

Erythema-ab-igne: Dermatoscopic evaluation of six cases

Dear Editor,

Erythema-ab-igne (EAI), or toasted skin syndrome, is a dermatosis resulting from low-level exposure to infrared heat. It presents as reticulated erythema and hyperpigmentation corresponding to dermal venous plexus. This results in a clinical picture characterized initially by transient macular erythema that easily blanches, progressing to fixed dusky hyperpigmentation. Dermatoscopic features of EAI need to be better characterized; knowledge of these features may aid in the differentiation of EAI from other reticulate dermatoses. We aim to provide new insights into the dermatoscopic features of EAI.

Six patients clinically diagnosed with EAI were included in the study. All patients were females with an average age of 36 years (range: 18–40 years) and had a history of using heating devices. Shins were involved in all six patients; two had lesions extending to the thighs and lower abdomen [Figure 1]. Dermatoscopic images were obtained using a DermLite DL4 dermatoscope attached to the camera of iPhone 12. Dermatoscopic features observed included accentuated pigment network (100%), epidermal scaling (83.3%), dilated eccrine openings (83.3%), polymorphous vessels (83.3%), red globules (33.3%), telangiectasias (33.3%) and white structureless areas (16.7%), over a background of erythema (100%) and homogenous brown pigmentation (100%) [Figures 2a–2d].

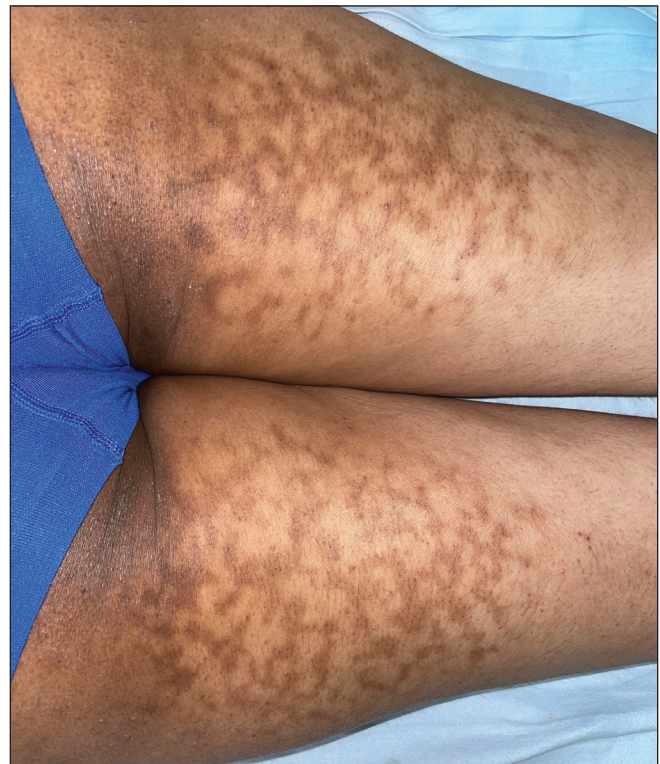

Figure 1: Dusky hyperpigmentation over the back of the thighs in a net-like pattern

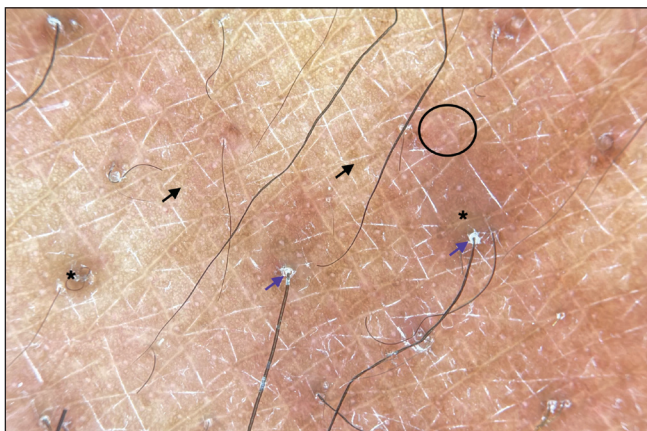


Figure 2a: Dermatoscopic evaluation of erythema-ab-igne: Accentuated pigment network (black arrows), follicular hyperkeratosis (blue arrows), polymorphous vessels (black circle) over a diffuse brown background (black asterisk) (DermLite DL4, 10x polarised).




Figure 2b: Dermatoscopic evaluation of erythema-ab-igne: Accentuated pigment network (black arrows), epidermal scaling (blue arrows), tortuous vessels (black circle), dotted vessels (yellow circle), white structureless areas (red asterisk) and green arrows (dilated eccrine openings) (DermLite DL4, 10x polarised).

How to cite this article: Mehta H, Gupta S, Vinay K. Erythema-ab-igne: Dermatoscopic evaluation of six cases. *Indian J Dermatol Venereol Leprol.* 2024;90:654-6. doi: 10.25259/IJDVL_68_2023

Received: January, 2023 **Accepted:** June, 2023 **Epub Ahead of Print:** July, 2023 **Published:** August, 2024

DOI: 10.25259/IJDVL_68_2023 **PMID:** 37609726

This is an open-access article distributed under the terms of the Creative Commons Attribution-Non Commercial-Share Alike 4.0 License, which allows others to remix, tweak, and build upon the work non-commercially, as long as the author is credited and the new creations are licensed under the identical terms.

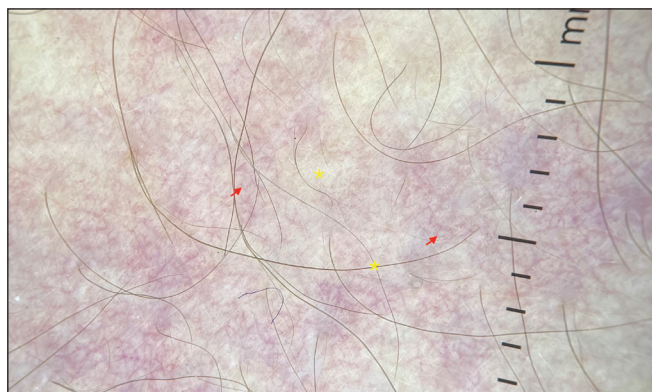


Figure 2c: Dermoscopic evaluation of erythema-ab-igne: Telangiectasias (red arrows) over a white background (yellow asterisk) in a patient with extensive erythema ab igne (DermLite DL4, 10x polarised)

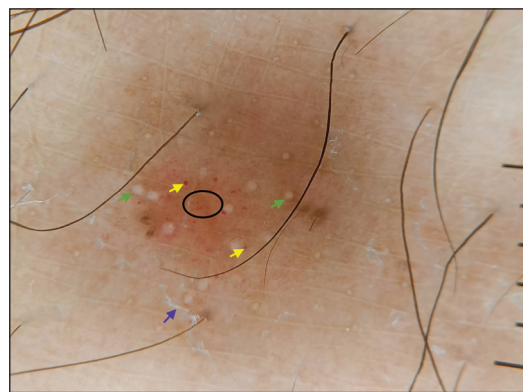


Figure 2d: Dermoscopic evaluation of erythema-ab-igne: Epidermal scaling (blue arrows), green arrows (dilated eccrine openings), red globules (yellow arrows), dotted vessels (black circle) (DermLite DL4, 10 ×, polarised)

Table 1: Observed frequency and likely histopathological correlates of various dermatoscopic features of erythema-ab-igne

Dermatoscopic feature	No. of patients (n = 6)	Histopathologic correlate
Lesional erythema	6 (100%)	Vasodilation
Accentuated pigment network	6 (100%)	Increased basal layer pigmentation
Homogenous brown pigmentation	6 (100%)	Dermal hemosiderin and melanin
Epidermal scaling and follicular hyperkeratosis	5 (83.3%)	Diffuse or focal hyperkeratosis
Dilated eccrine openings	5 (83.3%)	Dilatation of eccrine glands on heat exposure
Polymorphous vessels (linear vessels, dotted vessels, glomeruloid vessels, comma-shaped vessels)	5 (83.3%)	Dilation of postcapillary venules
Red globules	2 (33.3%)	Red blood cell extravasation
Telangiectasias	2 (33.3%)	Telangiectasias
White structureless areas	1 (16.7%)	Epidermal hyperkeratosis and dyskeratosis

In line with the existing literature, most of our patients were females, and the lower limbs were the most common site of involvement.¹ EAI may result from exposure to heat sources such as electric stoves, laptops, and hot water bottles. All our patients reported EAI after exposure to room heaters, likely due to the lack of central heating in most Indian households.

The pathogenesis of EAI is not completely elucidated, and recurrent heat exposure has been postulated to damage blood vessels in the papillary dermis with consequent hemosiderin accumulation and hyperpigmentation.¹ Diagnosis is generally clinical, although histopathology may be required to rule out other differentials in rare cases. Previous case reports have described erythema, telangiectasias, polymorphous vessels, and diffuse brown hyperpigmentation as dermatoscopic features of EAI.²⁻⁴ Apart from these previously reported findings, we observed accentuation of pigment network, dilated eccrine openings, and epidermal scaling in nearly all our patients. The main differentials of EAI include livedo reticularis, cutis marmorata, poikilodermatous mycosis fungoides, and adverse cutaneous drug reactions to amantadine. Dermatoscopy of poikilodermatous mycosis fungoides has been described as fine scales with linear branching vessels on a pink to the brown background.⁵ Major limitation of our study was the lack of histopathological confirmation. We minimized this limitation by only including cases with unequivocal clinical diagnosis of EAI. Likely

histopathological correlates of observed dermatoscopic findings are presented in Table 1.

Our study is an important case series describing the dermatoscopic features of EAI. EAI's dermatoscopic hallmarks include homogeneous brown pigmentation, lesional erythema, and pigment network accentuation. We describe several new features, such as epidermal scaling, dilated eccrine openings, polymorphous vessels, and red globules. Knowledge regarding these parameters would aid the clinician in establishing the diagnosis of EAI and differentiating it from other disorders with similar clinical presentations.

Declaration of patient consent: The authors certify that they have obtained all appropriate patient consent.

Financial support and sponsorship: Nil.

Conflicts of interest: There are no conflicts of interest.

**Hitaishi Mehta, Smriti Gupta,
Keshavamurthy Vinay**

Department of Dermatology, Venereology and Leprology, Post Graduate Institute of Medical Education and Research, Chandigarh, India

Corresponding author:

Dr. Keshavamurthy Vinay,

Department of Dermatology, Venereology and Leprology,
Post Graduate Institute of Medical Education and Research,
Chandigarh, India.

vinay.keshavmurthy@gmail.com

References

- Ozturk M, An I. Clinical features and etiology of patients with erythema ab igne: A retrospective multicenter study. *J Cosmet Dermatol* 2020;19:1774–9.
- Elmas ÖF, Demirbaş A, Atasoy M, Türsen Ü. The use of dermatoscopy in the diagnosis of erythema ab igne. *J Cosmet Dermatol* 2020;19:3444–5.
- Senhaji G, Jouari O, Zakia D, Mernissi F. A historical misleading case of erythema ab igne in a young Woman. *Our Dermatology Online* 2019;9:454–5.
- Giraldi S, Dietrich F, Abbage KT, Carvalho Vde O, Marinoni LP. Erythema Ab Igne induced by a laptop computer in an adolescent. *An Bras Dermatol* 2011;86:128–30.
- Apalla Z, Lallas A, Katodritou E, Fotiadou C, Lazaridou E, Bobos M. Dermoscopy of poikilodermatous mycosis fungoides: A case escaping diagnosis for three decades. *Photodermatol Photoimmunol Photomed* 2021;37:250–2.

Traumatic dystrophic calcinosis cutis in a child successfully treated with sodium metabisulfite ointment

Dear Editor,

A 13-year-old girl presented with multiple erythematous papules and nodules with ulceration and crusting, on her right knee for the past 1.5 years. There was a history of recurrent discharge of chalky white material from the lesions. The lesions did not limit any movement in the patient. There was no fever, muscle weakness, photosensitivity or any other systemic complaints. The patient had sustained trauma on the right knee due to a fall from a bicycle five years ago. Considering a diagnosis of an infective aetiology including scrofuloderma and atypical mycobacterial infection, she had received multiple courses of oral antibiotics and intralesional steroids before presenting to us with minimal improvement. Dermatological examination revealed multiple erythematous and yellow, discrete and coalescent, papules and nodules of size 0.5–1 cm on the right knee. Some lesions were arranged in a linear pattern. The papules were centrally ulcerated with whitish chalky deposits, along with variable white scaling and crusting. There were interspersed, small atrophic round scars [Figure 1]. The lesions were firm-to-hard on palpation. There was mild tenderness with no restriction of movement at the knee joint.

Dermatoscopy of the ulcerated erythematous papules showed scaling and crusting, central yellowish-to-white globules, with a surrounding rim of erythema and telangiectasias [Figure 2a]. A plain radiograph of the right knee joint revealed multiple well-defined periarticular opacities suggesting calcification [Figure 2b]. Serum calcium, phosphorus, vitamin D and parathyroid hormone levels were within normal limits. Histopathology on haematoxylin and eosin showed amorphous purple–blue dermal deposits

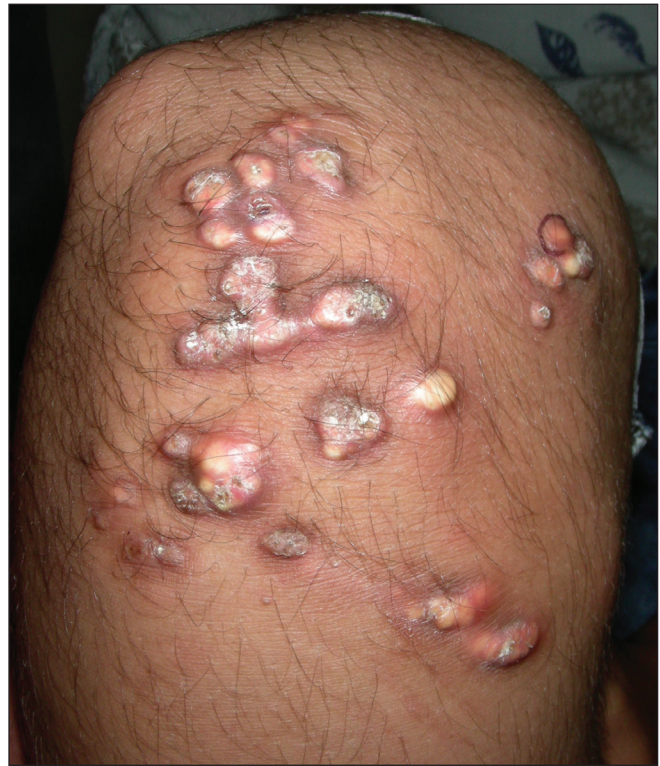

Figure 1: Multiple erythematous and yellow, discrete and coalescent, papules and nodules with central ulceration, white scaling and crusting on the right knee in a 13-year-old girl. Some papules are linearly arranged.

suggestive of calcinosis cutis [Figure 2c]. A diagnosis of dystrophic calcinosis cutis probably secondary to preceding trauma was considered, and the patient was started on topical 25% sodium metabisulfite ointment applied twice daily. For

How to cite this article: Mehta N, Bhoi AK, Khandpur S. Traumatic dystrophic calcinosis cutis in a child successfully treated with sodium metabisulfite ointment. *Indian J Dermatol Venereol Leprol.* 2024;90:656–8. doi: 10.25259/IJDVL_139_2023

Received: February, 2023 **Accepted:** March, 2023 **EPub Ahead of Print:** May, 2023 **Published:** August, 2024

DOI: 10.25259/IJDVL_139_2023 **PMID:** 37317755

This is an open-access article distributed under the terms of the Creative Commons Attribution-Non Commercial-Share Alike 4.0 License, which allows others to remix, tweak, and build upon the work non-commercially, as long as the author is credited and the new creations are licensed under the identical terms.