

Wells syndrome in a patient receiving adalimumab biosimilar: A case report and review of literature

Sir,

Wells syndrome was first described by George Wells in 1971 as a recurrent granulomatous dermatitis with eosinophilia.¹ It presents with erythematous, indurated, tender or mildly pruritic plaques which mimic cellulitis. Demonstration of dermal edema, marked eosinophil infiltration and presence of free eosinophilic granules coating collagen bundles (“flame figures”) in histopathology is diagnostic.^{1,2}

A 36-year-old man with a 12-year history of hidradenitis suppurativa (Hurley’s grade III) was started on adalimumab biosimilar (Exemptia; Zydus Cadila) monotherapy because of inadequate treatment response to multiple courses of antibiotics and retinoids (acitretin 35 mg/day for 1 year and 3 months). He presented to the outpatient department with three erythematous to plum colored indurated plaques of recent onset on the third and fifth digits of the right hand

and sole of the right foot, 1 month after starting adalimumab biosimilar (6 hours after third dose) [Figures 1–3]. He also complained of minimal pain that exacerbated with the movement of the fingers and on walking. There was no history of any other drug intake, fever, trauma, recent travel, insect bite or intravenous drug use. Sweet's syndrome, Wells syndrome and fixed drug eruption were considered as differential diagnoses.

A complete blood count revealed increased white blood cell count ($13.37 \times 10^3/\text{dL}$ [normal $4.00 \times 10^3/\text{dL}$ to $11.00 \times 10^3/\text{dL}$]) and peripheral eosinophilia (18.6%) with an absolute eosinophil count of $2.48 \times 10^3/\text{dL}$ (normal $0.10 \times 10^3/\text{dL}$ to $0.50 \times 10^3/\text{dL}$). C-reactive protein levels (6.9 mg/L [normal 0 mg/L to 5.0 mg/L]) and ESR (70 mm/h) were found to be elevated, suggesting an inflammatory process. Total serum IgE 65 U/ml (2–100 U/ml), renal and liver function were normal. No ova or parasites were observed in stool microscopy. The clinical diagnosis of Wells syndrome was confirmed by the typical histopathological finding of marked eosinophil infiltration into the dermis and subcutaneous tissue with flame figures [Figures 4 and 5]. A short course of oral steroids, i.e. prednisolone 40 mg for 2 weeks, gradually tapered over the next 8 weeks led to disease resolution [Figure 6]. Drug rechallenge test elicited similar results within 5 hours of giving the fourth dose. Adalimumab biosimilar was stopped and there has been no recurrence of the lesions thus far.

Wells syndrome presents with sudden onset, single or multiple, erythematous, indurated or urticarial plaques which resolve without scarring over 2–8 weeks. Clinical variants of Wells syndrome include plaque type, annular

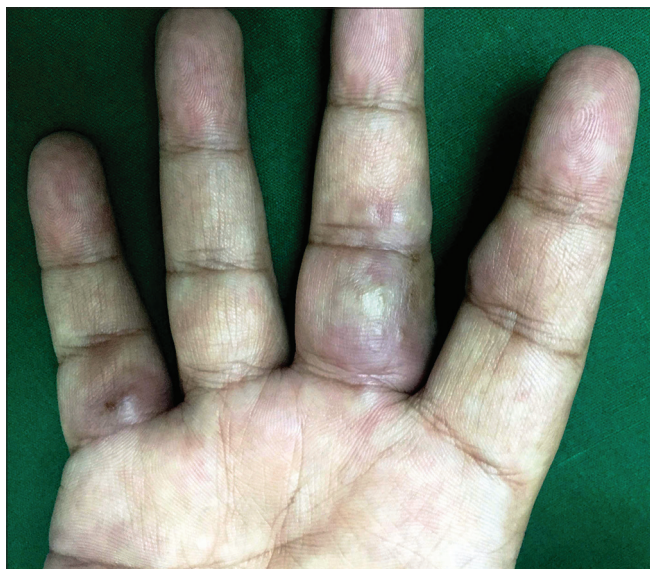

Figure 1: Erythematous to plum-colored indurated plaques on the volar aspect of the third and fifth digits of the right hand

granuloma-like, urticaria-like, papulo-vesicular, bullous, papulo-nodular and fixed drug eruption-like lesions.² In our case, plaque-type lesions were seen. The pathogenesis is not very clear and it is believed to be a hypersensitivity reaction to a variety of exogenous and endogenous stimuli. Excessive production of interleukin-5 resulting in eosinophil accumulation and a local Th2 immune response has been documented. Wells syndrome is associated with infections (viral/parasitic/arthropod bite), malignancy, atopy, Churg–Strauss syndrome and drugs. Table 1 lists the iatrogenic causes of Wells syndrome.² Adalimumab-induced Sweet's syndrome, erythema multiforme and fixed drug eruption have been reported previously but the characteristic histopathology helped us in clinching the diagnosis.

Some cases of eosinophilia associated with tumor necrosis factor- α inhibitors have been reported before.³ Wells syndrome-like lesions have been described at the injection site of etanercept⁴ and adalimumab⁵ as local reaction to the drug, but not away from the injection site as observed

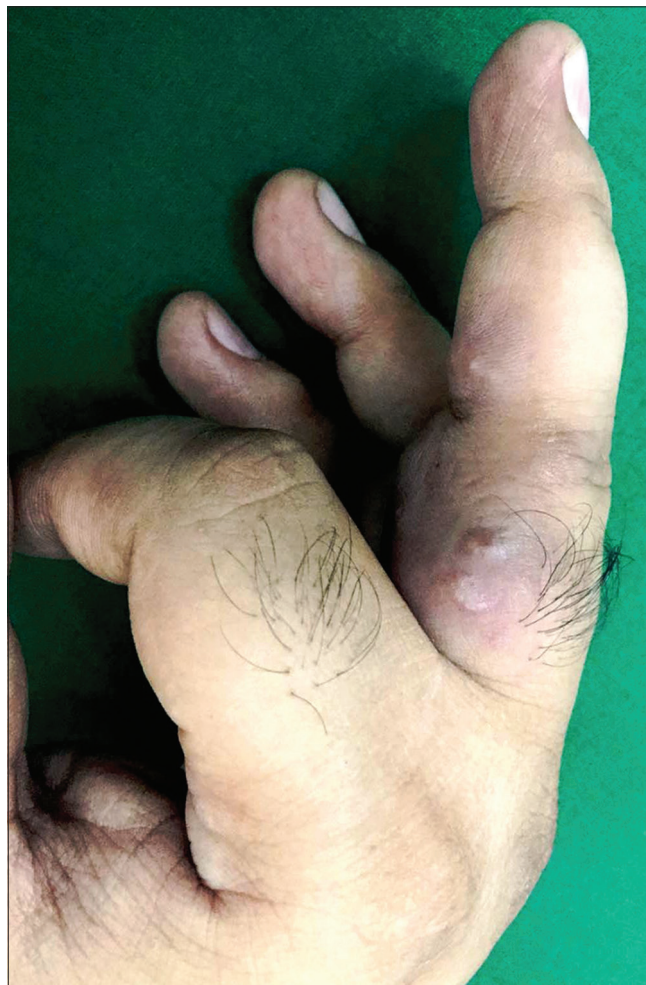

Figure 2: Close-up view showing erythematous to plum-colored indurated plaque with overlying two small vesicles on the proximal and middle phalanges of the third digit of the right hand

in our patient. The Naranjo adverse drug probability score was 9 in our patient, suggestive of a definite adverse drug reaction [Table 2]. A Medline and PubMed search was performed and we recorded the features in cases of Wells syndrome or cases with blood or tissue eosinophilia after anti-tumor necrosis factor- α therapy [Table 3].^{4,15}

The mechanism of tumor necrosis factor- α inhibition leading to eosinophilia remains still elusive. Anti-tumor necrosis factor- α agents can induce an immune deviation from the Th1 to the Th2 phenotype in some patients, resulting in eosinophilia. Quaglino *et al.* reported that psoriasis patients responding to etanercept showed a significant reversal of the Th1/Th17 activation and a concomitant upregulation of Th2 and regulatory T cells.¹⁶ Formation of IgE-class-switched antibodies can lead

to IgE-mediated drug hypersensitivity and subsequent eosinophilia.¹⁷ More sustained and effective tumor necrosis factor - α inhibition was associated with a higher risk of eosinophilia. Hence, adalimumab has more risk of causing eosinophilia than etanercept. Recently, Chiriac *et al.* reported a case series of 28 patients who developed eosinophilia during the first 6 months with adalimumab therapy.¹⁸

Table 1: Iatrogenic causes of Wells syndrome

Drugs
NSAIDs - Acetylsalicylic acid, tenoxicam, diclofenac sodium
Antibiotics - Penicillins, amoxicillin, ampicillin, tetracycline, minocycline, erythromycin, lincomycin, clindamycin
Anesthetics - Xylocaine, sodium thiopental, carbocaine
Benzodiazepine - Chlordiazepoxide
Chemotherapeutic agents - Bleomycin, chlorambucil, cladribine
Diuretics - Thiazide diuretics (hydrochlorothiazide), aliskiren
Hormonal agents - Thyroxine, danazol
Opioid - Pholcodine
Thiomersal containing vaccines - Tetanus, diphtheria, hepatitis B
Anti-TNF- α agents - Infliximab, etanercept, adalimumab
NSAIDs: Nonsteroidal anti-inflammatory drugs, TNF- α : Tumor necrosis factor- α

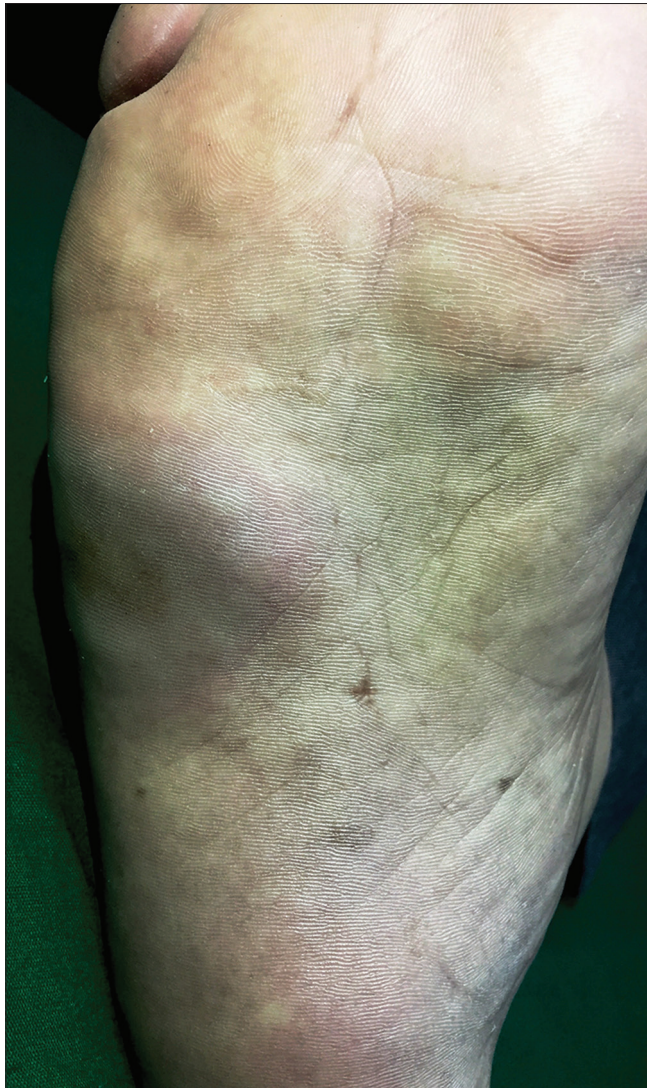

Figure 3: Erythematous to plum-colored indurated plaque on the sole of the right foot

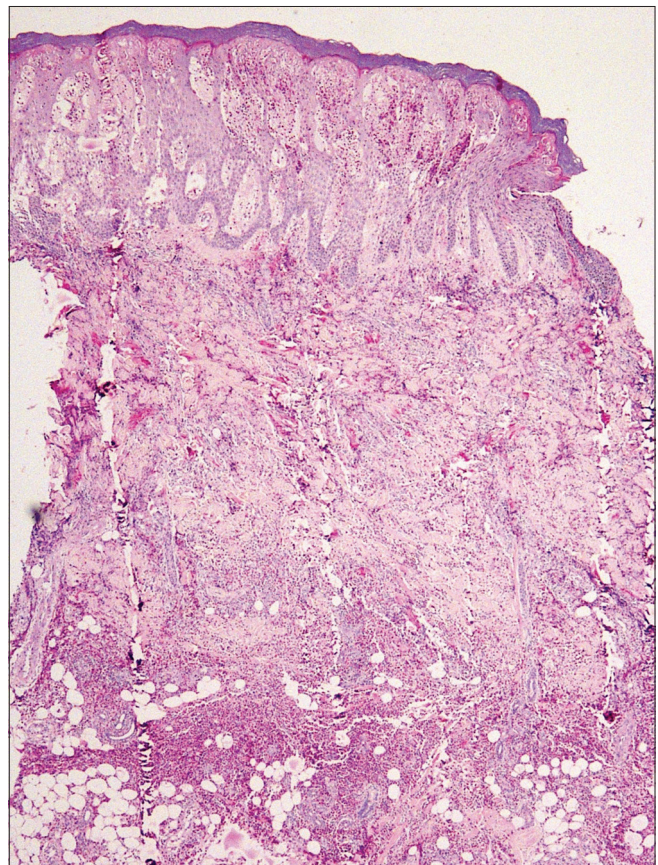


Figure 4: Skin biopsy from the palm showing dense eosinophil infiltration extending from the epidermis till subcutaneous fat, with marked epidermal spongiosis [hematoxylin and eosin (H and E), $\times 40$]

Table 2: Adverse drug reaction probability scores in our patient

Question	Yes	No	Don't know	Reply and score in our patient
Naranjo adverse drug probability score				
1. Are there previous conclusion reports on this reaction?	+1	0	0	+1 (yes)
2. Did the adverse event appear after the suspect drug was administered?	+2	-1	0	+2 (yes)
3. Did the AR improve when the drug was discontinued or a specific antagonist was administered?	+1	0	0	+1 (yes)
4. Did the AR reappear when drug was re-administered?	+2	-1	0	+2 (yes)
5. Are there alternate causes (other than the drug) that could solely have caused the reaction?	-1	+2	0	+2 (no)
6. Did the reaction reappear when a placebo was given?	-1	+1	0	0 (don't know)
7. Was the drug detected in the blood (or other fluids) in a concentration known to be toxic?	+1	0	0	0 (no)
8. Was the reaction more severe when the dose was increased or less severe when the dose was decreased?	+1	0	0	0 (don't know)
9. Did the patient have a similar reaction to the same or similar drugs in any previous exposure?	+1	0	0	0 (no)
10. Was the adverse event confirmed by objective evidence?	+1	0	0	+1 (yes)
Total Naranjo Score				9 (definite)
B. WHO-UMC causality category				
Temporal relation to drug intake				Certain
Response to withdrawal				
Event definitive pharmacologically or phenomenologically (recognized pharmacological phenomenon)				
Rechallenge positive				
Cannot be explained by disease or other drugs				
C. Modified Hartwig and Siegel Scale				
The AR required that treatment with the suspected drug be discontinued, or changed				Level 3 (moderate)
An antidote or other treatment (prednisolone) was required				
UMC: Uppsala Monitoring Centre, AR: Adverse reaction				

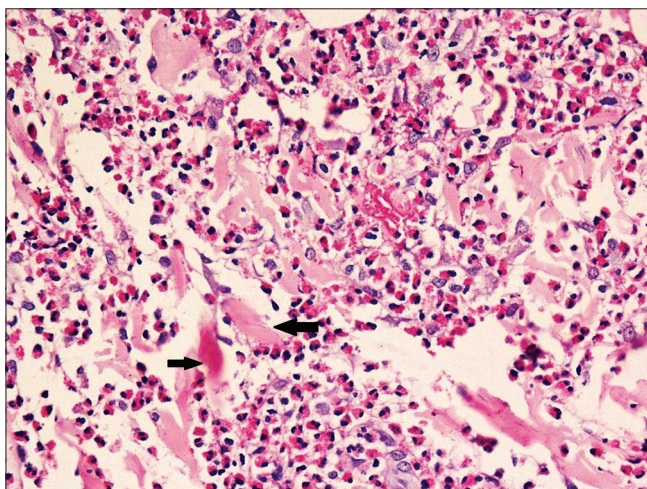


Figure 5: Marked dermal edema and eosinophil infiltration with arrows showing flame figures (H and E, ×400)

To conclude, the introduction of biologics has significantly improved treatment efficacy in several chronic inflammatory diseases. Recent reports suggest that tumor necrosis factor- α inhibitors can cause both blood and tissue eosinophilia. In

most cases, it is benign and does not warrant drug withdrawal. However, reports of acute necrotizing eosinophilic myocarditis⁸ and lung damage¹⁵ due to tissue eosinophilia caused by tumor necrosis factor inhibitors also exist. It is important for the treating dermatologists to recognize this complication early and treat accordingly. With new biologics entering the market every year, it is vital to identify and report potential drug-related side effects.

Declaration of patient consent

The authors certify that they have obtained all appropriate patient consent forms. In the form the patient has given his consent for his images and other clinical information to be reported in the journal. The patient understands that the names and initials will not be published and due efforts will be made to conceal their identity, but anonymity cannot be guaranteed.

Financial support and sponsorship

Nil.

Conflicts of interest

There are no conflicts of interest.

Table 3: Review of eosinophilia and eosinophilic dermatosis following tumor necrosis factor- α inhibitor treatment

Disease	Age/sex	Additional drugs	Anti TNF- α therapy	Pathology	Site (s)	Histology	Peripheral eosinophilia (%)	Supplemental investigations	Treatment	Author
RA	72/female	-	Adalimumab-4 h after 2 nd dose	WS	Thigh (injection site)	Dermal eosinophil infiltrate with flame figures	No	Increased ESR, CRP	Improved with steroids	Boura <i>et al.</i> ⁵
HS	36/male	-	Adalimumab-3 rd dose	WS	Fingers, sole	Marked dermal eosinophil infiltration extending upto subcutaneous tissue with flame figures	Yes (18.6)	IgE normal CRP, ESR raised	Improved with steroids	Our report
RA	69/female	Oral prednisolone	Infliximab-1 week	WS	Back, abdomen	Dense infiltrate of lymphocytes, histiocytes and eosinophils in the dermis. No flame figures	Yes (5.3)	Biopsy	NA	Tugnet <i>et al.</i> ⁶
RA	57/female	Prednisolone, methotrexate, and hydroxychloroquine	Etanercept-24 h	WS	Thigh	Dermal edema with dense eosinophilic infiltrate and flame figures	No	Biopsy	Improved with steroids	Winfield <i>et al.</i> ⁴
RA	24/female	Prednisolone (5 mg/day) and methotrexate	Etanercept-3 years	Digital vasculitis	Fingers, toes	Necrotizing vasculitis with mixed inflammatory infiltrate	Yes (59.8)	IL-5 and ECP levels increased, normal IgE	Responded to prednisolone. Anti TNF- α therapy continued	Nakahigashi <i>et al.</i> ⁷
Relapsing polychondritis	51/female	Methotrexate 10 mg and prednisone 6 mg	Adalimumab-2 weeks	Acute necrotizing eosinophilic myocarditis	Heart	Necrotizing eosinophilic pancarditis	No	Normal counts. Increased Trop T	Died	Adamson <i>et al.</i> ⁸
PsA	59/male	NSAIDS, topicals	Infliximab-9 months	Eosinophilic fasciitis	Leg	Diffuse thickening and edema of the epimysium with mixed lymphohistiocytic infiltrate and focal eosinophils	Yes (30)	Increased aldolase, normal IgE	Improved with steroids	Hariman <i>et al.</i> ⁹
RA	80/female	No	Infliximab-3 months, etanercept-1 month	Subacute prurigo and eosinophilia	Disseminated	Severe dermal edema with lymphocytic infiltrate and abundant perivascular eosinophils	Yes (total count 1020/mm ³)	Biopsy	Improved with steroids	Cancelliere <i>et al.</i> ¹⁰
PsA	68/male	Steroids, cyclosporine	Infliximab-8 th dose	Eczema	Disseminated	Dermatitis. Details not mentioned	Yes	Increased ESR and IgE	Improved with steroids, treatment discontinued	Vestergaard <i>et al.</i> ¹¹
Psoriasis	46/male, 55/female, 24/male	Topicals	Etanercept-3 months, adalimumab-8 months	Eosinophilia	Blood eosinophilia	-	Yes	ECP raised, IgE normal	Responded to treatment discontinuation	Malisiewicz <i>et al.</i> ¹²
PsA	59/male	Methylprednisolone 4 mg	Etanercept-1 month, adalimumab-5 months	Eosinophilia	Blood eosinophilia	-	Yes (38.6)	Normal IgE	Improved on treatment discontinuation	Guidelli <i>et al.</i> ¹³
ACH	58/female	-	Adalimumab-21 months	Eosinophilia	Blood eosinophilia	-	Yes	-	Improved on treatment discontinuation	Vester <i>et al.</i> ¹⁴
UC	63/female	Balsalazide	Infliximab-9 months	Drug-induced lung disease	Lung	Lymphocytic interstitial pneumonitis and histiocytic pneumonia with eosinophils	No	BAL (15% eosinophils)	Improved with steroids	Wiener <i>et al.</i> ¹⁵

RA: Rheumatoid arthritis, PsA: Psoriatic arthritis, UC: Ulcerative colitis, HS: Hidradenitis suppurativa, BAL: Bronchoalveolar lavage, Trop T: Troponin T, ACH: Acrodermatitis continua of Hallopeau, TNF- α : tumor necrosis factor- α , NSAIDS: Nonsteroidal anti-inflammatory drugs, WS: Wells syndrome, ESR: Erythrocyte sedimentation rate, CRP: C-reactive protein, IL-5: Interleukin-5, ECP: Eosinophil cationic protein

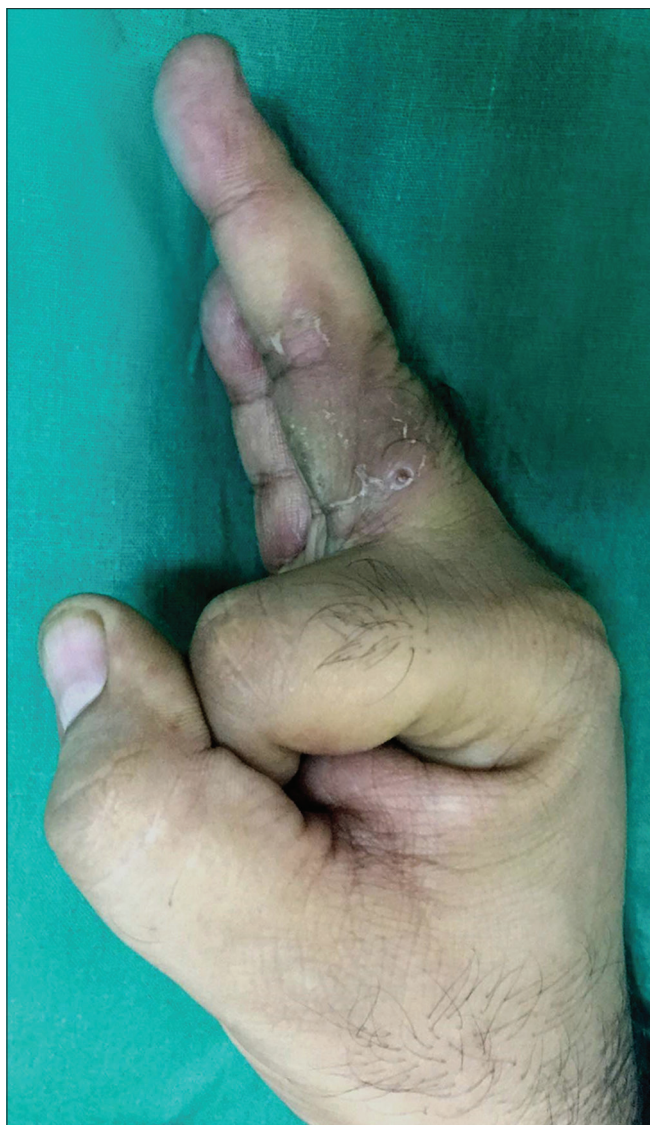

Figure 6: Improvement in edema with desquamation over the lesions 6 weeks after starting prednisolone

Garima Dabas, Dipankar De, Sanjeev Handa, Debajyoti Chatterjee¹, Bishan Das Radotra¹

Departments of Dermatology, Venereology and Leprology and ¹Pathology, Postgraduate Institute of Medical Education and Research (PGIMER), Chandigarh, India

Correspondence: Dr. Dipankar De, Department of Dermatology Venereology and Leprology, PGIMER, Chandigarh - 160 012, India. E-mail: dr_dipankar_de@yahoo.in

References

1. Wells GC. Recurrent granulomatous dermatitis with eosinophilia. *Trans St Johns Hosp Dermatol Soc* 1971;57:46-56.
2. Consigny S, Courville P, Young P, Richard C, Gauthier V, Maillard V, *et al.* Histological and clinical forms of the eosinophilic cellulitis. *Ann Dermatol Venereol* 2001;128:213-6.
3. Beuthien W, Mellinghoff HU, von Kempis J. Skin reaction to adalimumab. *Arthritis Rheum* 2004;50:1690-2.
4. Winfield H, Lain E, Horn T, Hoskyn J. Eosinophilic cellulitislike reaction to subcutaneous etanercept injection. *Arch Dermatol*

- 2006;142:218-20.
5. Boura P, Sarantopoulos A, Lefaki I, Skendros P, Papadopoulos P. Eosinophilic cellulitis (Wells’ syndrome) as a cutaneous reaction to the administration of adalimumab. *Ann Rheum Dis* 2006;65:839-40.
6. Tugnet N, Youssef A, Whallett AJ. Wells’ syndrome (eosinophilic cellulitis) secondary to infliximab. *Rheumatology (Oxford)* 2012;51:195-6.
7. Nakahigashi K, Egawa G, Miyachi Y, Kabashima K. Digital vasculitis with eosinophilia possibly associated with etanercept therapy. *Acta Derm Venereol* 2014;94:239-40.
8. Adamson R, Yazici Y, Katz ES, Greisman SG, Steiger D. Fatal acute necrotizing eosinophilic myocarditis temporally related to use of adalimumab in a patient with relapsing polychondritis. *J Clin Rheumatol* 2013;19:386-9.
9. Hariman R, Patel P, Strouse J, Collins MP, Rosenthal A. Development of eosinophilic fasciitis during infliximab therapy for psoriatic arthritis. *Case Rep Rheumatol* 2016;2016:7906013.
10. Cancelliere N, Barranco P, Vidaurrázaga C, Benito DM, Quirce S. Subacute prurigo and eosinophilia in a patient with rheumatoid arthritis receiving infliximab and etanercept. *J Investig Allergol Clin Immunol* 2011;21:248-9.
11. Vestergaard C, Deleuran M, Kragballe K. Two cases of atopic dermatitis-like conditions induced in psoriasis patients treated with infliximab. *J Eur Acad Dermatol Venereol* 2007;21:1272-4.
12. Malisiewicz B, Murer C, Pachlopnik Schmid J, French LE, Schmid-Grendelmeier P, Navarini AA, *et al.* Eosinophilia during psoriasis treatment with TNF antagonists. *Dermatology* 2011;223:311-5.
13. Guidelli GM, Tenti S, Fioravanti A. Severe eosinophilia during anti-tumor necrosis factor-alpha therapy for psoriatic arthritis. *Indian J Dermatol Venereol Leprol* 2014;80:187-9.
14. Vester K, Rüter RD, Harth W, Simon JC. Transient blood eosinophilia during treatment with adalimumab. *J Eur Acad Dermatol Venereol* 2012;26:924-5.
15. Wiener CM, Muse VV, Mark EJ. Case records of the Massachusetts General Hospital. Case 33-2008. A 63-year-old woman with dyspnea on exertion. *N Engl J Med* 2008;359:1823-32.
16. Quaglino P, Bergallo M, Ponti R, Barberio E, Cicchelli S, Buffa E, *et al.* Th1, th2, th17 and regulatory T cell pattern in psoriatic patients: Modulation of cytokines and gene targets induced by etanercept treatment and correlation with clinical response. *Dermatology* 2011;223:57-67.
17. Eyerich S, Onken AT, Weidinger S, Franke A, Nasorri F, Pennino D, *et al.* Mutual antagonism of T cells causing psoriasis and atopic eczema. *N Engl J Med* 2011;365:231-8.
18. Chiriac A, Brzezinski P, Stolnicu S, Podoleanu C, Moldovan C, Molnar C, *et al.* Eosinophilia – A rare possible adverse reaction during anti-tumor necrosis factor-alpha therapy for psoriasis. *J Dermatolog Treat* 2016;27:110-3.

This is an open access journal, and articles are distributed under the terms of the Creative Commons Attribution-NonCommercial-ShareAlike 4.0 License, which allows others to remix, tweak, and build upon the work non-commercially, as long as appropriate credit is given and the new creations are licensed under the identical terms.

Access this article online	
Quick Response Code:	Website: www.ijdvil.com
	DOI: 10.4103/ijdvil.IJDVL_636_17

How to cite this article: Dabas G, De D, Handa S, Chatterjee D, Radotra BD. Wells syndrome in a patient receiving adalimumab biosimilar: A case report and review of literature. *Indian J Dermatol Venereol Leprol* 2018;84:594-9.

Received: November, 2017. **Accepted:** February, 2018.

© 2018 Indian Journal of Dermatology, Venereology and Leprology | Published by Wolters Kluwer - Medknow