

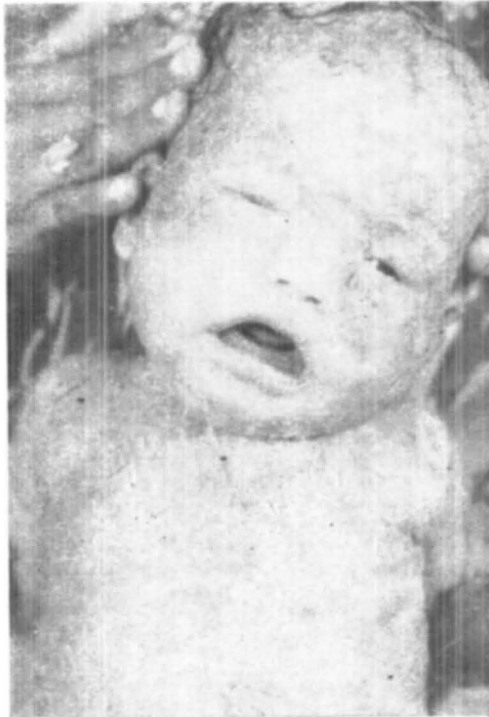Short Communications

Dettol induced irritant dermatitis

We are reporting a case of acute irritant dermatitis following "Dettol Bath" in a 10 day old baby to highlight the serious complications its injudicious use can produce.

Dettol (Chloroxylenol) is an antiseptic commonly used for almost every skin and venereal disease. It is abused by many people who are overconscious about hygiene as a cleansing agent. An attempt to get rid of harmful bacteria from a child's skin with dettol bath, resulted in frighteningly acute irritant dermatitis resembling exfoliative dermatitis.

A 10 day old female baby was brought to the hospital 24 hours after she was given a bath in dettol solution diluted with water in 1:4 strength. The baby developed diffuse erythema, vesicles and copious oozing, few hours after the bath. The child was dehydrated, toxæmic and very sick with exfoliation involving total body surface. The clinical picture was that of an exfoliative dermatitis.



Systemic steroids and supportive measures were given. The child responded to this and was well in about 3-4 weeks' time.

* Department of Dermatology,
Postgraduate Institute of Medical
Education & Research, Chandigarh

† Institute of Medical Sciences,
Banaras Hindu University,
Varanasi

* **Bhushan Kumar**

† **Gurmohan Singh**

* **S. N. Roy**

WHAT IS YOUR DIAGNOSIS ?

Fifty-five year old male patient complained of whitish patches on the inner aspect of both cheeks for 2 years. Patient was addicted to smoking for 20 years. He had an exposure to STD 10 years earlier, but had no post-exposure problems.

Examination revealed white firm plaques of 4 cm × 3 cm size on inner aspect of both cheeks. There was no ulceration and rest of the mucosa was normal. There were no lesions on the skin or genitalia.

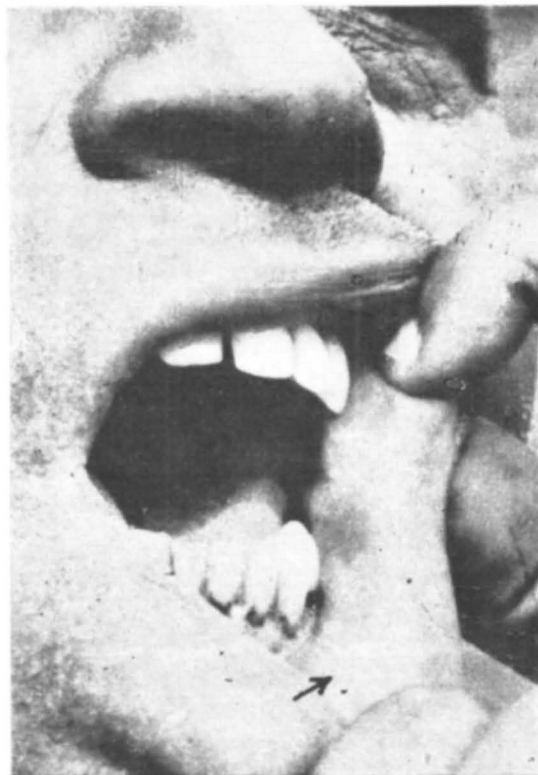


Fig.

- Differential diagnosis :**
1. Oral lichen planus
 2. Leukoplakia
 3. Late syphilis
 4. Submucous fibrosis