

# Indian Journal of Dermatology, Venereology & Leprology

Journal indexed with SCI-E, PubMed, and EMBASE

Vol 74 | Issue 2 | Mar-Apr 2008

C O N T E N T S

## EDITORIAL

### Management of autoimmune urticaria

Arun C. Inamadar, Aparna Palit ..... 89

## VIEW POINT

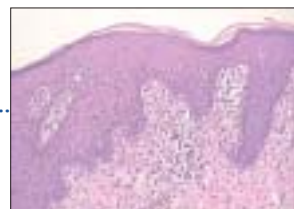### Cosmetic dermatology versus cosmetology: A misnomer in need of urgent correction

Shyam B. Verma, Zoe D. Draelos ..... 92

## REVIEW ARTICLE

### Psoriasiform dermatoses

Virendra N. Sehgal, Sunil Dogra, Govind Srivastava, Ashok K. Aggarwal ..... 94



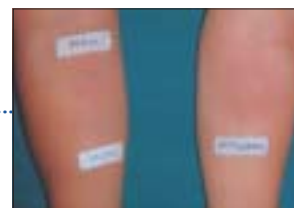## ORIGINAL ARTICLES

### A study of allergen-specific IgE antibodies in Indian patients of atopic dermatitis

V. K. Somani ..... 100

### Chronic idiopathic urticaria: Comparison of clinical features with positive autologous serum skin test

George Mamatha, C. Balachandran, Prabhu Smitha ..... 105



### Autologous serum therapy in chronic urticaria: Old wine in a new bottle

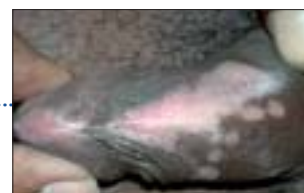A. K. Bajaj, Abir Saraswat, Amitabh Upadhyay, Rajetha Damisetty, Sandipan Dhar ..... 109

### Use of patch testing for identifying allergen causing chronic urticaria

Ashimav Deb Sharma ..... 114

### Vitiligoid lichen sclerosus: A reappraisal

Venkat Ratnam Attali, Sasi Kiran Attali ..... 118



**BRIEF REPORTS**

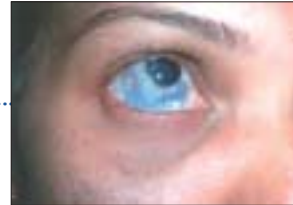**Activated charcoal and baking soda to reduce odor associated with extensive blistering disorders**

Arun Chakravarthi, C. R. Srinivas, Anil C. Mathew ..... 122



**Nevus of Ota: A series of 15 cases**

Shanmuga Sekar, Maria Kuruvila, Harsha S. Pai ..... 125



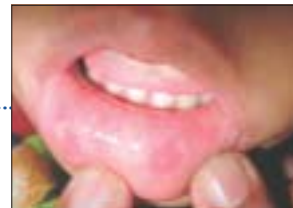**Premature ovarian failure due to cyclophosphamide: A report of four cases in dermatology practice**

Vikrant A. Saoji ..... 128

**CASE REPORTS**

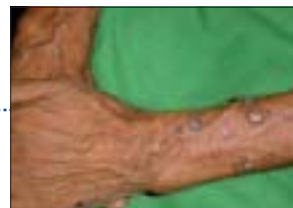**Hand, foot and mouth disease in Nagpur**

Vikrant A. Saoji ..... 133



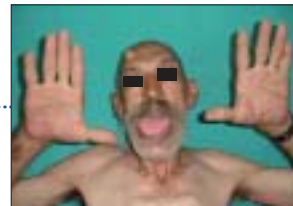**Non-familial multiple keratoacanthomas in a 70 year-old long-term non-progressor HIV-seropositive man**

Hemanta Kumar Kar, Sunil T. Sabhnani, R. K. Gautam, P. K. Sharma, Kalpana Solanki, Meenakshi Bhardwaj ..... 136



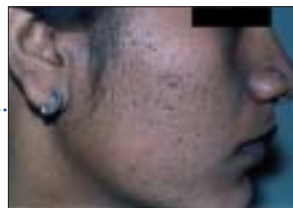**Late onset isotretinoin resistant acne conglobata in a patient with acromegaly**

Kapil Jain, V. K. Jain, Kamal Aggarwal, Anu Bansal ..... 139



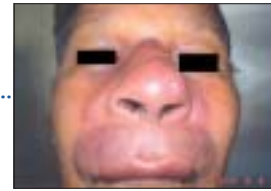**Familial dyskeratotic comedones**

M. Sendhil Kumaran, Divya Appachu, Elizabeth Jayaseelan ..... 142



**Nasal NK/T cell lymphoma presenting as a lethal midline granuloma**

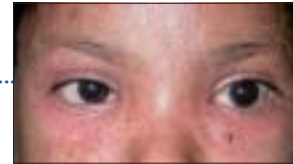Vandana Mehta, C. Balachandran, Sudha Bhat, V. Geetha, Donald Fernandes .....



145

**Childhood sclerodermatomyositis with generalized morphea**

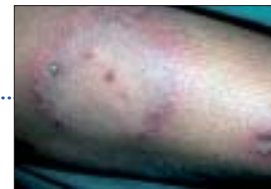Girishkumar R. Ambade, Rachita S. Dhurat, Nitin Lade, Hemangi R. Jerajani.....



148

**Subcutaneous panniculitis-like T-cell cutaneous lymphoma**

Avninder Singh, Joginder Kumar, Sujala Kapur, V. Ramesh.....



151

**LETTERS TO EDITOR**

**Using a submersible pump to clean large areas of the body with antiseptics**

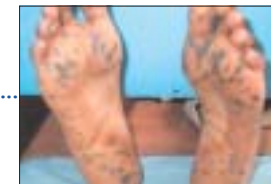C. R. Srinivas .....



154

**Peutz-Jeghers syndrome with prominent palmoplantar pigmentation**

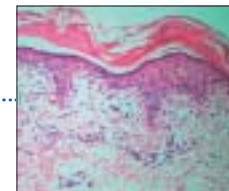
K. N. Shivaswamy, A. L. Shyamprasad, T. K. Sumathi, C. Ranganathan .....



154

**Stratum corneum findings as clues to histological diagnosis of pityriasis lichenoides chronica**

Rajiv Joshi .....



156

**Author's reply**

S. Pradeep Nair .....

157

**Omalizumab in severe chronic urticaria**

K. V. Godse.....

157

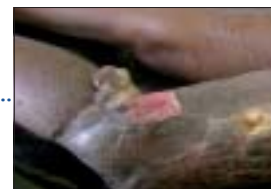**Hypothesis: The potential utility of topical eflornithine against cutaneous leishmaniasis**

M. R. Namazi .....

158

**Nodular melanoma in a skin graft site scar**

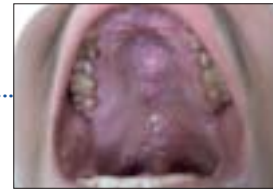A. Gnaneshwar Rao, Kamal K. Jhamnani, Chandana Konda .....



159

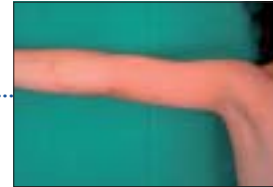**Palatal involvement in lepromatous leprosy**

A. Gnaneshwar Rao, Chandana Konda, Kamal Jhamnani..... 161



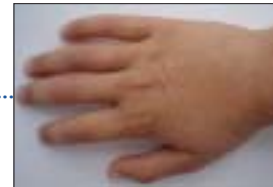**Unilateral nevoid telangiectasia with no estrogen and progesterone receptors in a pediatric patient**

F. Sule Afsar, Ragip Ortac, Gulden Diniz ..... 163



**Eruptive lichen planus in a child with celiac disease**

Dipankar De, Amrinder J. Kanwar..... 164

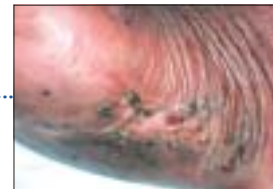

**Xerosis and pityriasis alba-like changes associated with zonisamide**

Feroze Kaliyadan, Jayasree Manoj, S. Venkitakrishnan..... 165

**Treatment of actinomycetoma with combination of rifampicin and co-trimoxazole**

Rajiv Joshi ..... 166



**Author's reply**

M. Ramam, Radhakrishna Bhat, Taru Garg, Vinod K. Sharma, R. Ray, M. K. Singh, U. Banerjee, C. Rajendran ..... 168

**Vitiligo, psoriasis and imiquimod: Fitting all into the same pathway**

Bell Raj Eapen ..... 169

**Author's reply**

Engin Şenel, Deniz Seçkin ..... 169

**Multiple dermatofibromas on face treated with carbon dioxide laser: The importance of laser parameters**

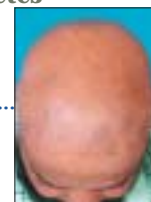Kabir Sardana, Vijay K. Garg ..... 170

**Author's reply**

D. S. Krupa Shankar, A. Kushalappa, K. S. Uma, Anjay A. Pai..... 170

**Alopecia areata progressing to totalis/universalis in non-insulin dependent diabetes mellitus (type II): Failure of dexamethasone-cyclophosphamide pulse therapy**

Virendra N. Sehgal, Sambit N. Bhattacharya, Sonal Sharma, Govind Srivastava, Ashok K. Aggarwal ..... 171



**Subungual exostosis**

Kamal Aggarwal, Sanjeev Gupta, Vijay Kumar Jain, Amit Mital, Sunita Gupta..... 173

**Clinicohistopathological correlation of leprosy**

Amrish N. Pandya, Hemali J. Tailor ..... 174

**RESIDENT'S PAGE**

**Dermatographism**

Dipti Bhute, Bhavana Doshi, Sushil Pande, Sunanda Mahajan, Vidya Kharkar ..... 177

**FOCUS**

**Mycophenolate mofetil**

Amar Surjushe, D. G. Saple ..... 180

**QUIZ**

**Multiple papules on the vulva**

G. Raghu Rama Rao, R. Radha Rani, A. Amareswar, P. V. Krishnam  
Raju, P. Raja Kumari, Y. Hari Kishan Kumar ..... 185



**E-IDVL**

**Net Study**

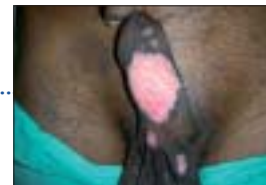**Oral isotretinoin is as effective as a combination of oral isotretinoin and topical anti-acne agents in nodulocystic acne**

Rajeev Dhir, Neetu P. Gehi, Reetu Agarwal, Yuvraj E. More ..... 187

**Net Case**

**Cutaneous diphtheria masquerading as a sexually transmitted disease**

T. P. Vetrichevvel, Gajanan A. Pise, Kishan Kumar Agrawal,  
Devinder Mohan Thappa ..... 187



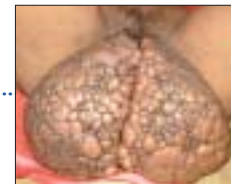**Net Letters**

**Patch test in Behcet's disease**

Ülker Gül, Müzeyyen Gönül, Seray Külcü Çakmak, Arzu Kılıç ..... 187

**Cerebriform elephantiasis of the vulva following tuberculous lymphadenitis**

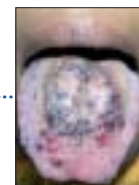Surajit Nayak, Basanti Acharjya, Basanti Devi, Satyadarshi Pattnaik,  
Manoj Kumar Patra ..... 188



**Net Quiz**

**Vesicles on the tongue**

Saurabh Agarwal, Krishna Gopal, Binay Kumar ..... 188



### Using a submersible pump to clean large areas of the body with antiseptics

Sir,

In the year 1970, I joined SSKM Hospital in Kolkata as a resident in plastic surgery and was posted in the burns unit then located in the famous Ronald Ross building. In those days, our greatest time-consuming challenge was cleaning wounds involving large areas of the body. Today, as dermatologists, we face a similar situation with toxic epidermal necrolysis (TEN) and other extensive bullous disorders. Wound toilette is done usually with basins of potassium permanganate solution and normal saline. The patients' skin is tender causing them to constantly groan during dressing.

Hence, any device that could minimize patient handling would be useful. Last year, my wife Chitra bought a small fountain to be placed on the table in our home. It has a tiny submersible pump which re-circulates water pumping it through a dolphin's mouth. Derma India<sup>®</sup> procured for me a small submersible pump [Figure 1] (Tulu submersible pump model THS 3000 240-250 Power 35 Watt) with which we could siphon water from a container and pump it through an adjustable hand piece. It is possible to place potassium permanganate, hydrogen peroxide or saline in the container and direct the stream of fluid with some force over the body of the patient to dislodge crusts and clean



Figure 1: Tulu submersible pump

the wound, akin to the water servicing of a car. This device will not only quicken the process of wound cleaning but will also save time and possibly decrease the discomfort to the patient as handling is reduced. The stream can also be directed into less accessible areas.

#### ACKNOWLEDGMENT

Mr. Raja and Mr. Iyyengar from DermaIndia<sup>®</sup> for choosing and providing the pump and attachments

**C. R. Srinivas**

Department of Dermatology, PSG Hospitals, Peelamedu,  
Coimbatore, India

**Address for correspondence:** Dr. C. R. Srinivas,  
Department of Dermatology, PSG Hospitals, Peelamedu,  
Coimbatore - 641 004. Tamil Nadu, India.  
E-mail: srini\_cr\_1955@yahoo.com