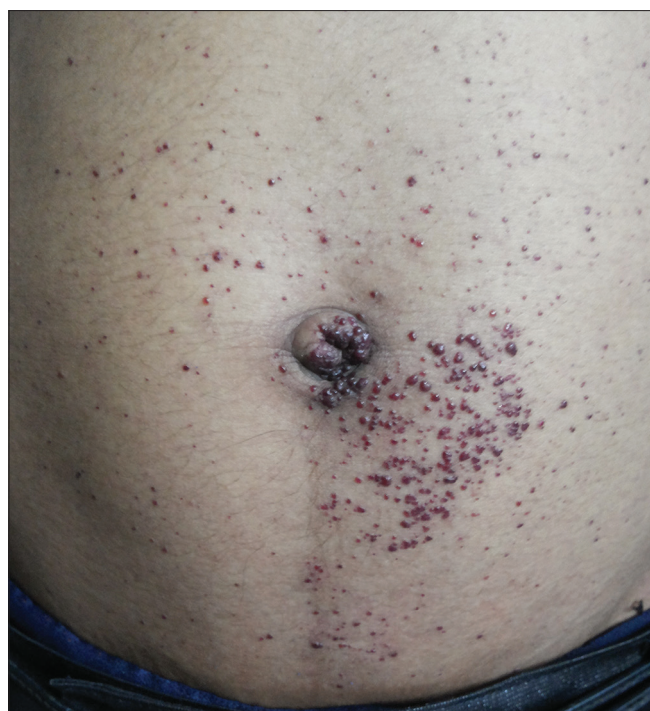

## Multiple reddish papules in the bathing trunk distribution

A 20-year-old boy presented with multiple, discrete, 2-4 mm sized, red-purple papules on the arms, trunk, penis, scrotum and legs, becoming confluent around the umbilicus [Figure 1]. The papules started appearing 3 years ago on his thighs and occasionally bled on trauma, without any other symptoms. The patient had episodic burning pain in both hands and feet, heat intolerance and decreased sweating. There was no history of abdominal pain, bone pain, edema of the feet, auditory or neurological complaints

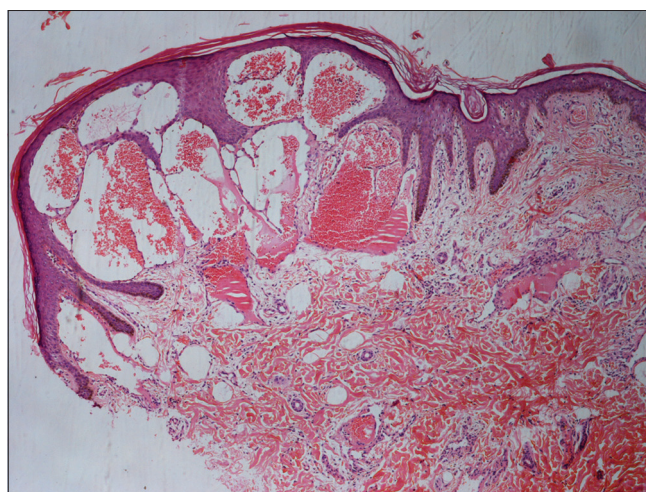


**Figure 1:** Multiple, red to purple, hyperkeratotic papules on anterior trunk with grouping around umbilicus

or significant drug intake. No other family member had similar features. Systemic and ophthalmic evaluations revealed no abnormalities.

Routine hematological tests, coagulation profile, electrocardiography and chest radiographs were normal. Renal function analysis showed mild proteinuria, up to 0.46 g/L. The  $\alpha$ -galactosidase enzyme assay on dried blood spots was 0.55 nmol/h/ml (normal 3–20 nmol/h/ml). Biopsy of a papule showed hyperkeratosis, acanthosis and papillomatosis with dilated and congested vessels, lined by endothelium within dermal papillae [Figure 2].

### What is Your Diagnosis?



**Figure 2:** Hyperkeratosis of epidermis with acanthosis and papillomatosis, and dilated and congested vessels lined by endothelium in the dermal papillae (H and E,  $\times 100$ )

#### Access this article online

##### Quick Response Code:



##### Website:

www.ijdvl.com

##### DOI:

10.4103/0378-6323.190872

This is an open access article distributed under the terms of the Creative Commons Attribution-NonCommercial-ShareAlike 3.0 License, which allows others to remix, tweak, and build upon the work non-commercially, as long as the author is credited and the new creations are licensed under the identical terms.

**For reprints contact:** reprints@medknow.com

**How to cite this article:** Bhushan P, Dorjay K. Multiple reddish papules in the bathing trunk distribution. Indian J Dermatol Venereol Leprol 2017;83:274-5.

**Received:** August, 2015. **Accepted:** February, 2016.

**Answer**

Diagnosis: Angiokeratoma corporis diffusum (Fabry's disease).

**Discussion**

Angiokeratomas are vascular ectasia with hyperkeratotic overlying epidermis. They can be localized or generalized. Localized forms include solitary papular angiokeratoma, angiokeratoma circumscriptum, angiokeratoma of Mibelli and angiokeratoma of Fordyce.<sup>[1]</sup> The generalized form, angiokeratoma corporis diffusum, is classically associated with Fabry's disease with a bathing trunk distribution of lesions, i.e. concentrated between knees and umbilicus.<sup>[1-3]</sup> However, these may also be seen in other diseases such as fucosidosis, aspartylglucosaminuria, galactosialidosis, Schindler/Kanzaki disease, and sialidosis or these may even be idiopathic.<sup>[1]</sup> The angiokeratomas of all these conditions are clinically similar, but can be differentiated on the basis of electron microscopy (showing zebra-like inclusion bodies in Fabry's disease).<sup>[2]</sup>

Fabry's disease is a X-linked lysosomal storage disease, due to partial or complete deficiency of  $\alpha$ -galactosidase A.<sup>[2]</sup> The clinical manifestations presumably result from the accumulation of globotriaosylceramide. The cutaneous manifestations of Fabry's disease include telangiectasias, macular and papular vascular lesions, acromegaly-like facies, heat intolerance, decreased or increased sweating, Raynaud's phenomenon and lymphedema of legs, besides the classical angiokeratomas. Fabry's-like disease has also been described with chloroquine toxicity.<sup>[4]</sup> The vascular lesions of Fabry's disease, including angiokeratomas, have been reported to be markers of a higher propensity for systemic involvement.<sup>[3]</sup>

Fabry's disease is a multisystem disease. Acroparesthesias are typically seen in the first two decades and generally improves subsequently.<sup>[2]</sup> Other manifestations are generally progressive and include cardiac (left ventricular dilatation and hypertrophy, mitral valve regurgitation and arrhythmias), ocular (cornea verticillata, retinal vessel tortuosity, optic atrophy, cataracts and lenticular changes), renal (proteinuria, declining renal function and Maltese cross appearance of crystals in urine on polarized light), cerebrovascular/neural (transient ischemic attacks, vertigo, dizziness and high frequency hearing loss) and gastrointestinal (cramps and diarrhea) abnormalities.<sup>[1-3]</sup> The diagnosis can be confirmed by the estimation of  $\alpha$ -galactosidase A. Low serum  $\alpha$ -galactosidase A level is sufficient for the diagnosis in men, but in women, enzyme levels may be normal so genetic studies are mandatory.<sup>[2]</sup> In heterozygous women, the expression of disease is variable, but, generally the onset is delayed and organ damage is less severe. Overall, the life

expectancy is reduced by 20 and 10 years in men and women, respectively.<sup>[2]</sup>

Early diagnosis of Fabry's disease is important because of systemic involvement and complications worsen with time. Dermatologists are often the first to make the diagnosis, because most of the patients are concerned with the cutaneous eruption. A multimodal approach is needed to treat the varied manifestations of the disease.<sup>[2]</sup> Angiokeratomas may be palliatively removed with cryotherapy, electrofulguration or vascular lasers. In 2001, enzyme replacement therapy was introduced in Europe for Fabry's disease with marked improvement in renal function, cardiac mass, abdominal symptoms and overall quality of life.<sup>[2,5]</sup> The cost of enzyme replacement therapy may be prohibitive for most patients. Reduction in the cost of enzyme replacement therapy will enable these patients to live a normal life.

**Financial support and sponsorship**

Nil.

**Conflicts of interest**

There are no conflicts of interest.

**Premanshu Bhushan, Konchok Dorjay**

Department of Dermatology, Dr. PN Behl Skin Institute and School of Dermatology, New Delhi, India

**Correspondence:** Dr. Konchok Dorjay,  
Dr. PN Behl Skin Institute and School of Dermatology, Greater Kailash-1, New Delhi - 110 048, India.  
E-mail: konchokyokhang@gmail.com

**References**

1. Karen JK, Hale EK, Ma L. Angiokeratoma corporis diffusum (Fabry disease). *Dermatol Online J* 2005;11:8.
2. Germain DP. Fabry disease. *Orphanet J Rare Dis* 2010;5:30.
3. Orteu CH, Jansen T, Lidove O, Jaussaud R, Hughes DA, Pintos-Morell G, *et al.* Fabry disease and the skin: Data from FOS, the Fabry outcome survey. *Br J Dermatol* 2007;157:331-7.
4. Roos JM, Aubry MC, Edwards WD. Chloroquine cardiotoxicity: Clinicopathologic features in three patients and comparison with three patients with Fabry disease. *Cardiovasc Pathol* 2002;11:277-83.
5. De Schoenmakere G, Chauveau D, Grünfeld JP. Enzyme replacement therapy in Anderson-Fabry's disease: Beneficial clinical effect on vital organ function. *Nephrol Dial Transplant* 2003;18:33-5.