

pattern is the most common presentation, many unusual forms, like poikilodermatous, diffuse, bullous, nevoid, linear, amyloidosis cutis dyschromica and incontinentia pigmenti-like have been reported.<sup>6</sup>

We report this case for its unusual appearance as well as rare site of presentation.

**Declaration of patient consent:** The authors certify that they have obtained all appropriate patient consent.

**Financial support and sponsorship:** Nil.

**Conflicts of interest:** There are no conflicts of interest.

**Use of artificial intelligence (AI)-assisted technology for manuscript preparation:** The authors confirm that there was no use of artificial intelligence (AI)-assisted technology for assisting in the writing or editing of the manuscript and no images were manipulated using AI.

**Preema Sinha<sup>1</sup>, Akansha Tripathi<sup>1</sup>,  
Manoj Gopal Madakshira<sup>2</sup>, Prashantha GB<sup>1</sup>,  
Choudhary Sampoorna Raj<sup>1</sup>**

<sup>1</sup>Department of Dermatology, Base hospital Lucknow, Lucknow,

<sup>2</sup>Department of Pathology, Command Hospital, Lucknow, India

**Corresponding author:**

Dr. Preema Sinha,

Department of Dermatology, Base hospital Lucknow, Lucknow,  
India.

drpreemasinha@gmail.com

## References

1. Mehrotra K, Dewan R, Kumar JV, Dewan A. Primary cutaneous amyloidosis: A clinical, histopathological and immunofluorescence study. *J Clin Diagn Res* 2017;11:WC01–5.
2. Guillet C, Steinmann S, Maul JT, Kolm I. Primary localized cutaneous amyloidosis: A retrospective study of an uncommon skin disease in the largest tertiary care center in Switzerland. *Dermatol* 2022;238: 579–86.
3. Konmettu AP, Gurumurthy C, Rangappa V, Shastry V. Frictional melanosis and macular amyloidosis-exploring the link. *Pigment Int* 2022;9:166–75.
4. Bandhlsh A, Aggarwal A, Koranne R. A clinico-epidemiological study of macular amyloidosis from North India. *Indian J Dermatol* 2012;57:269.
5. Venkataram M, Shashikant MBA. Frictional melanosis and its clinical and histopathological features. *Iran J Dermatol* 2018;21:124–7.
6. Somani VK, Somani A, Sarkar R. Primary localized cutaneous amyloidosis – A review. *Pigment Int* 2023;10:4–13.

# Ectodermal dysplasia-skin fragility syndrome – identification of a novel plakophilin1 (*PKP1*) gene variant through whole exome sequencing

Dear Editor,

A 16-year-old boy, presented with generalised skin erosions, dryness and cracking of lips, thickened skin on the palms and soles, abnormal nails, and woolly hair. The symptoms started at the age of 3 months with gradual progression. He was the first child of a second-degree consanguineous marriage, with his younger sister and both parents being asymptomatic. On physical examination, his height (147 cm) and weight (33 kg) were below the third centile for his age, with a normal gait. Cutaneous examination revealed generalised xerosis with features of skin fragility in the form of numerous superficial skin erosions with crusting on the upper back [Figure 1a], chest, and limbs, with the face being relatively spared. Palmoplantar keratoderma was present with superficial

fissures [Figures 1b and 1c]. The scalp showed coarse woolly hair, without alopecia/hypotrichosis, but with remarkably easy pluckability [Figure 1d]. The eyebrows looked thick and dense, with the eyelashes being normal. The lips and perioral region were red, scaly, and fissured [Figure 1e]. Nails were dystrophic with subungual hyperkeratosis and distal curving. A general examination of all other systems, including the cardiovascular system, was normal.

A trichogram of plucked hair showed dystrophic anagen hair. Histopathology revealed widened intercellular spaces with a split in the sub-corneal layer [Figure 2a].

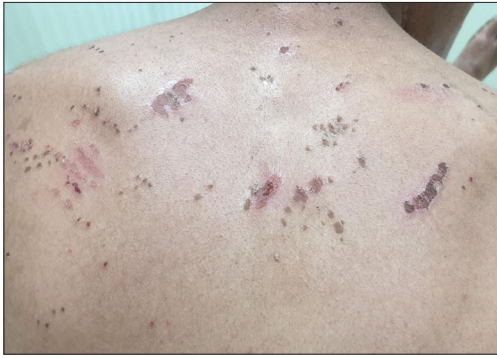Scanning electron microscopy (SEM) of hair revealed damaged, rough cuticles with paint brush fractures of the cortex and dystrophic anagen roots [Figures 2b and 2c].

**How to cite this article:** Konda SC, Biswas A, Konda A, Rao VR, Adepu V. Ectodermal dysplasia-skin fragility syndrome – identification of a novel plakophilin1 (*PKP1*) gene variant through whole exome sequencing. *Indian J Dermatol Venereol Leprol*. 2025;91:381-5. doi: 10.25259/IJDVL\_420\_2023

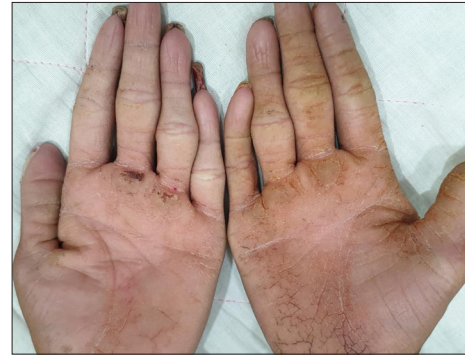**Received:** April, 2023 **Accepted:** October, 2023 **Epub Ahead of Print:** March, 2024 **Published:** April, 2025

**DOI:** 10.25259/IJDVL\_420\_2023 **PMID:** 38595014

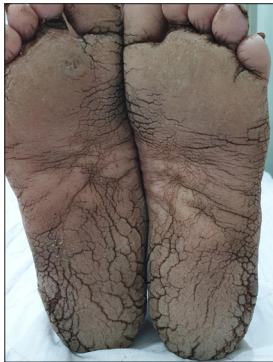This is an open-access article distributed under the terms of the Creative Commons Attribution-Non Commercial-Share Alike 4.0 License, which allows others to remix, transform, and build upon the work non-commercially, as long as the author is credited and the new creations are licensed under the identical terms.



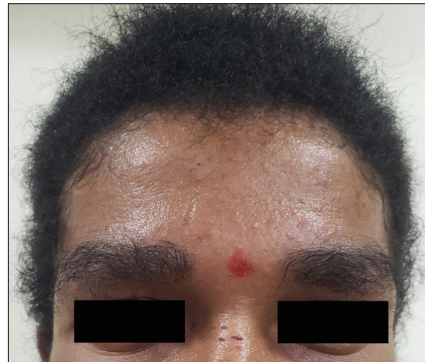**Figure 1a:** Superficial erosions on the upper trunk.



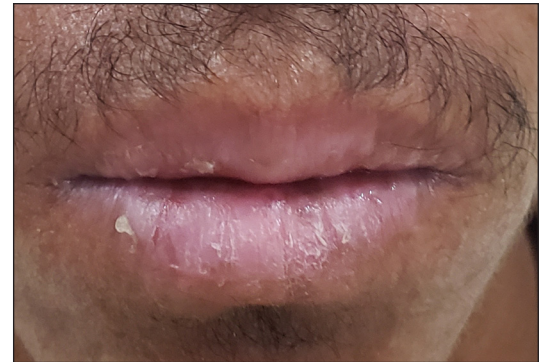**Figure 1b:** Palmar keratoderma.



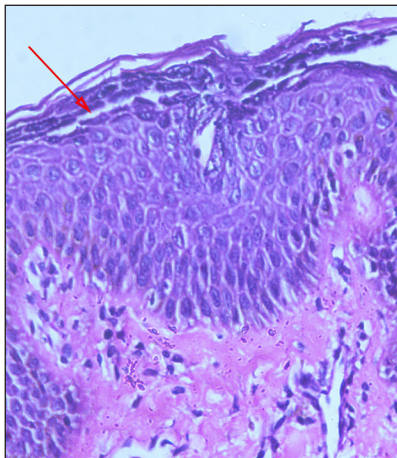
**Figure 1c:** Plantar keratoderma.



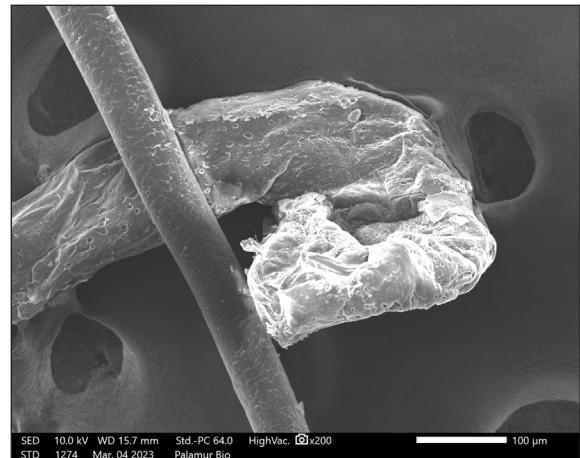
**Figure 1d:** Scalp and eyebrows showing woolly hair.



**Figure 1e:** Erosions and scaling of lips.



**Figure 2a:** Histopathology of skin (Haematoxylin and eosin, 40x) staining with arrow showing the blister.




**Figure 2b:** Scanning electron microscopic (SEM) image of hair showing dystrophic anagen root.

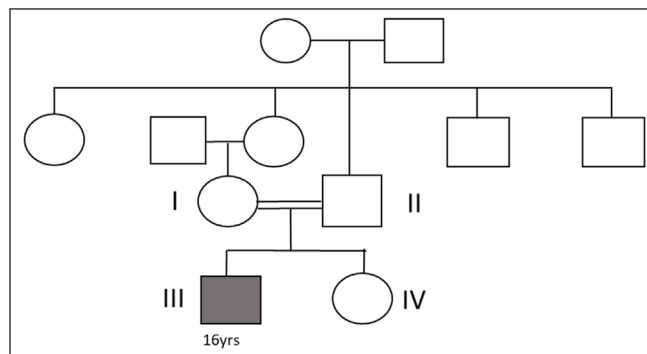
Whole-exome sequencing identified a novel missense variant, c.1061T>C (p. Leu354Pro) in exon 6 of plakophilin 1 gene. This variant was validated using sanger sequencing in the proband, parents, and younger sister. Both the parents and the sister were heterozygous, whereas the proband was homozygous for the mutant variant [Figures 3a and 3b]. Pathogenicity prediction software tools predicted this variant to be deleterious. The 3D structure of the wild and mutant

protein showed a change in the orientation of amino acid—producing destabilizing effects [Figure 3c].

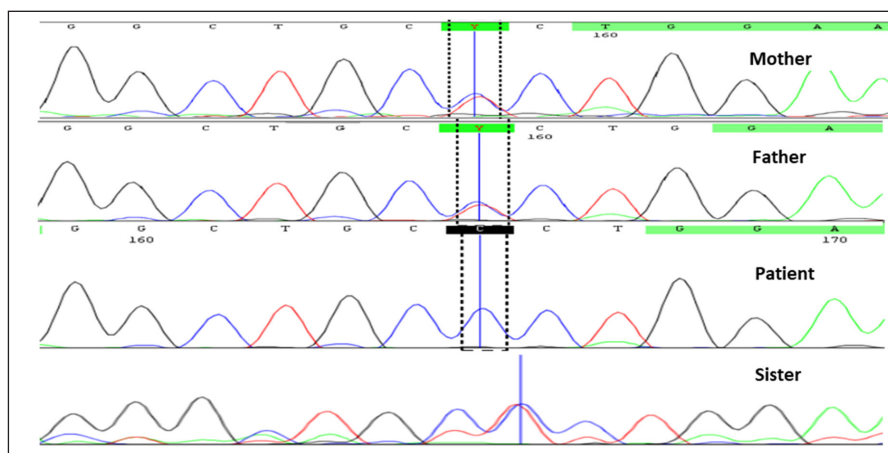
The differential diagnoses considered were generalised epidermolysis bullosa simplex (excluded by lack of extensive blisters), Naxos and Carvajal syndrome (excluded by lack of cardiomyopathy), and Kindler epidermolysis bullosa (excluded by lack of photosensitivity and poikiloderma).



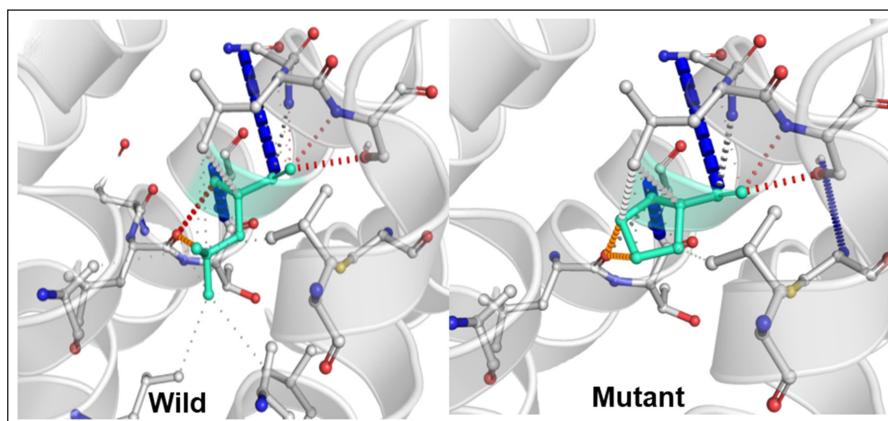
**Figure 2c:** Scanning electron microscopic image of hair showing fractured cortex.



**Figure 3a:** Family pedigree: Gray box shows the affected proband.



**Figure 3b:** Sanger sequencing showing homozygous variation in the proband as compared to parents and sibling.



**Figure 3c:** Destabilizing change in orientation of protein structure due to the presence of a mutation.

As there are no specific treatments for this condition, the boy was managed conservatively with moisturisers and topical antibacterials for skin lesions, lip balms for the lips, and keratolytic creams for the palms and soles.

## Discussion

Desmosomes are junctions essential for preserving tissue integrity by tethering adjoining cells and anchoring the cell membrane to the keratin intermediate filament

cytoskeleton internally. These are intercellular junctional complexes primarily found in epithelial tissues but also in meninges, lymph node follicles, and myocardium.<sup>1</sup> The main structural constituents of desmosomes are a) the cadherins – desmogleins and desmocollins; b) the plakins – desmoplakin, periplakin, and envoplakin; and c) the armadillo family of proteins – plakoglobin, plakophilins (PKP1 and 2). These interact with one another near the plasma membrane and with keratin intermediate filaments in the cytoplasm. Ectodermal



Table 1: Studies that reported PKP1 variants for EDSF syndrome

S. No	Age (years)/ Gender	Origin/Ethnicity	Parental consanguinity	Zygosity	Variant, AA change	Variation
1 <sup>2</sup>	6/M	British	No	Compound heterozygous	c.910C>T – p.Gln304* c.1132ins28 – NA	Nonsense Frameshift
2 <sup>3</sup>	0.5/F	Arab	Yes	Homozygous	c.847-2A>G – N/A	Splice site
3 <sup>3</sup>	3/F	Arab	Yes	Homozygous	c.203-1G>A – N/A	Splice site
4 <sup>5</sup>	1/F	Egyptian (case 1)	Yes	Homozygous	c409_410insAC – p.Thr137Thrfs*61	Frameshift
5 <sup>5</sup>	0.9/M	Egyptian (case 2)	No	Homozygous	c1213delA – p.Arg411Glufs*22	Frameshift
6 <sup>6</sup>	8/M	Chinese	No	Homozygous	c.723delG – p.E241Dfs*4	Frameshift
7 <sup>7</sup>	1.5/M	British	No	Compound heterozygous	c.203-1G>A – N/A c.213T>G – p.Tyr71*	Splice site Nonsense
8 <sup>8</sup>	17/M	British	No	Homozygous	c.1233-2A>T – N/A	Splice site
9 <sup>9</sup>	42/M	Japan	Yes	Homozygous	c.2021+1G>A – N/A	Splice site
10 <sup>10</sup>	33/M	Dutch	N/A	Homozygous	c1680+1G>A – N/A	Splice site
11 <sup>11</sup>	3/F	Chinese	No	Compound heterozygous	c.1835-2A>G – N/A c.1053T>A+1054 – N/A +1G>T	Splice site
12 <sup>12</sup>	6/M	Turkish	Yes	Homozygous	c.888delC-p.Arg297Alafs*42	Frameshift
13 <sup>13</sup>	10/M	Brazilian	Yes	Homozygous	c.2014C>T – p.Arg672*	Nonsense
14 <sup>14</sup>	1.2/F	Iraqi	Yes	Homozygous	c.897del5 – p.Asn300Gluys*60	Frameshift
15 <sup>15</sup>	15/M	Spanish	N/A	Homozygous	c.1233-2A>G – N/A	Splice site
16 <sup>16</sup>	5/F	Egyptian	Yes	Homozygous	c.203-1G>T – N/A	Splice site
17 <sup>16</sup>	4/F	Egyptian	Yes	Homozygous	c.203-1G>T – N/A	Splice site
18 <sup>17</sup>	27/F	Turkish	Yes	Homozygous	c.1411-9G>A – N/A	Splice site
19 <sup>18</sup>	29/M	Turkish	Yes	Homozygous	c.1414_1415delTG – p.Val472Glyfs*28	Frameshift
20 <sup>19</sup>	2/F	Caucasian	No	Homozygous in lesional skin	c.638delT – p.V213Gfs*33	Frameshift
21 <sup>20</sup>	5/M	Chinese	N/A	Homozygous	c.203-1G>A – N/A	Splice site
22 <sup>21</sup>	16/F	Spanish	Yes	Homozygous	c.455C>T – p.Ala152Val	Missense
23 <sup>21</sup>	Neonate/F	Spanish	Yes	Homozygous	c.455C>T – p.Ala152Val	Missense
24 <sup>**</sup>	16/M	Indian	Yes	Homozygous	C1061T>C p.Leu354Pro	Missense

PKP 1: Plakophilin 1, EDSF: Ectodermal dysplasia skin fragility syndrome, M: Male, F: Female, N/A: Not available, AA: Amino acid, \*: Stop codon, \*\*: Present study.

dysplasia-skin fragility syndrome, first described by McGrath *et al.*<sup>2</sup> is a rare autosomal recessive genodermatosis characterised by cutaneous erosions/blisters, palmoplantar keratoderma, hair abnormalities/alopecia, characteristic lip scaling with fissures and nail dystrophy resulting from loss of function mutations in the Plakophilin 1 (*PKP1*) gene.<sup>2</sup>

An ectodermal dysplasia-skin fragility syndrome patient born out of consanguineous marriage and possessing a homozygous variant in the *PKP1* gene causing a substitution of leucine with proline at codon 1061 is described here. In the literature review of all reported cases [Table 1], homozygosity was present in 87% and parental consanguinity was present in 66% of cases, including the present case. Twenty three cases have been reported with confirmed bi-allelic mutations in the *PKP1* gene, ours being the latest. Structurally, PKP1 is located close to the plasma membrane in the desmosomal plaque, binding and interacting primarily with desmoplakin (via the amino-terminal domain).<sup>2,3</sup>

Desmosomal PKP1 distribution is concentrated in the suprabasal layers of stratified and complex epithelia such as

skin, outer root sheath cells of hair follicles, etc.<sup>4</sup> PKP1 is a multifunctional protein promoting desmosomal stability.<sup>5</sup> In previously reported studies, skin fragility, and nail involvement were present in all 23 cases, as in our case. Perioral and lip erythema, scaling and fissures were reported in 18/23 cases, palmoplantar keratoderma in 21/23 cases and alopecia/hypotrichosis/woolly hair in 22/23 cases. Additionally, hypohidrosis was reported in 6/23 cases and pruritus, dental anomalies, recurrent cutaneous infections, pneumonia, delayed milestones, and low height and weight centiles were present in a few cases.<sup>3</sup> We observed that ectodermal dysplasia-skin fragility syndrome occurred in all ethnic populations [Table 1]. Mutations in the head domain (5'-N-terminal) resulted in absent or markedly decreased PKP1 with an early onset of symptoms that were severe in nature, especially skin fragility (average age 2.9 years). Further down mutations towards the C-terminal/3'end resulted in reduced PKP1 and milder symptoms with later onset (average age 28.2 years). Mutations in the armadillo repeat units 1, 2, and 3 were associated with woolly/curly/wiry hair, including our case.

Perioral and lip scaling and fissuring is a persistent and prominent distinguishing feature that should prompt the clinician to consider ectodermal dysplasia-skin fragility syndrome. Hair pathology varied from total alopecia to sparse and woolly hair, which is due to abnormal or absent PKP1 in the suprabasal cells of the outer root sheath of hair follicles. The hair in our patient was normal at birth but subsequently became woolly and was strikingly easily pluckable, which was not reported in any other case. Similar trichogram and scanning electron microscopy hair findings were reported in 2020 by Sun *et al.*<sup>6</sup>

## Conclusion

PKP1 mutations, though rare, constitute an important disorder of desmosomes with core clinical features of skin fragility, lip, and perioral scaling, nail abnormalities, palmoplantar keratoderma and alopecia/hypotrichosis/woolly hair. We herewith report a case of ectodermal dysplasia-skin fragility/McGrath syndrome in an Indian boy with a novel homozygous missense mutation in the PKP1 gene, in exon 6 in the armadillo repeat region motif-3 with a review and expansion of current literature on the PKP1 mutation database and phenotype-genotype correlation.

**Declaration of patient consent:** The authors certify that they have obtained all appropriate patient consent.

**Financial support and sponsorship:** Nil.

**Conflicts of interest:** There are no conflicts of interest.

**Use of artificial intelligence (AI)-assisted technology for manuscript preparation:** The authors confirm that there was no use of artificial intelligence (AI)-assisted technology for assisting in the writing or editing of the manuscript and no images were manipulated using AI.

**Sharath Chandra Konda<sup>1</sup>, Amitabh Biswas<sup>2</sup>,  
Amritha Konda<sup>3</sup>, Vadlamudi Raghavendra Rao<sup>4</sup>,  
Vilas Adepu<sup>5</sup>**

<sup>1</sup>Department of Dermatology, SVS Medical College, Yenugonda, Telangana, <sup>2</sup>Department of Orthogenetics Lab and Orthopedics, All India Institute of Medical Sciences, New Delhi, <sup>3</sup>General Medicine, SVS Medical College, Paulsagutta, Telangana, <sup>4</sup>Department of Genetics, Genome Foundation, Hyderabad, Telangana, <sup>5</sup>Consultant Dermatologist, Dr Vilas Skin and Hair Center, Banjara Hills, Hyderabad, Telangana, India

## Corresponding author:

Dr. Sharath Chandra Konda,  
Department of Dermatology, SVS Medical College, Yenugonda,  
Telangana, India.  
drsharath2k@yahoo.co.in

## References

- South A P. Plakophilin 1: An important stabiliser of desmosomes. *Clin Exp Dermatol* 2004;29:161–7.
- McGrath JA, McMillan JR, Shemanko CS, Runswick SK, Leigh IM, Lane EB, *et al.* Mutations in the plakophilin 1 gene result in ectodermal dysplasia/skin fragility syndrome. *Nat Genet* 1997;17:240–4.
- Sprecher E, Molho-Pessach V, Ingber A, Sagi E, Indelman M, Bergman R. Homozygous splice site mutations in PKP1 result in loss of epidermal plakophilin 1 expression and underlie ectodermal dysplasia/skin fragility syndrome in two consanguineous families. *J Invest Dermatol* 2004;122:647–51.
- Adhe VS, Dongre AM, Khopkar US. Ectodermal dysplasia-skin fragility syndrome. *Indian J Dermatol Venereol Leprol* 2011;77:503–6.
- Doolan BJ, Goma NS, Fawzy MM, Dogheim NN, Liu L, Mellerio JE, *et al.* Ectodermal dysplasia-skin fragility syndrome: Two new cases and review of this desmosomal genodermatosis. *Exp Dermatol* 2020;29:520–30.
- Sun B, Ran X, Wen P, Liu L, Wang X, Li M, *et al.* Novel homozygous deletion of the plakophilin-1 gene in a Chinese patient with ectodermal dysplasia-skin fragility syndrome. *J Dermatol* 2020;47:779–81.
- McGrath JA, Hoeger PH, Christiano AM, McMillan JR, Mellerio JE, Ashton GHS, *et al.* Skin fragility and hypohidrotic ectodermal dysplasia resulting from ablation of plakophilin 1. *Br J Dermatol* 1999;140:297–307.
- Whitlock NV, Haftek M, Angoulvant N, Wolf F, Perrot H, Eady Raj, *et al.* Genomic amplification of the human plakophilin 1 gene and detection of a new mutation in ectodermal dysplasia/skin fragility syndrome. *J Invest Dermatol* 2000;115:368–74.
- Hamada T, South AP, Mitsuhashi Y, Kinebuchi T, Bleck O, Ashton GHS, *et al.* Genotype-phenotype correlation in skin fragility-ectodermal dysplasia syndrome resulting from mutations in plakophilin 1. *Exp Dermatol* 2002;11:107–14.
- Steijlen PM, Van Steensel MAM, Jansen BJH, Blokx W, Van de Kerkhof PCM, Happle R, *et al.* *J Invest Dermatol* 2004;122:1321–4.
- Zheng R, Bu DF, Zhu XJ. Compound heterozygosity for new splice site mutations in the plakophilin 1 gene (PKP 1) in a Chinese case of ectodermal dysplasia-skin fragility syndrome. *Acta Derm Venereol* 2005;85:394–9.
- Ersay-Evans S, Erkin G, Fassihi H, Chan I, Paller AS, Surucu S, *et al.* Ectodermal dysplasia-skin fragility syndrome resulting from a new homozygous mutation, 888delC, in the desmosomal protein plakophilin 1. *J Am Acad Dermatol* 2006;55:157–61.
- Tanaka A, Lai-Cheong JE, Café MEM, Gontijo B, Salomao PR, Pereira L, *et al.* Novel truncating mutations in PKP 1 and DSP cause similar skin phenotypes in two Brazilian families. *Br J Dermatol* 2009;160:692–7.
- Boyce AE, McGrath JA, Techanukul T, Murrell DF, Chow CW, McGregor L, *et al.* Ectodermal dysplasia-skin fragility syndrome due to a new homozygous internal deletion in the PKP1 gene. *Australas J Dermatol* 2012;53:61–5.
- Hernandez-Martin A, Torrelo A, Ciria S, Colmenero I, Aguilar A, Grimalt R, *et al.* Ectodermal dysplasia-skin fragility syndrome: A novel mutation in the PKP1 gene. *Clin Exp Dermatol* 2013;38:787–90.
- Abdalla EM, Has C. A plakophilin-1 gene mutation in an Egyptian family with ectodermal dysplasia-skin fragility syndrome. *Mol Syndromol* 2014;5:304–6.
- Hsu CK, Liu L, Can PK, Kocaturk E, McMillan JR, Gungor S, *et al.* *J Dermatol Sci* 2016;84:210.
- Alatas ET, Kara A, Kara M, Dogan G, Baysal O. Ectodermal dysplasia-skin fragility syndrome with a new mutation. *Indian J Dermatol Venereol Leprol* 2017;83:476–9.
- Vazquez-Osorio I, Chmel N, Rodriguez-Diaz E, Gonzalvo-Rodriguez P, Happle R, Bueno E, *et al.* A case of mosaicism in ectodermal dysplasia-skin fragility syndrome. *Br J Dermatol* 2017;177:101–2.
- Ruan QF, Xia C, Xie WG. Histopathological and genetical diagnosis of one case of neonatal ectodermal dysplasia/skin fragility syndrome. *Zhonghua Shao Shang Za Zhi* 2020;36:500–2.
- Cuenca-Barrales C, Monserrat-Garcia MT, Dominguez-Cruz JJ, Sunol-Capella M, Zulueta-Dorado T, Fernandez R, *et al.* Ectodermal dysplasia-skin fragility syndrome: Two new cases with a novel missense mutation. *J Dtsch Dermatol Ges* 2020;19:595–7.