

Non-cultured epidermal cell suspension and laser resurfacing to improve the appearance of thick post-burn skin graft

Dear Editor,

Non-cultured epidermal cell suspension (NCES) has a variety of indications in pigmentary disorders apart from vitiligo, including post-burn depigmentation, post-herpetic depigmentation, chemical leukoderma and depigmentation in discoid lupus erythematosus patients.¹ In addition to depigmentation, non-cultured epidermal cell suspension has also been found to be useful to treat colour mismatch, variegation and textural changes that occur after surgery in vitiligo patients.² Non-cultured epidermal cell suspension is potentially useful to replace any uneven texture formed as a sequela of a disease or its intervention with a more uniform homogenous epidermis. Here, we present a novel

use of non-cultured epidermal cell suspension to improve the appearance of post-burn skin graft over the face.

An 18-year-old female presented to us seeking improvement in the appearance of a skin graft. She had severe burns on the left side of the face 10 years ago, for which a large, full-thickness skin graft using the thigh as the donor site was done 6 years ago by a plastic surgeon. At presentation, the thick graft was distinctly noticeable, being hyperpigmented and raised compared to the rest of the face [Figure 1a]. It also had prominent follicles and covered almost the whole of the left side of the face. The graft had a 'stuck-on' appearance on the face. The patient was highly dissatisfied with the appearance. She had not shown any significant improvement with the use

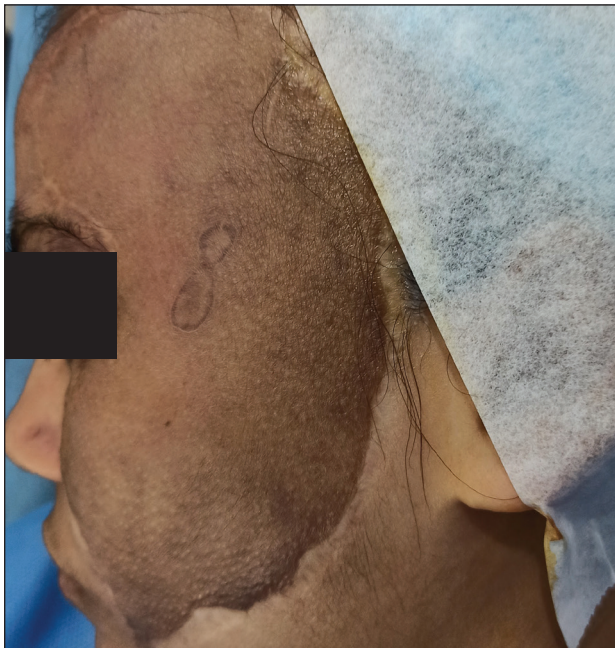


Figure 1a: A patient with a distinctly noticeable hyperpigmented thick post-burn graft on the face. The graft was elevated compared to the rest of the facial skin, appeared stuck-on and had prominent follicles. A small linear scarred area was present within the graft over the zygomatic ridge.

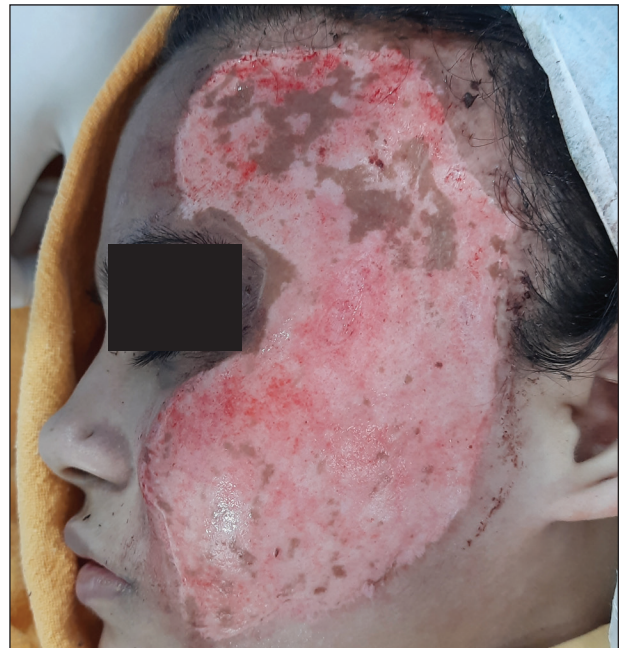


Figure 1b: Non-cultured epidermal cell suspension (NCES) for thick post-burn graft. The graft epidermis has been dermabraded.

How to cite this article: Mehta N, Taneja N, Gupta S. Non-cultured epidermal cell suspension and laser resurfacing to improve the appearance of thick post-burn skin graft. *Indian J Dermatol Venereol Leprol.* 2024;90:376–8. doi: 10.25259/IJDVL_402_2023

Received: April, 2023 **Accepted:** June, 2023 **Epub Ahead of Print:** July, 2023 **Published:** April, 2024

DOI: 10.25259/IJDVL_402_2023 **PMID:** 37609724

This is an open-access article distributed under the terms of the Creative Commons Attribution-Non Commercial-Share Alike 4.0 License, which allows others to remix, tweak, and build upon the work non-commercially, as long as the author is credited and the new creations are licensed under the identical terms.

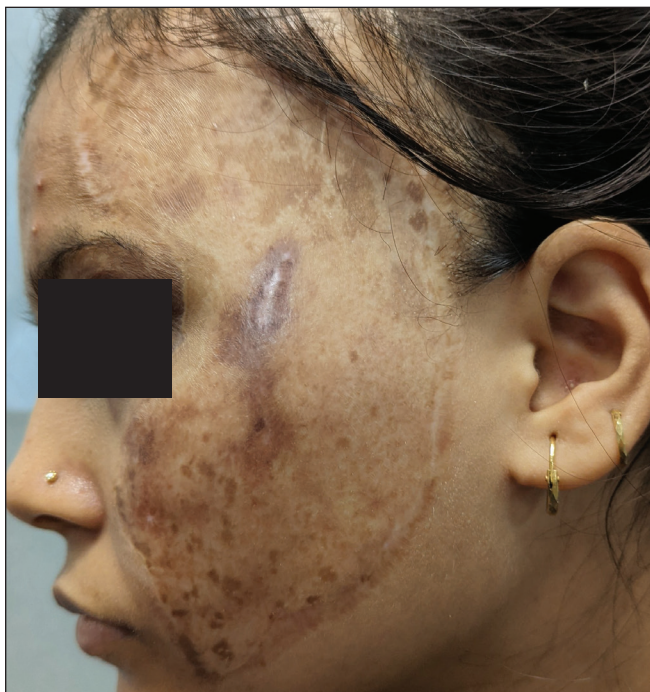

Figure 1c: One month after the non-cultured epidermal cell suspension session. There was significant improvement in the colour match and skin texture. The elevation was reduced and the follicular openings became less prominent. The linear scarred area over the zygomatic ridge healed slowly compared to the surrounding skin.

of modified Kligman's regimen for 3 months prior to taking up for surgery.

For non-cultured epidermal cell suspension, the cellular suspension was prepared using the standard technique.² The skin of the post-burn graft was superficially dermabraded till the level of papillary dermis (indicated by the development of pin-point bleeding) [Figure 1b]. The cell suspension was applied over the dermabraded area and then covered with dry collagen sheet, a transparent film dressing and an adhesive plaster. The dressing was removed after 1 week and the eroded area was allowed to heal spontaneously without any medications. One month after non-cultured epidermal cell suspension, the color of the grafted site matched well with the rest of the face and there was also moderate flattening of the tissue, getting rid of the stuck-on appearance [Figure 1c]. Subsequently, four sessions of fractional CO₂ laser ablation of the raised graft were done, at monthly intervals starting 2 months after the non-cultured epidermal cell suspension. This resulted in homogenisation of colour, further flattening of the graft, merging of the graft margins with the periphery, significant reduction of the follicular prominences and significant improvement in texture. However with time increased pigmentation was noticed in the grafted skin compared to the surrounding skin despite photo protection and sunscreen use [Figure 1d]. Overall, the graft was significantly less noticeable and the patient was moderately satisfied. The resultant graft had a much better aesthetic appearance, rated as 5 out of 10 on an investigator global assessment scale by

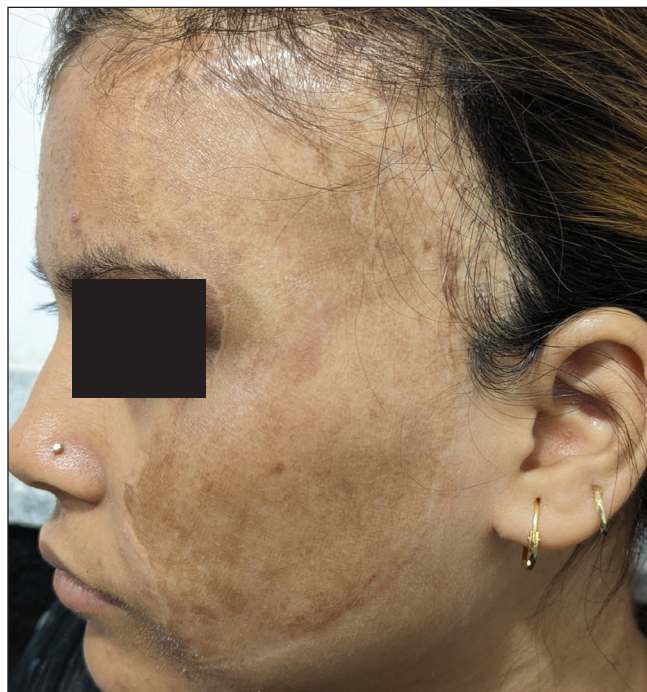

Figure 1d: Ten months after a single session of non-cultured epidermal cell suspension and four sessions of CO₂ laser. Further homogenisation of colour, flattening, merging of margins and improvement in texture, but there was hyperpigmentation on the skin of the graft. The patient was moderately satisfied with the resultant appearance.

us. The patient rated the overall improvement in appearance as 7 out of 10 on a visual analogue scale.

There were no immediate post-procedural complications and the patient tolerated the procedure well. A small previously scarred area over the zygomatic arch healed slowly with superficial erosions persisting till a month after procedure. Subsequently, it healed with mild dyspigmentation.

Epidermal cell suspension has been used for the management of burns and non-healing ulcers and wounds as it leads to faster re-epithelialization.^{3,4} Dermabrasion or ablative CO₂ laser alone without transplanting the non-cultured epidermal cell suspension would have resulted in a longer time to reepithelization for such a large surface area. Non-cultured epidermal cell suspension promoted faster healing and lesser inflammation. Non-cultured epidermal cell suspension combined with dermabrasion is also reported to improve dyspigmentation caused by vitiligo treatments and colour of scars.^{2,5} Therefore, we hypothesise that non-cultured epidermal cell suspension helped in achieving relatively homogenous lightening of the graft in this patient.

In conclusion, non-cultured epidermal cell suspension can be useful in alleviating the colour, texture and skin thickness mismatch between the thick skin grafts and the surrounding skin with good patient satisfaction.

Declaration of patient consent

The authors certify that they have obtained all appropriate patient consent.

Financial support and sponsorship

Nil.

Conflicts of interest

There are no conflicts of interest.

Nikhil Mehta, Neha Taneja, Somesh Gupta

Department of Dermatology and Venereology,
All India Institute of Medical Sciences, Delhi, India

Corresponding author:

Dr. Somesh Gupta,
Department of Dermatology and Venereology,
All India Institute of Medical Sciences, Delhi, India.
someshgupta@aiims.edu

References

- 1 Mulekar SV, Issa AA, Eisa AA. Treatment of post-burn leucoderma with non-cultured melanocyte-keratinocyte transplantation (MKTP). *Burns* 2011;37:448–52.
- 2 Taneja N, Sahni K, Gupta S. Autologous noncultured epidermal cell suspension for treatment of iatrogenic variegate repigmentation, textural changes and color mismatch in vitiligo. *Dermatol Ther* 2020;33:e14399.
- 3 De Angelis B, Migner A, Lucarini L, Agovino A, Cervelli V. The use of a non cultured autologous cell suspension to repair chronic ulcers. *Int Wound J* 2013;12:32–9.
- 4 Zhao H, Chen Y, Zhang C, Fu X. Autologous epidermal cell suspension: A promising treatment for chronic wounds. *J Tissue Viability* 2016;25:50–6.
- 5 Ren J, Liu J, Yu N, Zhang W, Qian H, Liu Z, *et al*. The use of noncultured regenerative epithelial suspension for improving skin color and scars: A report of 8 cases and review of the literature. *J Cosmet Dermatol* 2019;18:1487–94.

Intradermal vitamin C: A new paradigm in the treatment of exogenous ochronosis

Dear Editor,

Exogenous ochronosis is caused by prolonged use of hydroquinone-containing skin-lightening creams, leading to dark brown to blue-black skin pigmentation. Although multiple treatment options are available, the outcomes are frequently erratic, unpredictable and rarely satisfying. We have attempted to utilise intradermal vitamin C (ascorbic acid) for the treatment of exogenous ochronosis.

A 45-year-old Indian man visited the dermatology department with complaints of hyperpigmentation on both cheeks. He had been using various depigmenting creams on and off for 9 years; including application of unsupervised triple combination cream (2% hydroquinone, 0.05% tretinoin and 0.1% mometasone furoate) in the past 3 years. For the last 3 months, he reported worsening of pigmentation and appearance of erythema on both cheeks.

Clinical examination revealed presence of bilaterally symmetrical blue-black macules in a speckled pattern, with erythematous backgrounds on both cheeks [Figures 1a, 1b]. The prayer sign was observed over the forehead. Rest of the physical examination was unremarkable. Dermoscopy revealed irregular, dark brown to black globular, annular

and arciform structures, which obliterated some follicular openings and formed a curvilinear and worm-like pattern [Figure 1c]. Additionally, marked telangiectasia was evident in the background. The histological examination revealed a thinned-out epidermis, dense elastotic degeneration in superficial dermis and deposition of extracellular, yellowish-brown, banana-shaped, sickled or round ochronotic bodies [Figure 2].

Based on clinical, dermoscopic and histological findings, the patient was diagnosed to have exogenous ochronosis. He was strictly advised to avoid using any depigmenting cream and was prescribed broad spectrum sunscreen against ultraviolet, infrared and visible light. In addition, a barrier repair moisturiser containing hyaluronic acid, ceramide, squalene and lecithin was prescribed for one month. To address the pigmentation, 0.05–0.1 mL of vitamin C (500 mg/5 mL) was injected at 1 cm interval intradermally up to 1 mL (100 mg) per sitting every four weeks for three cycles. The patient experienced mild-to-moderate pain during the procedure. After one month, erythema subsided completely (100%) and after three months, 80% improvement in the hyperpigmentation was observed [Figures 3a, 3b and 3c].

How to cite this article: Gulwani PR, Parekh AR, Shah HA. Intradermal vitamin C: A new paradigm in the treatment of exogenous ochronosis. *Indian J Dermatol Venereol Leprol.* 2024;90:378–380. doi: 10.25259/IJDVL_890_2023

Received: August, 2023 **Accepted:** December, 2023 **EPub Ahead of Print:** March, 2024 **Published:** April, 2024

DOI: 10.25259/IJDVL_890_2023 **PMID:** 38595002