

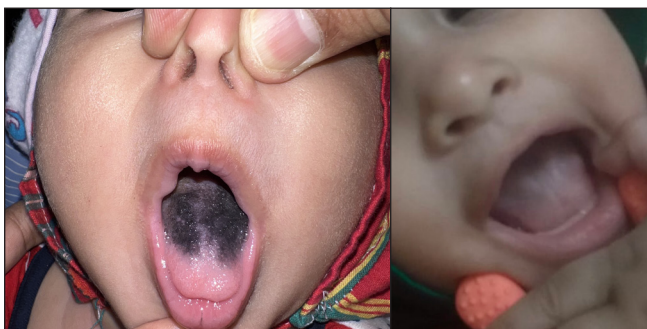
# Lingua villosa nigra in an infant

Dear Editor,

Black hairy tongue (BHT) or lingua villosa nigra is an acquired, asymptomatic, benign and self-limiting condition rarely seen in infancy.<sup>1</sup> It gets its name due to the hypertrophic reaction of keratin seen in filiform papillae giving it a black hairy appearance. This condition is commonly seen in adults above the age of 40 years and is uncommon in infancy.

Here, we report the case of an infant with BHT and discuss the various differential diagnoses of pigmentation in the oral cavity. A 6-month-old male child was brought by worried parents to the dermatology outpatients with complaints of sudden blackish discolouration of the tongue that was noticed a week ago. No prior history of intake of antibiotics or any other medication was reported. The child was still exclusively breastfed and the mother reported no change in the feeding habits and no feeding difficulties since the onset of the lesion. The infant's birth history was unremarkable. No family history of Addison's disease was reported. The child was otherwise normal with no other muco-cutaneous findings.

On examination, there was diffuse black discolouration of the dorsum of the tongue sparing the tip and lateral borders [Figure 1]. The scraping from the tongue revealed only epithelial cells and a few bacteria. A diagnosis of BHT was made. Parents were reassured regarding the benign and



**Figure 1:** Black discolouration of the dorsal surface of the tongue in a 6-month-old infant.

self-resolving nature of this condition. On follow-up after 4 weeks, there was complete clearance of the pigmentation.

BHT (Syn; lingua villosa nigra, keratomycesis linguae, verbatum<sup>2</sup> lingua or hyperkeratosis of the tongue) is a well-described and common pigmentary disorder of the tongue.<sup>2</sup> Delayed desquamation and retention of papillary cells result in build-up of keratin which contributes to the hairy appearance of the tongue, with the length of the papillae reaching more than three times the normal length of the filiform papillae.<sup>3</sup> Other than the black discoloration, the elongated papillae may appear brown, green or yellow in colour or may be devoid of any pigmentation. This retention leads to further changes in the oral environment leading to an increase in porphyrin-producing bacteria giving the characteristic black colour. However, other colours are not explained through the bacterial overgrowth and BHT is not considered a true infectious glossitis.<sup>4,5</sup>

The aetiology of BHT is not fully elucidated and is multifactorial. Various local and systemic insults contribute to an altered oral pH and promotion of chromogenic bacteria. A typical patient of BHT would be an older male smoker with a blackish coating on the tongue and complaints of dysgeusia, halitosis or a burning sensation in the mouth.<sup>2</sup> Infants presenting with BHT vary significantly from their adult counterparts [Table 1].<sup>2,5</sup> Epidemiological data regarding infantile BHT is scarce. All prior prevalence data is exclusive to adult BHT.<sup>5</sup> Differential diagnoses to be considered during infancy are congenital melanocytic naevus, pseudo BHT (chemical- or food colouring-induced discolouration), lingual melanotic macules, Addison's disease, pigmented fungiform papillae of the tongue and Peutz-Jeghers syndrome. Differential diagnoses and their classical features are mentioned in Table 2.<sup>2,3,5-7</sup>

Characteristic 'hairy' appearance of the dorsum of the tongue, sparing the rest of the oral cavity, including its lateral and anterior borders, makes BHT a straightforward diagnosis. Dermoscopy has been used to aid in the diagnosis as a non-invasive alternative to scraping.<sup>3</sup>

**How to cite this article:** Shah S, Hegde SS. Lingua villosa nigra in an infant. Indian J Dermatol Venereol Leprol. doi: 10.25259/IJDVL\_1145\_2023

**Received:** October, 2023 **Accepted:** April, 2024 **EPub Ahead of Print:** July, 2024

**DOI:** 10.25259/IJDVL\_1145\_2023

This is an open-access article distributed under the terms of the Creative Commons Attribution-Non Commercial-Share Alike 4.0 License, which allows others to remix, tweak, and build upon the work non-commercially, as long as the author is credited and the new creations are licensed under the identical terms.

**Table 1: Differences between infantile and adult black hairy tongue and differential diagnosis of black pigmentation in oral cavity**

Features	Adult black hairy tongue	Infantile black hairy tongue
Symptoms	- Common above the age of 40 years - Asymptomatic or associated with dysgeusia, halitosis, burning sensation or metallic taste	- Uncommon - Asymptomatic
Course	- Persists for years without treatment	- Self-limiting and resolves in a few weeks without treatment
Risk factors	- Smoking, poor oral hygiene, antibiotic use, xerostomia, trigeminal neuralgia, black tea drinkers, general illness, malignancy and HIV	- Unknown; possible dietary practices leading to a change in oral pH
Differential diagnosis	- Pseudo-black hairy tongue, pigmented fungiform papillae, acanthosis nigricans, oral hairy leukoplakia	- Oral melanotic macule, congenital melanocytic naevus, pigmented fungiform papillae, Peutz-Jeghers syndrome, Addison's disease, Laugier-Hunziker syndrome
Treatment	- Discontinuance of risk factors, improvement in oral hygiene, gentle brushing and scraping of the tongue - Anecdotal use of trichloroacetic acid, topical urea solution, topical triamcinolone acetonide, oral retinoids, salicylic acid and gentian violet	- No active management necessary in view of its self-resolving nature

**Table 2: Differential diagnosis of pigmentation in oral cavity**

Condition	Classical features
Black hairy tongue	- Elongated, dark filiform papillae - Dark hairy coat like plaque over the dorsum of the tongue, anterior to circumvallate papillae - Sparing the tip and lateral borders of the tongue - Can be black, blackish-brown or yellowish discolouration
Pseudo hairy tongue	- Pigmentation of the dorsum of the tongue without elongated filiform papillae involving the dorsum of the tongue - Caused by bismuth subsalicylate, antibiotics and anti-depressants, food colouring
Pigmented fungiform papillae of the tongue	- Pigmented fungiform papillae in a discrete or clustered morphology due to melanin-laden macrophages - Persistent and non-progressive involving the dorsal aspect of the tongue - Involves the tip and lateral borders of the tongue
Congenital melanotic macule	- Present at birth - Increased basal melanin pigmentation with melanophages and normal melanocyte number - Solitary or multiple flat pigmented lesions on the dorsum of the tongue or involving oral mucosa that is present since birth and show proportional growth
Oral congenital melanocytic nevi	- Present at birth - Well-demarcated plaques or papules showing homogenous or scattered pigmentation and small size - Involvement of buccal mucosa, gingiva, labial mucosa and palatal mucosa - Band-like infiltration of melanocytes coursing through the collagen bundles
Peutz-Jeghers syndrome	- Multiple small dark brown freckle-like pigmentation of lips and perioral skin and can extend to buccal mucosa that presents in childhood or adolescence - Monitor gastrointestinal involvement
Laugier-Hunziker syndrome	- Multiple brown macules in labial mucosa, palate, gingiva or tongue - Pigmentation occurs in adulthood and is associated with melanonychia
Addison's disease	- Patchy or diffuse oral pigmentation involving buccal mucosa, palatine arches, lips, gingiva or tongue - Associated with extra-oral manifestations of Addison's disease
Oral acanthosis nigricans	- Verrucous plaques, hypertrophy and papillomatosis of mucosa and papillae with or without associated pigmentation - Involvement of lips, palate, gingiva and tongue - Associated with internal malignancy
Oral hairy leukoplakia	- White hairy plaques involving the lateral and ventral surface of the tongue - Can also involve gingiva and buccal mucosa
Other differential diagnosis: amalgam tattoo, medication-induced hyperpigmentation, melanoacanthoma	

Management guidelines during infancy, where other contributing factors are ruled out, is the reassurance of worried parents regarding the benign and self-resolving nature of this condition. Better oral hygiene and gentle tongue scraping can promote desquamation.<sup>3</sup> Though lacking sufficient evidence, topical retinoid, urea, trichloroacetic acid, salicylic acid and gentian violet have also been suggested in adult BHT.<sup>3,8</sup>

Discoloured tongue or chromoglossia in an infant will always be a cause of worry for new parents but careful examination will ease a clinician to arrive at the diagnosis.

**Declaration of patient consent**

The authors certify that they have obtained all appropriate patient consent.

**Financial support and sponsorship**

Nil.

**Conflicts of interest**

There are no conflicts of interest.

### Use of artificial intelligence (AI)-assisted technology for manuscript preparation

The authors confirm that there was no use of artificial intelligence (AI)-assisted technology for assisting in the writing or editing of the manuscript and no images were manipulated using AI.

***Swapnil Shah, Shibhani Sudheer Hegde<sup>1</sup>***

Department of Dermatology, Ashvini Rural Medical College and Research Centre, Kumbhari district, Solapur, Maharashtra,

<sup>1</sup>Department of Dermatology, Bharati Vidyapeeth Medical College and Hospital, Katraj, Pune, India.

#### **Corresponding author:**

Dr. Shibhani Sudheer Hegde,  
Department of Dermatology, Bharati Vidyapeeth Medical College  
and Hospital, Katraj, Pune, India.  
shibhani.s.hegde@gmail.com

### References

1. Owczarek-Drabińska JE, Radwan-Oczko M. A case of lingua villosa nigra (black hairy tongue) in a 3-month-old infant. *Am J Case Rep* 2020;21:e926362.
2. Gurvits GE, Tan A. Black hairy tongue syndrome. *World J Gastroenterol* 2014;20:10845–50.
3. Schlager E, St Claire C, Ashack K, Khachemoune A. Black hairy tongue: predisposing factors, diagnosis, and treatment. *Am J Clin Dermatol* 2017;18:563–9.
4. Pouloupoulos AK, Antoniadis DZ, Epivatianos A, Grivea IN, Syrogiannopoulos GA. Black hairy tongue in a 2-month-old infant. *J Paediatr Child Health* 2008;44:377–9.
5. Rosebush MS, Briody AN, Cordell KG. Black and Brown: Non-neoplastic pigmentation of the oral mucosa. *Head Neck Pathol* 2019;13:47–55.
6. Rice SM, Lal K. Hyperpigmented macules of the tongue in a 15-year-old girl. *Pediatr Dermatol* 2021;38:941–2.
7. Júnior MH, Souza PE, Soares RV, de Andrade BA, de Almeida OP, Horta MC. oral congenital melanocytic nevus: A rare case report and review of the literature. *Head Neck Pathol* 2015;9:481–7.
8. Körber A, Voshege N. Black hairy tongue in an infant. *CMAJ* 2012;184:68.