

Exacerbation of head and neck eczema with new-onset alopecia following dupilumab treatment in severe atopic dermatitis patients: A case series

Dear Editor,

Atopic dermatitis (AD) is a chronic inflammatory skin disorder that may be comorbid with various autoimmune diseases, including alopecia areata (AA). Dupilumab, an interleukin (IL)-4 and IL-13 receptor antagonist, was approved by the FDA for the treatment of moderate-to-severe AD. Although some case reports have demonstrated improvement in AA with dupilumab, there are conflicting reports of patients developing new-onset hair loss during treatment.

Three of our severe AD patients, whose eczema area and severity index (EASI) scores were greater than 23, developed alopecic patches after treatment with dupilumab. None of the three patients had a history of hair loss, including AA. They presented with multiple, erythematous, scaly patches accompanied by conspicuous hair loss, which manifested between 8 and 12 weeks after treatment initiation [Figures 1a–1c]. Notably, the alopecic lesions primarily affected the parietal scalp regions in all patients; however, in the first patient, the hair loss rapidly progressed, encompassing the entire forehead. Interestingly, the patients manifested concurrent exacerbation of head and neck eczema,

with head and neck EASI scores increasing from 2.5 to 4.5 in the first patient and from 1.0 to 1.8 in the other patients. The first two patients observed spontaneous hair regrowth in 2 to 3 months while continuing dupilumab. The third patient, nevertheless, discontinued dupilumab upon experiencing abrupt hair loss accompanied by erythema along the frontal hairline after 8 weeks of starting treatment. A punch biopsy from the scalp was subjected to histopathologic examination which revealed parakeratosis, irregular acanthosis and marked spongiosis with perivascular lymphocytic infiltration predominantly in the papillary dermis, resembling subacute eczematous dermatitis [Figures 2a–2c]. After discontinuation of dupilumab, the patient received systemic steroids and cyclosporine, resulting in the gradual emergence of vellus hairs.

Multiple case reports and clinical studies suggest that dupilumab may act as a novel remedy for AA. It has been proposed that dupilumab could treat Th2-associated inflammation in the hair follicles and promote hair growth.¹ Nonetheless, there are multiple reports of patients developing alopecic patches while on dupilumab.^{2–7} These differences in

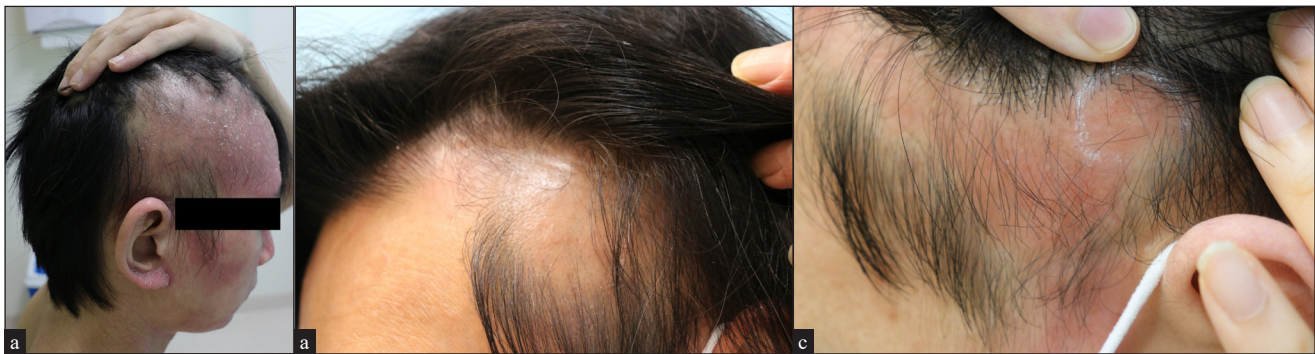

Figure 1: Three men with severe atopic dermatitis (a) 28-year old, (b) 47-year old and (c) 25-year old, presented with erythematous, diffuse, non-scarring alopecic patches on the frontal and parietal scalp following the use of dupilumab.

How to cite this article: Koo HYR, Choi JY, Yu DS, Lee YB. Exacerbation of head and neck eczema with new-onset alopecia following dupilumab treatment in severe atopic dermatitis patients: A case series. *Indian J Dermatol Venereol Leprol*. doi: 10.25259/IJDVL_1018_2023

Received: September, 2023 **Accepted:** December, 2023 **Epub Ahead of Print:** April, 2024

DOI: 10.25259/IJDVL_1018_2023

This is an open-access article distributed under the terms of the Creative Commons Attribution-Non Commercial-Share Alike 4.0 License, which allows others to remix, tweak, and build upon the work non-commercially, as long as the author is credited and the new creations are licensed under the identical terms.

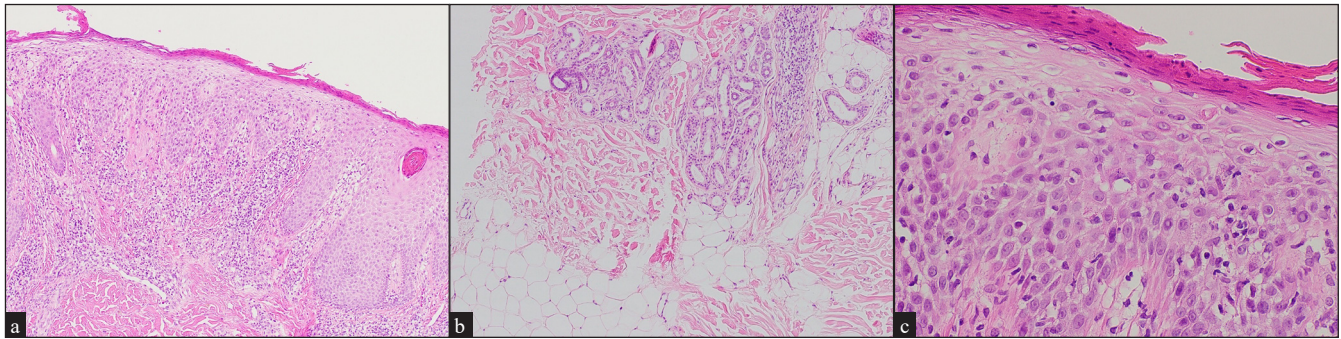


Figure 2a: Haematoxylin and eosin stained tissue sectioned showing parakeratosis, irregular acanthosis, and noticeable spongiosis with perivascular lymphocytic infiltration mainly in the papillary dermis, resembling subacute eczematous dermatitis. Note there is no terminal hair or increased catagen/telogen hairs. (a) 40x, (b) 100x and (c) 400x magnification.

Table 1: Characteristics and histopathological findings of cases of hair loss in patients on dupilumab.

Sources	Age/Sex	Site and morphology	Latency period (Weeks)	Histopathological findings
Flanagan, 2019 ²	27/M	Diffuse pink background erythema with ill-defined areas of non-scarring alopecia on the crown and temporal scalp	18	- AA-like hair miniaturisation with peribulbar chronic inflammation - Severe sebaceous gland atrophy
Barroso-García, 2018 ⁴	31/M	Patches of hair loss on the anterior scalp	6	- Deep, patchy perifollicular lymphocytic infiltrate and frequent fibrotic tracts - Focal epidermal inflammation with exocytosis, spongiosis and parakeratosis
Salgüero-Fernández, 2019 ⁵	33/M	Diffuse alopecia of the scalp, predominantly on the frontal and occipital areas, associated with erythema and scaling and areas of alopecia on the beard area	7	- Epidermal hyperplasia with interpapillary crest elongation - Marked spongiosis with lymphocyte exocytosis - Parakeratosis - Inflammatory infiltrate of lymphocytes and plasma cells in the papillary dermis - Perifollicular and peribulbar lymphoplasmacytic inflammatory infiltrate
Zhu, 2020 ⁶	31/M	Scalp, frontotemporal, localised non-scarring alopecic patch with perifollicular scale	40	- Hair miniaturisation and perifollicular lymphoplasmacytic infiltrate. - Sebaceous gland atrophy
Maiolini, 2021 ⁷	22/M	Scaling, erythematous alopecia plaque, with pruritus, on the vertex region, 5 cm in diameter, with erythema-eczema pattern on dermoscopy	20	- Psoriasisiform dermatitis with confluent parakeratosis, spongiosis, exocytosis of lymphocytes - Extravasated red blood cells.
Our case, 2023	25/M	Hair loss with erythema along the frontal hairline	8	- Parakeratosis, irregular acanthosis, and noticeable spongiosis with perivascular, lymphocytic infiltration mainly in the papillary dermis

clinical outcomes emphasise the importance of understanding the pathogenic mechanisms of hair loss related to Th2-associated pathways. Despite several studies reporting de novo AA arising after dupilumab treatment, only a few studies have performed histopathology examination, making a definitive diagnosis uncertain. As summarised in Table 1, histopathologic findings of previous reports have revealed various findings of hair loss that are consistent with various disease entities, including AA, eczema, or drug-induced hair loss.²⁻⁷ Given that the hair loss observed in our cases appeared 2 to 3 months after the initiation of dupilumab, there appears to be a temporal relationship between the two events. Clinically, our patients exhibited hair loss with aggravation of eczema in the head and neck regions. The histopathological examination of one case showed features resembling subacute eczematous dermatitis, rather than the classic AA findings of dense peribulbar lymphocytic infiltrates.

We present three cases of patients with new-onset hair loss while on dupilumab for AD. This suggests that hair loss following dupilumab treatment may be a manifestation of exacerbated head and neck eczema with acute hair loss. Since only a limited number of histopathological examination of biopsy specimens have been performed, it is imperative for dermatologists to be aware of these phenomena and conduct scalp biopsies to guide treatment.

Declaration of patient consent

The authors certify that they have obtained all appropriate patient consent.

Financial support and sponsorship

Nil.

Conflicts of interest

There are no conflicts of interest.

Use of artificial intelligence (AI)-assisted technology for manuscript preparation

The authors confirm that they have used artificial intelligence (AI)-assisted technology to assist in the writing or editing of the manuscript or image creations.

Ha Yeh Rin Koo, Jin Young Choi^{ID}, ***Dong Soo Yu,***
Young Bok Lee^{ID}

Department of Dermatology, Uijeongbu St. Mary's Hospital,
College of Medicine, The Catholic University of Korea, Cheon Bo-ro,
Uijeongbu, Korea

Corresponding author:

Dr. Young Bok Lee,
Department of Dermatology, Uijeongbu St. Mary's Hospital,
College of Medicine, The Catholic University of Korea, Cheon
Bo-ro, Uijeongbu, Korea.
lyb80@catholic.ac.kr

References

1. Guttman-Yassky E, Renert-Yuval Y, Bares J, Chima M, Hawkes JE, Gilleaudeau P, *et al.* Phase 2a randomized clinical trial of dupilumab (anti-IL-4R α) for alopecia areata patients. *Allergy* 2022;77:897–906.
2. Flanagan K, Sperling L, Lin J. Drug-induced alopecia after dupilumab therapy. *JAAD Case Rep* 2019;5:54–6.
3. Hendricks AJ, Lio PA, Shi VY. Dupilumab and alopecia: Causative or therapeutic? *Dermatol* 2019;235:306–7.
4. Barroso-García B, Rial M, Molina A, Sastre J. Alopecia areata in severe atopic dermatitis treated with dupilumab. *J Investig Allergol Clin Immunol* 2018;28:420–1.
5. Salgüero-Fernández I, Gonzalez de Domingo M, Suarez D, Roustan-Gullón G. Dermatitis and alopecia in a patient treated with dupilumab: A new adverse effect? *Clin Exp Dermatol* 2019;44:e41–e43.
6. Zhu G, Kang K, Chen J, Novoa R, Brown R, Chiou A, *et al.* Inflammatory alopecia in patients on dupilumab: A retrospective cohort study at an academic institution. *J Eur Acad Dermatol Venereol* 2020;34:e159–e161.
7. Maiolini VM, Sousa NA, Marsillac Pfd, Bressan AL. Alopecia areata-like and psoriasis after dupilumab use for atopic dermatitis. *An Bras Dermatol* 2021;96:634–6.