

# Treatment of pyogenic granuloma in children with copper vapor laser radiation (578 nm)

Sir,

Pyogenic granuloma presents as red or purple papules on the skin and mucous membranes.<sup>1</sup> Trauma, infection, hormonal changes and long-term use of angiogenic drugs (retinoids) are known causes of pyogenic granulomas. They can cause discomfort due to bleeding and functional disturbances in areas such as vermillion or palpebrae. In esthetically significant areas, it can pose a cosmetic problem as well. Pyogenic granulomas are characterized by dilated, distorted capillary-like vessels arranged in a lobular configuration, sometimes with a larger feeder vessel.<sup>2</sup> Pathogenetic treatment must lead to remodeling of the vascular bed and suppress vascular endothelial growth factor (VEGF) expression inside the pathological focus. Cryotherapy, cautery or excision of pyogenic granulomas can cause recurrences and scar formation.<sup>3</sup>

As per literature, laser treatment for pyogenic granulomas in adults provided favorable results without pronounced side effects. The ablative carbon dioxide laser showed fair results for the treatment of pyogenic granuloma. Nevertheless, sometimes it is associated with hyperpigmentation, scarring and relapses.<sup>4</sup> The use of the neodymium: YAG laser to treat pyogenic granuloma demonstrated high efficiency but was followed by scarring in 40% of patients.<sup>5</sup> Thermal damage resulting in apoptosis of the immature fibroblasts and collagens denaturation in the reticular layer of the dermis may be associated with deep penetration of the mid-infrared radiation. The lack of both reticular dermis fibroblasts and intact collagen may predispose to scarring.<sup>5</sup> Complete removal of pyogenic granuloma with pulsed dye laser at 595 nm in children required two to 15 treatment sessions.<sup>6</sup> It failed to eliminate thick pyogenic granuloma papules because of limited pulse energy and inadequate penetration depth [Table 1].<sup>7,8</sup>

The copper vapor laser radiation at 578 nm has been used to eliminate port-wine stains or telangiectasia consisting of dilated venous microvessels in the deeper dermal

layers.<sup>9</sup> There were no reports of use of the copper vapor laser for treatment of pyogenic granulomas. Nevertheless, copper vapor laser seems to be a good treatment option for treating pyogenic granuloma without side effects due to its capability to provide selective coagulation of the blood vessels in the upper dermis.<sup>9</sup> We report for the first time the successful use of copper vapor laser to treat pyogenic granuloma.

A total of seven patients (two boys and five girls) with Fitzpatrick skin type I - III, aged one–13 years old, with medium size pyogenic granulomas (up to eight millimeters), were treated at the Laser Department of the Health Institute (Kharkiv, Ukraine). The lesion was located on the face in four cases and on the lips in three cases [Figures 1-3]. The diagnosis was confirmed using dermoscopy [Figure 4a], which indicated the presence of lobular clusters of irregular capillary-sized vessels in the papillary dermis. Informed consent was obtained from parents of the children after discussing the risks and benefits of laser treatment.

The lesions were treated with copper vapor laser (Yakhroma-Med, Lebedev Physical Institute of the Russian Academy of Sciences). The copper vapor laser settings were as follows: average power of 0.7–1.0 W at yellow (578 nm) wavelength, the exposure time was 0.2–0.3 s with 1mm spot size. The treatment endpoint using a multiple stacking pass technique was assumed when the pyogenic granuloma acquired a grayish tint or blanching [Figure 1b and 4b]. In all cases, flattening of the elevated lesion was observed immediately during the treatment. No bleeding or erythema occurred after the laser procedure. The treatment was performed without anesthesia. After the procedure, the skin was treated with a 0.05% solution of chlorhexidine gluconate and bepanthene cream twice a day.

The irradiated skin healed with crust exfoliation in 7–12 days, with the complete epidermis restoration and skin color normalization [Figures 2b and 3b]. The pyogenic granuloma

**How to cite this article:** Ponomarev IV, Topchiy SB, Andrusenko YN, Shakina LD. Treatment of pyogenic granuloma in children with copper vapor laser radiation (578 nm). *Indian J Dermatol Venereol Leprol* 2021;87:856-8.

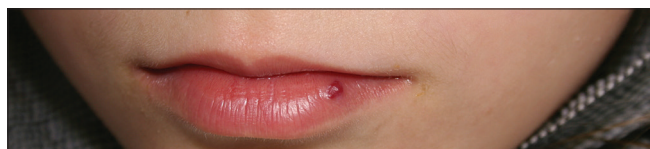**Received:** December, 2020 **Accepted:** May, 2021 **Epub Ahead of Print:** August, 2021 **Published:** October 2021

**DOI:** 10.25259/IJDVL\_5\_2020 **PMID:** 34491684

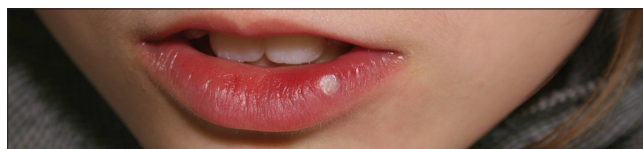This is an open-access article distributed under the terms of the Creative Commons Attribution-Non Commercial-Share Alike 4.0 License, which allows others to remix, tweak, and build upon the work non-commercially, as long as the author is credited and the new creations are licensed under the identical terms.

**Table 1: Comparison of different laser systems for pyogenic granuloma treatment**

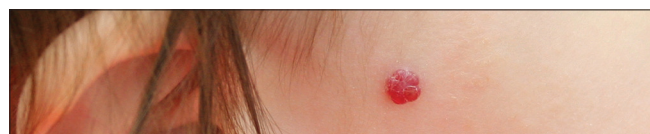Laser type	Number of treatments	Anesthesia	Side effects
Nd:YAG <sup>5</sup>	1–4	Yes	Recurrences 4% Scarring in 40% of cases
PDL <sup>6</sup>	2–15	No	Purpura
PDL <sup>7</sup>	1–6	No	Lack of response for large pyogenic granulomas (1 cm and 0.5 cm in diameter and elevated over 0.5 cm above the surface of the skin)
PDL <sup>8</sup>	Every four weeks until the lesion cleared	No	Hypopigmentation textural changes Hyperpigmentation
Copper vapor laser (this report)	Single	No	No



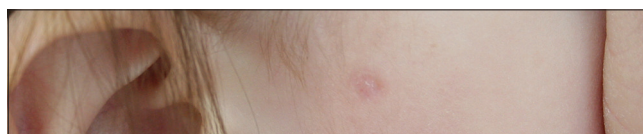**Figure 1a:** Pyogenic granuloma over the vermilion border in a girl, nine years old, before laser treatment



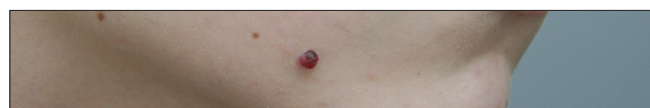**Figure 1b:** Blanching and shrinking of the pyogenic granuloma immediately after the copper vapor laser treatment. Copper vapor laser settings are average power – 0.8 W and exposure time – 0.2 s



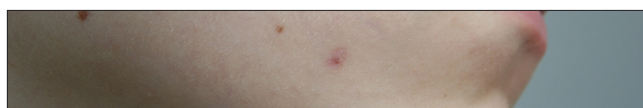
**Figure 2a:** Pyogenic granuloma on the right cheek in a 1.5-year girl, before laser treatment



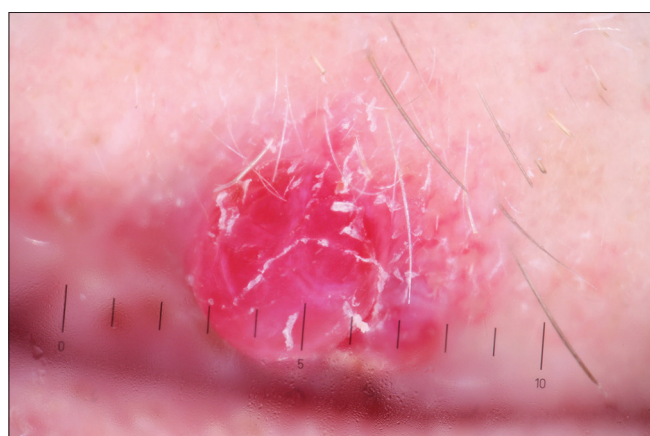**Figure 2b:** Two months after a single copper vapor laser treatment. Copper vapor laser settings are average power – 0.9 W and exposure time – 0.3 s



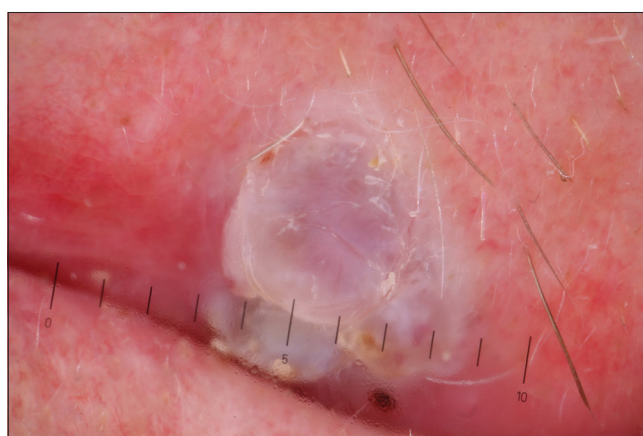**Figure 3a:** Pyogenic granuloma at the border between the right cheek and chin in a 13-year girl, before laser treatment



**Figure 3b:** Two months after a single copper vapor laser treatment. Copper vapor laser settings are average power – 0.9 W and exposure time – 0.3 s



**Figure 4a:** Dermoscopy of pyogenic granuloma: the focus is symmetrical, the boundaries are clear cut and the structure is homogeneous, lacunar, well-defined, rounded or oval red structures present



**Figure 4b:** After copper vapor laser treatment, the focus has changed dramatically and acquired a white-gray tint due to coagulated vessels and cavities

removal was complete in a single session. None of the patients showed any recurrence after being followed up for 24 months after the laser treatment.

Copper vapor laser radiation targets oxyhemoglobin and hemoglobin in the microvascular bed of the pyogenic granuloma. The high absorption of copper vapor laser

radiation by blood provided complete removal of pyogenic granuloma by the appropriate vascular obliteration.<sup>9</sup> Due to the high absorption by blood, copper vapor laser radiation neither passes into the deep dermis nor overheats dermal stem cells. This is essential for appropriate skin healing after laser exposure and thus prevents relapses. The copper vapor laser works well for pyogenic granuloma treatment because it provides the relevant volume coagulation and selective heating of the feeder vessel.<sup>9</sup>

Our study demonstrates the efficacy of the copper vapor laser to provide complete pyogenic granuloma resolution with good cosmetic results, in the absence of pronounced side effects. The reliable hemostatic effect of copper vapor laser is essential for a safe procedure for pyogenic granuloma treatment in pediatric patients. Copper vapor laser treatment does not require anesthesia and takes a few minutes and can be performed in the outpatient department.

The study's limitations are associated with the lack of comparative assessment of the different laser treatment modes. More studies are required to determine the optimal copper vapor laser settings for patients with different skin phototypes.

#### Declaration of patient consent

The authors certify that they have obtained all appropriate patient consent.

#### Financial support and sponsorship

Nil.

#### Conflicts of interest

There are no conflicts of interest.

**Igor V. Ponomarev, Sergey B. Topchiy, Yury N. Andrusenko<sup>1</sup>, Lyudmila D. Shakina<sup>2</sup>**

Department of Quantum Radiophysics, P. N. Lebedev Physical Institute of the Russian Academy of Sciences, Moscow, Russia, <sup>1</sup>Department of the Health Institute, Clinic of Aesthetic Medicine, Kharkiv, Ukraine, <sup>2</sup>Department of Methodical, National Medical Research Center of Children Health, Moscow, Russia

#### Corresponding author:

Dr. Igor V. Ponomarev,  
Head of Laser Project, 53, Leninskiy Prospect,  
Moscow, 119991, Russian Federation.  
luklalukla@ya.ru

#### References

1. Sarwal P, Lapumnuaypol K. Pyogenic granuloma. In: Stat Pearls. Treasure Island, FL: Stat Pearls Publishing; 2020.
2. Oak SN, Viswanath N. Management of hemangiomas in children. *Indian J Dermatol Venereol Leprol* 2006;72:1-4.
3. Pagliai KA, Cohen BA. Pyogenic granuloma in children. *Pediatr Dermatol* 2004;21:10-3.
4. Wheeland RG, Ashley JR, Smith DA, Ellis DL, Wheeland DN. Carbon dioxide laser treatment of granuloma faciale. *J Dermatol Surg Oncol* 1984;10:730-3.
5. Philipp C, Almohamad A, Adam M, Becker-Köhnlein J, Berlien H, Müller U, *et al.* Pyogenic granuloma-Nd: YAG laser treatment in 450 patients. *Photonics Lasers Med* 2015;4:215-26.
6. Kishi Y, Kikuchi K, Hasegawa M, Ohgushi K, Igarashi A, Hatanaka M, *et al.* Dye laser treatment for hemorrhagic vascular lesions. *Laser Ther* 2018;27:61-4.
7. Tay YK, Weston WL, Morelli JG. Treatment of pyogenic granuloma in children with the flashlamp-pumped pulsed dye laser. *Pediatrics* 1997;99:368-70.
8. Kono T, Sakurai H, Groff WF, Chan HH, Takeuchi M, Yamaki T, *et al.* Comparison study of a traditional pulsed dye laser versus a long-pulsed dye laser in the treatment of early childhood hemangiomas. *Lasers Surg Med* 2006;38:112-5.
9. Klyuchareva SV, Ponomarev IV, Pushkareva AE. Numerical modeling and clinical evaluation of pulsed dye laser and copper vapor laser in skin vascular lesions treatment. *J Lasers Med Sci* 2019;10:44-9.

## Pinch-punch technique for scrotal calcinosis cutis

Sir,  
Scrotal calcinosis cutis is a benign condition which usually occurs at a young age or in early adulthood.<sup>1</sup> The condition manifests as solitary or multiple, asymptomatic calcified nodules or papules on the scrotum. It may be associated with pruritus, feeling of heavy sensation, discharge of white chalky material, secondary bacterial infection or a combination of all these features. The term idiopathic scrotal calcinosis is used in the absence

of any systemic disorder of the calcium/phosphorus metabolism.<sup>1</sup> Treatment of scrotal calcinosis is intended to address the associated symptoms as well as to preserve cosmesis. Surgery is the usual mode of treatment in scrotal calcinosis. Various surgical methods practiced for the condition include enucleation, wide local excision with direct closure and complex scrotal reconstruction.<sup>2</sup> Pinch-punch technique has been described as a novel method for removal of calcinosis cutis in patients with fewer and

**How to cite this article:** Rout AN, Pradhan S, Sirka CS. Pinch-punch technique for scrotal calcinosis cutis. *Indian J Dermatol Venereol Leprol* 2021;87:858-60.

**Received:** March, 2021 **Accepted:** June, 2021 **Epub Ahead of Print:** August, 2021 **Published:** October 2021

**DOI:** 10.25259/IJDVL\_274\_2021 **PMID:** 34491687

This is an open-access article distributed under the terms of the Creative Commons Attribution-Non Commercial-Share Alike 4.0 License, which allows others to remix, tweak, and build upon the work non-commercially, as long as the author is credited and the new creations are licensed under the identical terms.