

Pustular lesions in the neonate: Focused diagnostic approach based on clinical clues

TP Afra, Manju Daroach¹, Rahul Mahajan¹, Dipankar De¹, Sanjeev Handa¹

Department of Dermatology, IQRAA International Hospital & Research Centre, Kozhikode, Kerala, ¹Department of Dermatology, Venereology and Leprology, Postgraduate Institute of Medical Education & Research, Chandigarh, India.

Abstract

Pustules in a neonate can be due to various causes. Though the majority of conditions causing pustules in a neonate are benign, it is essential to clearly differentiate these from serious ones. A systematic approach based on detailed history and clinical examination of the neonate along with basic laboratory evaluation narrows down diagnostic possibilities and aids in the correct diagnosis. This review outlines a step-by-step approach so as to avoid clinical dilemmas and unnecessary intervention.

Key words: Pustules, neonate, diagnosis, benign, infectious

Introduction

The first four weeks of extrauterine life constitute the neonatal period. Neonates may develop pustules due to innocuous causes or serious reasons. The presence of pustules in a newborn can cause apprehension in the parents and the neonatologists leading to extensive investigations to find the etiology.

The diagnostic approach to pustular lesions in a neonate should be focused as relevant to the clinical presentation. Meticulous clinical evaluation supported by simple bedside laboratory tests can narrow diagnostic possibilities and help differentiate between the benign and more sinister possibilities. This review is aimed at outlining a diagnostic approach to pustular lesions in the neonate based on clinical findings and basic laboratory evaluation [Figures 1a and b]. While this approach encompasses the more common etiologies manifesting as pustules in the neonatal period, the list herein (Table 1) is not exhaustive and we do not attempt to detail the clinical and epidemiologic characteristics of each dermatosis individually.

Epidemiology and etiology

There is a relative scarcity of large epidemiologic studies on pustular eruptions in neonates. In a study from India involving

100 neonates with pustular eruptions, 36 (36%) were in the early neonatal period (first week of life). The majority of these were of infectious etiology (58%) and among families of poor socioeconomic status (96%).¹ In another study by Goyal *et al.* 18 (41%) of neonates were diagnosed with erythema toxicum neonatorum, four (9%) each with miliaria crystallina and staphylococcal pyoderma, three (6.8%) with neonatal acne, two (4.5%) each with group A streptococcal impetigo, sucking blisters and neonatal tinea faciei and one (2.3%) each with neonatal candidiasis, neonatal varicella, scabies, transient neonatal pustular melanosis, epidermolysis bullosa simplex, incontinentia pigmenti, eosinophilic pustular folliculitis, pemphigus vulgaris and neonatal herpes simplex.² Erythema toxicum neonatorum is the commonest neonatal pustular dermatosis, seen in 16–30% of newborns.³ Impetigo is the most common primary skin infection in neonates that presents with pustules.

Pustular lesions in neonates can be categorized based on etiology as: (1) benign self-limiting dermatoses, (2) infections, (3) inflammatory dermatoses, (4) neoplastic disorders, (5) primary immunodeficiency disorders and (6) miscellaneous disorders [Table 1].⁴⁻⁹

How to cite this article: Afra T, Daroach M, Mahajan R, De D, Handa S. Pustular lesions in the neonate: Focused diagnostic approach based on clinical clues. *Indian J Dermatol Venereol Leprol* 2022;88:708-16.

Corresponding author: Dr. Rahul Mahajan, Department of Dermatology, Venereology and Leprology, Postgraduate Institute of Medical Education & Research, Chandigarh, India. drmahulpgi@yahoo.com

Received: February, 2021 **Accepted:** April, 2022 **Epub Ahead of Print:** August, 2022 **Published:** November, 2022

DOI: 10.25259/IJDVL_209_2021 **PMID:** 36332088

This is an open-access article distributed under the terms of the Creative Commons Attribution-Non Commercial-Share Alike 4.0 License, which allows others to remix, transform, and build upon the work non-commercially, as long as the author is credited and the new creations are licensed under the identical terms.

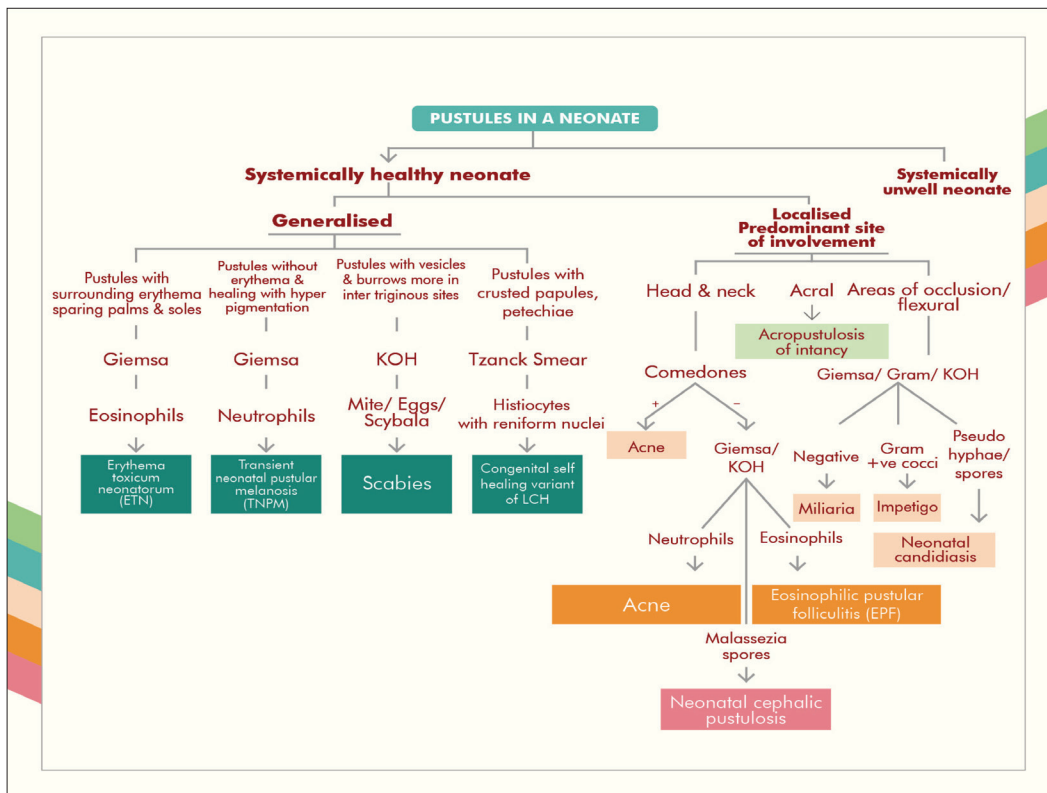


Figure 1a: Flowchart of the diagnostic approach to a systemically healthy neonate presenting with pustules

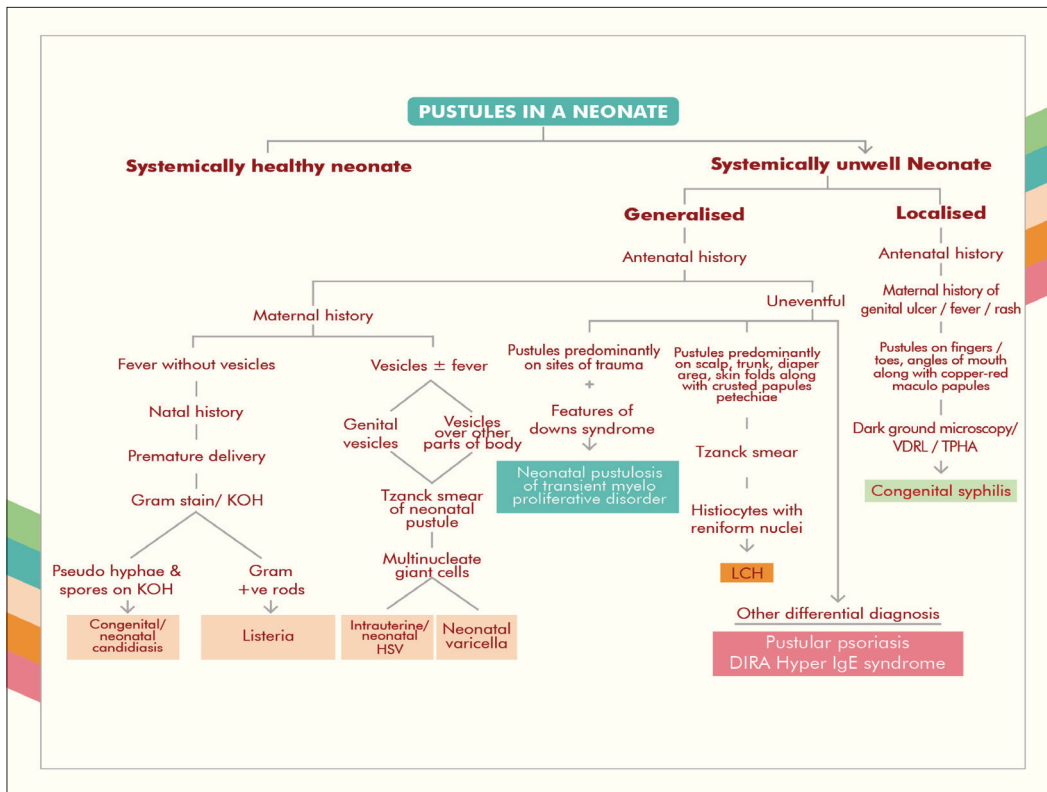


Figure 1b: Flowchart of the diagnostic approach to a systemically unwell neonate presenting with pustules

Table 1: Classification of pustular lesions in neonates based on etiology

Category	Etiology
Benign self-limiting dermatoses⁵	<p>Common causes</p> <p>Erythema toxicum neonatorum Transient neonatal pustular melanosis¹⁰ Miliaria/heat rash Neonatal cephalic pustulosis Neonatal acne</p> <p>Uncommon causes</p> <p>Acropustulosis of infancy Eosinophilic pustular folliculitis</p>
Infections	<p>Bacterial</p> <p>Impetigo Congenital syphilis Listeria monocytogenes infection Pseudomonas aeruginosa infection Hemophilus influenzae infection</p> <p>Viral</p> <p>Herpes simplex virus infection (intrauterine, neonatal) Varicella (foetal varicella syndrome/congenital varicella/varicella embryopathy, neonatal varicella, neonatal herpes zoster)</p> <p>Fungal</p> <p>Candidiasis (congenital, neonatal) Dermatophytosis Aspergillosis</p> <p>Parasitic</p> <p>Scabies</p>
Associated with neoplasm	<p>Neonatal pustulosis of transient myeloproliferative disorder Langerhans cell histiocytosis (congenital Langerhans cell histiocytosis, Hashimoto–Pritzker disease or congenital self-healing reticulohistiocytosis)</p>
Inflammatory dermatosis	<p>Pustular psoriasis</p>
Primary immunodeficiency disorders	<p>Hyper-IgE syndrome/Job syndrome Deficiency of interleukin-1 receptor antagonist</p>
Miscellaneous	<p>Incontinentia pigmenti Autoimmune blistering diseases (neonatal pemphigus, gestational pemphigoid, pemphigus foliaceus)</p>

Approach

The initial evaluation of neonatal pustules includes the history of onset and course of the pustules, general physical examination, cutaneous examination and basic laboratory evaluation. The clinician should identify whether the cutaneous pustules are a manifestation of a systemic disease or a disease limited to the skin. The general condition of the neonate can provide insight into this. The distribution of pustules further aids the diagnosis. The causes of generalised or localized pustules in a term healthy neonate who is accepting feeds normally are mostly benign eruptions or cutaneous infections. In such a scenario, the benign neonatal pustuloses possible include erythema toxicum neonatorum, transient neonatal pustular melanosis, miliaria/heat rash, neonatal cephalic pustulosis, neonatal acne and the less common acropustulosis of infancy or eosinophilic pustular folliculitis.¹⁰ These conditions are usually transient, self-limiting and asymptomatic in a neonate. Certain cutaneous infections like impetigo, neonatal candidiasis and scabies can also present as pustules in an otherwise well child. The distribution and morphology of the pustules as well as simple laboratory tests (including Giemsa stain, Gram stain and potassium hydroxide study) on the contents of pustule establishes the diagnosis in most cases.

Along with the clues obtained during the initial evaluation a more detailed history including antenatal and natal history is to be undertaken if the condition remains undiagnosed after the first step. During this stage, a thorough cutaneous examination with systemic examination should be carried out in consultation with paediatrician and more specific laboratory tests can be ordered based on the history and examination findings. Pustules in a neonate who is premature, unwell, has difficulty feeding, maternal history of fever, rash, vesicles, vaginal candidiasis, intrauterine devices, cervical sutures, premature rupture of membranes or chorioamnionitis can be a marker of more serious systemic disease. These findings should lead to a focused evaluation for the diagnosis of systemic infections, certain inflammatory dermatoses, neoplasms, primary immunodeficiency disorders and other rare disorders.

Maternal and family history

In general, maternal history and family history are noncontributory in the scenario of cutaneous pustules in an otherwise well neonate except in a few conditions.

A history of itching, dermatophytosis or scabies in the mother or a close family member may point to a diagnosis of the same condition in the neonate.^{11,12} Though a rare cause of

neonatal pustules, maternal pemphigus vulgaris can lead to neonatal pemphigus, which has an excellent prognosis.¹³

History of vesicles in the mother in the genital area during pregnancy points towards neonatal herpes simplex infection. The presence of vesicles or pustules during the last three weeks of pregnancy, especially between five days before and two days after delivery is a strong indication of neonatal varicella.^{14,15} If there is any suspicion of congenital syphilis, the clinician should seek the history suggestive of primary chancre or secondary syphilis in the mother and history of exposure in mother.¹⁶ History of vaginal candidiasis, intrauterine devices, cervical sutures, premature rupture of membranes or chorioamnionitis in the mother indicate risk factors for candidiasis in the neonate.^{17,18}

The family history and pedigree chart analysis help in the diagnosis of primary immunodeficiency disorders such as Job syndrome (autosomal dominant hyper-IgE syndrome) and deficiency of the interleukin-1-receptor antagonist (autosomal recessive) as well as incontinentia pigmenti (X-linked dominant; mother may be asymptomatic or have mosaic hypopigmented streaks on skin).^{8,9,19}

Birth history

Erythema toxicum neonatorum is common in full term healthy male neonates with no gestational risk factors.¹⁰ Among infectious causes, neonates who have acquired the disease during their intrauterine life are usually premature and of low birth weight as in intrauterine herpes simplex virus infection and listeria infection.^{20,21} Premature and low

birth weight infants are also at risk of developing systemic spread of cutaneous infection as in candidiasis.⁴

Age at onset

Although the timing of onset of the pustular eruption is not a very specific clue, a few clinical entities may manifest more frequently in early neonatal life (first week of life) [Figure 2]. Among the benign causes, transient neonatal pustular melanosis tends to present at birth in newborns with pigmented skin whereas erythema toxicum neonatorum begins after 24–48 hours from delivery in a full-term neonate with a waxing and waning course and completely resolves in a week.^{22,23} Of the infectious causes, those acquired during intrauterine life present at birth itself (intrauterine herpes simplex virus infection, congenital candidiasis, congenital syphilis)^{14,16,24} whereas those acquired close to the time of birth (neonatal herpes simplex virus infection, neonatal varicella, neonatal candidiasis)^{14,15} or in the immediate postpartum period (impetigo) present a few days to two or three weeks after birth.⁶

Morphology and distribution

In most conditions, the pustules evolve from macules, papules or vesicles. The morphology and pattern of distribution of the eruption (pustules along with other skin lesions) are important in diagnosis. It should be noted if the pustules are generalised or localized. Generalised pustules in a healthy neonate are seen in erythema toxicum neonatorum, transient neonatal pustular melanosis, scabies and rarely the congenital self-healing variant of Langerhans cell histiocytosis. In these conditions, along with the morphology and distribution of

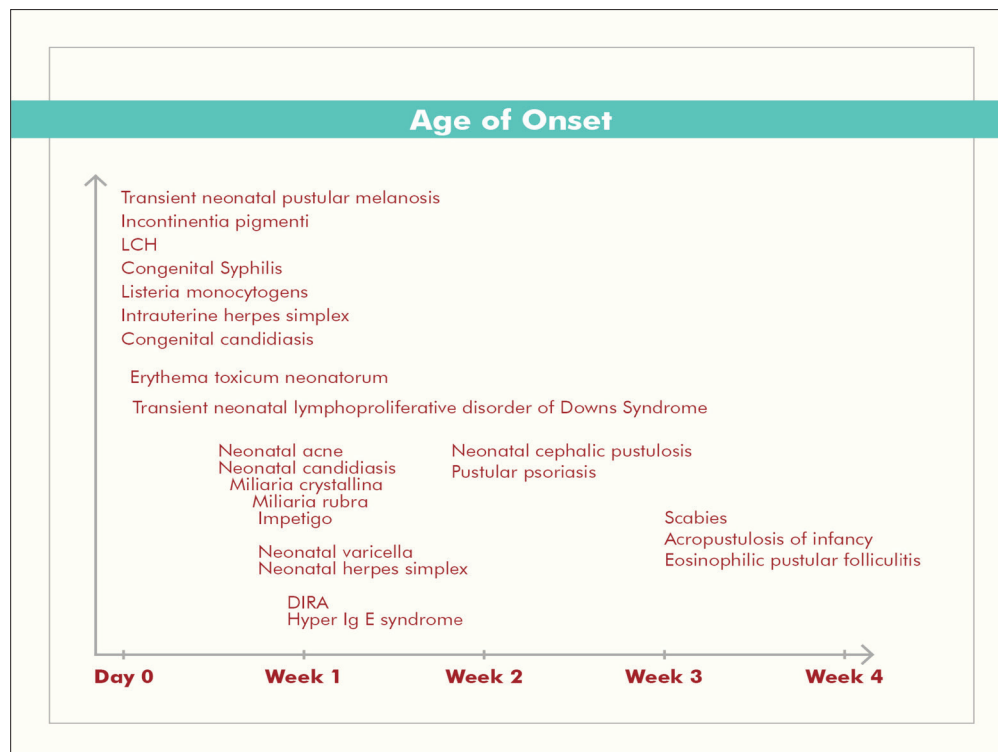


Figure 2: Diagrammatic representation of the age of onset of pustular lesions in the neonate

the pustules, other associated lesions come into the picture. In erythema toxicum neonatorum, transient erythematous macules, wheals, vesicles, pustules and papules in varying combinations are seen all over the body except on the palms and soles, where pilosebaceous units are absent [Figure 3].⁵ This eruption starts on the face and then involves the proximal extremities, trunk and buttocks. The pustules in transient neonatal pustular melanosis lack surrounding erythema and they rupture leaving a collarette of scale; palms and soles may be affected. The hyperpigmented macules left behind on clearing of the pustules may last longer.²³ In contrast to older children, scabies in neonates presents with vesicles and pustules along with its other classical lesions such as erythematous papules, nodules, and burrows. In neonates, the presentation is usually generalised involving the palms, soles, head and neck with lesions more concentrated on the wrists, axillae, periumbilical region, medial feet and groins [Figure 4]. Eczematisation and secondary infection can also supervene. In severe infestation, the neonate may be irritable with poor feeding and inadequate weight gain.¹² Congenital self-healing Langerhans cell histiocytosis presents as red-brown macules, papules and nodules which can be solitary or generalized all over the body. Varied presentations with vesicles, pustules and blueberry muffin lesions can also be seen. Though the disease is limited to the skin, a thorough evaluation to rule out systemic involvement is needed.²⁵

When the pustules are localised, some differentials can be arrived at based on the predominant area of involvement. The differential diagnosis when papulopustules are located in the head and neck region are neonatal acne, neonatal cephalic pustulosis and eosinophilic pustular folliculitis. Erythematous papulopustules on the face are seen in neonatal acne and neonatal cephalic pustulosis [Figure 5]. In newborns with neonatal acne, facial pustules are accompanied by comedones in 23–30% of cases.^{26,27} In eosinophilic pustular folliculitis, recurrent crops of esiculopustules occur on the face and scalp and may be associated with hemorrhagic crusts.^{6,28} If comedones are not seen, microscopy with Giemsa stain or a potassium hydroxide smear may aid diagnosis. A closely related condition, acropustulosis of infancy presents similar to eosinophilic pustular folliculitis, but the sites of predilection are the hands and feet.²⁸

Localised pustules are also seen in miliaria, impetigo and neonatal candidiasis. In miliaria, sites of predilection are occluded areas like the neck and back. In miliaria crystallina, clear tiny vesicles are seen over healthy skin. Multiple erythematous papules or papulovesicles on an erythematous background are seen in miliaria rubra. The contents may become pustular due to deeper obstruction (miliaria pustulosa) or due to secondary infection (periporitis).⁵ Bullous impetigo is common over the perineum, periumbilical area and neck creases and manifests as rapidly enlarging thin walled flaccid bullae with a narrow rim of erythema. The bullae rupture easily to form moist erosions with a collarette of scales at

the edge. In nonbullous impetigo, the vesicle or pustule is transient and forms honey-coloured crusted plaques with surrounding erythema.²⁹ It may be emphasized that while the majority of neonates with impetigo will have mild limited disease, it is important to look for any systemic signs and symptoms, lymphadenopathy, and general condition as it may spread very quickly to involve larger areas of the body or evolve into staphylococcal scalded skin syndrome.³⁰ Beefy red erythematous moist plaques with a scalloped outline and satellite pustules in the napkin area are seen in neonatal candidiasis which is a common cause of neonatal pustules. It

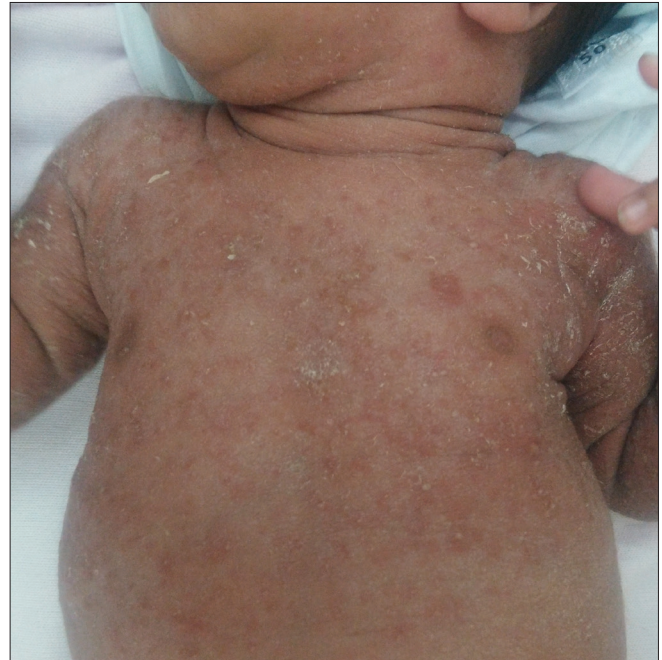

Figure 3: Pustules over trunk surrounded by erythematous halos, suggestive of erythema toxicum neonatorum

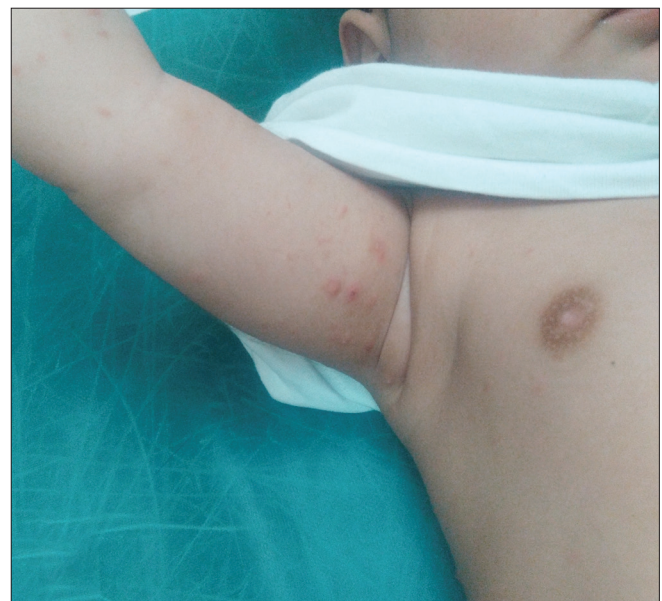

Figure 4: Pustules over axilla in a neonate with scabies

starts from the perianal area and spreads peripherally. It may be associated with oral thrush and localized palmar pustules as a result of inoculation of *Candida* from the mouth into the skin due to sucking.⁶

Pustules in a neonate due to an underlying systemic disease are mostly generalised. In congenital candidiasis (intrauterine infection) there is extensive involvement of the body with palms, soles and nails characteristically involved. The oral cavity and diaper region are usually spared here, in contrast to neonatal candidiasis (where the neonate acquires the infection during its passage through the infected birth tract). Disseminated involvement in neonatal candidiasis can however be seen in premature and low birth weight infants.^{6,31}

Even though the features of herpes simplex virus infection (intrauterine and neonatal) and varicella (fetal varicella syndrome, neonatal varicella and neonatal herpes zoster) overlap, there are certain subtle cutaneous features that help to differentiate these conditions. Vesicles evolving into pustules and crusts are present in all these situations, though rare in fetal varicella syndrome. Vesicles are less extensive in neonatal herpes simplex virus infection than in neonatal varicella and lack the classical grouping.⁶ Cutaneous scars and aplasia cutis are characteristic features of intrauterine infections

(herpes simplex virus and varicella), the dermatomal pattern being more specific for varicella.^{14,15} Involvement of oral or conjunctival mucosa favours the diagnosis of herpes simplex.¹⁴

In transient myeloproliferative disorder associated with Down syndrome, vesiculopustular eruptions are seen predominantly on the face but may also involve the trunk and extremities and resolve spontaneously within weeks to months. Lesions also develop at sites of minor trauma or adhesive dressings.³² Crusted papules and pustules along with nodules, petechiae, fissures and oozy lesions over the scalp, diaper area and skin folds are indicators of congenital Langerhans cell histiocytosis [Figure 6].^{33,34} Pustular psoriasis in neonates may present as napkin psoriasis with dissemination, generalised pustular psoriasis of von Zumbusch type or annular or circinate forms.^{7,35,36} Deficiency of the interleukin-1-receptor antagonist also presents similarly with generalised pustules. Onychomadesis can also be seen.⁹ In the hyper-IgE syndrome, papulopustules are distributed predominantly on the scalp and face along with other sites like the neck, axillae and napkin area. Eczematous lesions and cold abscesses are also seen though more common after the neonatal period.⁸

Pustules on the fingers, toes and at the angles of the mouth along with the typical copper-red maculopapules, vesiculobullous lesions or condyloma lata will clinch the diagnosis of early

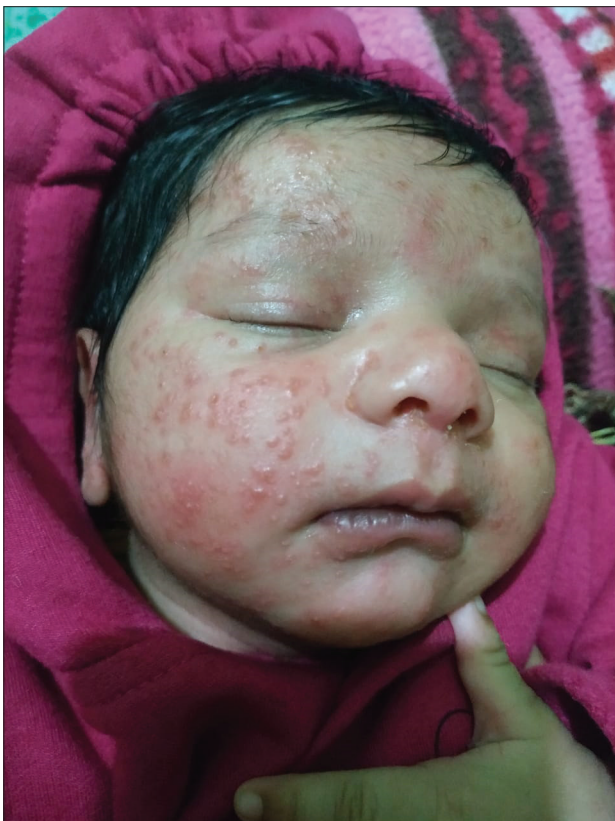

Figure 5: Erythematous papulopustules over face and scalp without comedones in benign cephalic pustulosis

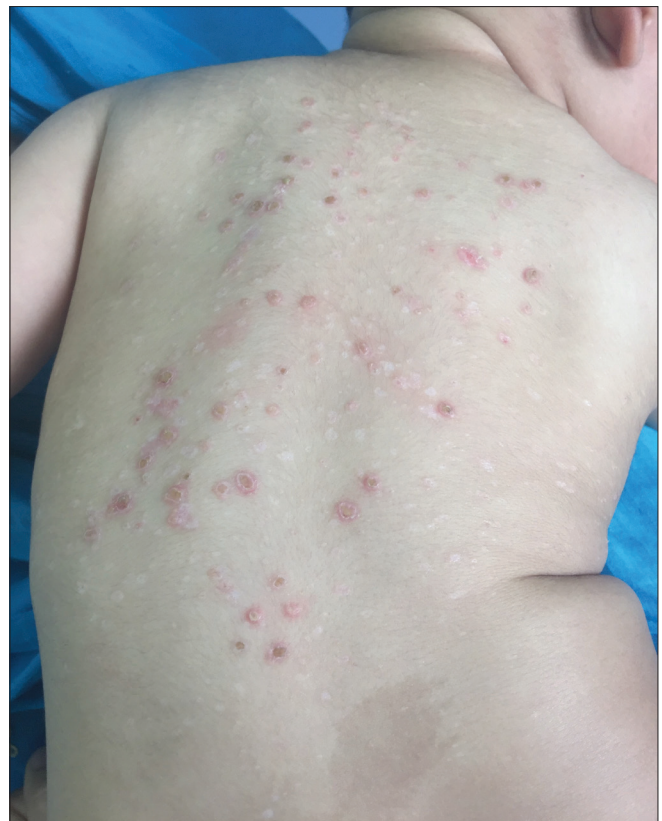

Figure 6: Crusted papules and pustules on the back in congenital Langerhans cell histiocytosis

congenital syphilis in the neonate.¹⁶ Vesicles and pustules in a linear and whorled distribution corresponding to Blaschko's lines in a female neonate are a clear indicator of incontinentia pigmenti [Figure 7].¹⁹

Systemic features

Systemic involvement is absent in the benign self-limiting dermatoses.¹⁰ The presence of systemic features is a sign to consider more serious causes in the differential diagnosis [Table 2].

Basic laboratory evaluation

Basic laboratory tests include microscopic examination of the contents of the vesiculopustule using Gram stain, Giemsa stain/ Tzanck smear and potassium hydroxide mounts. The findings of these tests taken with the clinical setting can confirm the diagnosis in most cases of pustules in neonates [Table 3].

Further diagnostic evaluation

Based on the initial findings, the clinician can consider more specific laboratory tests to confirm the diagnosis [Table 4].

Table 2: Systemic involvement in a neonate with pustules

Systemic features	Diagnosis to be considered
None	Benign self-limiting dermatosis ⁵
Hepatosplenomegaly, pseudoparalysis, respiratory distress	Congenital syphilis ¹⁶
Microcephaly, chorioretinitis	Intrauterine herpes simplex virus infection ¹⁴
Central nervous system involvement, hepatitis, lethargy, poor feeding	Neonatal herpes simplex virus infection ¹⁴
Dermatomal scarring, aplasia cutis, neurologic defects, eye disease, skeletal anomalies	Congenital varicella syndrome ¹⁵
Pneumonia, hepatitis.	Neonatal varicella ¹⁵
Fever, respiratory distress, sepsis, deranged liver function tests	Systemic candidiasis ³⁷
Features of Down syndrome, hepatosplenomegaly, high white cell count and presence of blasts	Neonatal pustulosis of transient myeloproliferative disorder ³²
Bone pain, lymph node enlargement, hepatosplenomegaly, respiratory failure, poor appetite, irritability	Langerhans cell histiocytosis ²⁵
Recurrent pneumonia with pneumatocele, osteopenia, retention of deciduous teeth, recurrent bacterial and fungal infections	Job syndrome ⁸
Multifocal aseptic osteomyelitis, periostitis	Deficiency of IL 1 receptor antagonist (DIRA) ⁹
Central nervous, ophthalmic and dental anomalies	Incontinentia pigmenti ¹⁹

Table 3: Basic laboratory evaluation in a neonate with pustules

Investigation	Findings	Diagnosis
Giemsa stain	Eosinophils	Erythema toxicum neonatorum ²² Eosinophilic pustular folliculitis ⁵
	Neutrophils	Transient neonatal pustular melanosis ⁵ Acropustulosis of infancy ⁵
	Lymphocytes	Miliaria ⁵
Gram stain	Fungal spores	Neonatal cephalic pustulosis ³⁸
	Neutrophils and gram-positive cocci in clusters (<i>Staphylococcus aureus</i>) and in chains (<i>Streptococcus</i>)	Impetigo ⁶
Potassium hydroxide (KOH) preparation	Pseudohyphae and spores	Candidiasis ³¹
	Hyphae	Dermatophytosis ^{4,11}
	Mites, eggs and scybala	Scabies ^{4,12}
Tzanck smear	Multinucleate giant cells	Viral infections (both herpes simplex virus and varicella) ⁶
	Acantholytic cells	Neonatal pemphigus ³⁹
	Histiocytes with reniform nuclei and abundant cytoplasm	Langerhans cell histiocytosis ⁴⁰
	Blast cells	Neonatal pustulosis of transient myeloproliferative disorder ⁴¹
Dark field microscopy	Treponemes	Congenital syphilis ¹⁶

Table 4: Detailed laboratory evaluation in a neonate with pustules

Suspected diagnosis	Diagnostic evaluation
Impetigo	Culture of pustular contents ⁶
Congenital syphilis	Serology, complete hemogram with differential count, liver function tests, X-rays of the chest and joints, CSF analysis, auditory, ophthalmologic and neurologic evaluation ¹⁶
Herpes simplex virus and varicella	Maternal type-specific serology (HSV), viral specific staining techniques, PCR and cultures ¹⁴
Candidiasis	Culture of pustular contents, blood, urine, cerebrospinal fluid (if dissemination/systemic infection suspected), liver function tests ⁴²
Neonatal pustulosis of transient myeloproliferative disorder.	Skin biopsy, full blood count, peripheral smear ³²
Langerhans cell histiocytosis	Skin biopsy, full blood counts, serum electrolytes, renal function tests, liver function tests, coagulation studies, ESR, C-reactive protein, skeletal survey, bone marrow studies, chest X-ray, MRI of the brain, HRCT of the chest, abdominal ultrasound, liver biopsy (as indicated) ²⁵
Pustular psoriasis	Skin biopsy, full blood counts, ESR and C-reactive protein ³⁶
Job syndrome	Serum IgE, full blood counts, systemic evaluation as indicated ⁸
Deficiency of IL-1 receptor antagonist (DIRA)	Skin biopsy, full blood counts and acute-phase reactants ⁹

HSV: Herpes simplex virus, PCR: Polymerase chain reaction, ESR: Erythrocyte sedimentation rate, MRI: Magnetic resonance imaging, HRCT: High resolution computed tomography

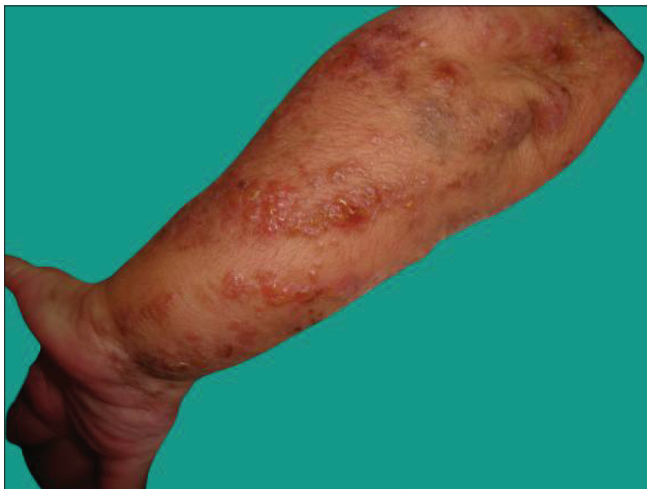

Figure 7: Vesicles and pustules along Blaschko's lines in a female neonate with incontinentia pigmenti

Conclusion

Even though there are numerous causes for pustules in a neonate, these are benign in a large proportion and resolve without much intervention and without any complications. Most of the common causes can be diagnosed during the initial clinical evaluation. Extensive laboratory evaluation may be needed

if the clinical presentation is suggestive of a more serious or systemic disease presenting as pustules in the neonatal period and can be managed accordingly. Overenthusiastic labeling of a benign condition as serious can lead to unnecessary parental distress and iatrogenic complications, and should be avoided.

Acknowledgement: We thank the parents of the patients for granting permission for clinical photography. We also thank Mr. Sansin Dulkifl, Bachelor of Multimedia Communication for the technical assistance in flow chart preparation and Dr. Vinay Keshavmurthy for providing Figure 6.

Declaration of patient consent

The authors certify that they have obtained all appropriate patient consent.

Financial support and sponsorship

Nil.

Conflicts of interest

There are no conflicts of interest.

References

- Nanda S, Reddy BS, Ramji S, Pandhi D. Analytical study of pustular eruptions in neonates. *Pediatr Dermatol* 2002;19:210–5.
- Goyal T, Varshney A, Bakshi SK. Incidence of vesicobullous and erosive disorders of neonates: Where and how much to worry?. *Indian J Pediatr* 2021;88:574–8.
- Monteagudo B, Labandeira J, Cabanillas M, Acevedo A, Toribio J. Prospective study of erythema toxicum neonatorum: Epidemiology and predisposing factors. *Pediatr Dermatol* 2012;29:166–8.
- Hussain S, Venepally M, Treat JR. Vesicles and pustules in the neonate. *Semin Perinatol* 2013;37:8–15.
- Reginatto FP, Villa DD, Cestari TF. Benign skin disease with pustules in the newborn. *An Bras Dermatol* 2016;91:124–34.
- Van Praag MC, Van Rooij RW, Folkers E, Spritzer R, Menke HE, Oranje AP. Diagnosis and treatment of pustular disorders in the neonate. *Pediatr Dermatol* 1997;14:131–43.
- Oliveira ST, Maragno L, Arnone M, Takahashi MD, Romiti R. Generalized pustular psoriasis in childhood. *Pediatr Dermatol* 2010;27:349–54.
- Chamlin SL, McCalmont TH, Cunningham BB, Esterly NB, Lai CH, Mallory SB, et al. Cutaneous manifestations of hyper-IgE syndrome in infants and children. *J Pediatr* 2002;141:572–5.
- Jesus AA, Goldbach-Mansky R. Monogenic autoinflammatory diseases: Concept and clinical manifestations. *Clin Immunol* 2013;147:155–74.
- Reginatto FP, Muller FM, Peruzzo J, Cestari TF. Epidemiology and predisposing factors for erythema toxicum neonatorum and transient neonatal pustular: A multicenter study. *Pediatr Dermatol* 2017;34:422–6.
- Warren LJ, Tilakaratne D, Seth R. Neonatal tinea corporis. *Med J Aust* 2017;207:324.
- Hill TA, Cohen B. Scabies in babies. *Pediatr Dermatol* 2017;34:690–4.
- Zhao CY, Chiang YZ, Murrell DF. Neonatal autoimmune blistering disease: A systematic review. *Pediatr Dermatol* 2016;33:367–74.
- James SH, Kimberlin DW. Neonatal herpes simplex virus infection: Epidemiology and treatment. *Clin Perinatol* 2015;42:47–59.
- Sauerbrei A, Wutzler P. Neonatal varicella. *J Perinatol* 2001;21:545–9.
- Parish JL. Treponemal infections in the pediatric population. *Clin Dermatol* 2000;18:687–700.
- Bruner JP, Elliott JP, Kilbride HW, Garite TJ, Knox GE. Candida chorioamnionitis diagnosed by amniocentesis with subsequent fetal infection. *Am J Perinatol* 1986;3:213–8.

18. Cosgrove BF, Reeves K, Mullins D, Ford MJ, Ramos-Caro FA. Congenital cutaneous candidiasis associated with respiratory distress and elevation of liver function tests: A case report and review of the literature. *J Am Acad Dermatol* 1997;37:817–23.
19. Swinney CC, Han DP, Karth PA. Incontinenti pigmenti: A comprehensive review and update. *Ophthalmic Surg Lasers Imaging Retina* 2015;46:650–7.
20. Ezzedine K, Gauthier Y, Leaute-Labreze C, Marquez S, Bouchtnei S, Jouary T, *et al.* Segmental vitiligo associated with generalized vitiligo (mixed vitiligo): A retrospective case series of 19 patients. *J Am Acad Dermatol* 2011;65:965–71.
21. Craig AM, Dotters-Katz S, Kuller JA, Thompson JL. Listeriosis in pregnancy: A review. *Obstet Gynecol Surv* 2019;74:362–8.
22. Morgan AJ, Steen CJ, Schwartz RA, Janniger CK. Erythema toxicum neonatorum revisited. *Cutis* 2009;83:13–6.
23. Laude TA. Approach to dermatologic disorders in black children. *Semin Dermatol* 1995;14:15–20.
24. Chapel TA, Gagliardi C, Nichols W. Congenital cutaneous candidiasis. *J Am Acad Dermatol* 1982;6:926–8.
25. Jezierska M, Stefanowicz J, Romanowicz G, Kosiak W, Lange M. Langerhans cell histiocytosis in children - a disease with many faces. Recent advances in pathogenesis, diagnostic examinations and treatment. *Postepy Dermatol Alergol* 2018;35:6–17.
26. Katsambas AD, Katoulis AC, Stavropoulos P. Acne neonatorum: A study of 22 cases. *Int J Dermatol* 1999;38:128–30.
27. Alakloby OM, Bukhari IA, Awary BH, Al-Wunais KM. Acne neonatorum in the eastern Saudi Arabia. *Indian J Dermatol Venereol Leprol* 2008;74:298.
28. Garcia-Patos V, Pujol RM, Moragas JM. Infantile eosinophilic pustular folliculitis. *Dermatology* 1994;189:133–8.
29. Darmstadt GL, Lane AT. Impetigo: An overview. *Pediatr Dermatol* 1994;11:293–303.
30. Loughhead JL. Congenital staphylococcal scaled skin syndrome: Report of a case. *Pediatr Infect Dis J* 1992;11:413–4.
31. Raval DS, Barton LL, Hansen RC, Kling PJ. Congenital cutaneous candidiasis: Case report and review. *Pediatr Dermatol* 1995;12:355–8.
32. Narvaez-Rosales V, de-Ocariz MS, Carrasco-Daza D, Ramirez-Davila B, Orozco-Covarrubias L, Duran-McKinster C, *et al.* Neonatal vesiculopustular eruption associated with transient myeloproliferative disorder: Report of four cases. *Int J Dermatol* 2013;52:1202–9.
33. Munn S, Chu AC. Langerhans cell histiocytosis of the skin. *Hematol Oncol Clin North Am* 1998;12:269–86.
34. Larsen L, Merin MR, Konia T, Armstrong AW. Congenital self-healing reticulohistiocytosis: Concern for a poor prognosis. *Dermatol Online J* 2012;18:2.
35. Mahe E. Childhood psoriasis. *Eur J Dermatol* 2016;26:537–48.
36. Bellet JS, Chamlin SL, Yan AC, Paller AS. Intertriginous pustular psoriasis. *J Am Acad Dermatol* 2009;60:679–83.
37. Darmstadt GL, Dinulos JG, Miller Z. Congenital cutaneous candidiasis: Clinical presentation, pathogenesis, and management guidelines. *Pediatrics* 2000;105:438–44.
38. Niamba P, Weill FX, Sarlangue J, Labreze C, Couprie B, Taieb A. Is common neonatal cephalic pustulosis (neonatal acne) triggered by *Malassezia sympodialis*? *Arch Dermatol* 1998;134:995–8.
39. Moncada B, Kettelsen S, Hernandez-Moctezuma JL, Ramirez F. Neonatal pemphigus vulgaris: Role of passively transferred pemphigus antibodies. *Br J Dermatol* 1982;106:465–7.
40. Colon-Fontanez F, Eichenfield LE, Krous HF, Friedlander SF. Congenital Langerhans cell histiocytosis: The utility of the Tzanck test as a diagnostic screening tool. *Arch Dermatol* 1998;134:1039–40.
41. Patel T, Patel AB, Moody M, Kelly B, Gibson B. Tzanck smear for quick screening of transient myeloproliferative disorder in neonates with vesiculopapular eruptions. *Int J Dermatol* 2015;54:e251–3.
42. Johnson DE, Thompson TR, Ferrieri P. Congenital candidiasis. *Am J Dis Child* 1981;135:273–5.