

Linear lichen planus of the genitalia

A 21-year-old man presented with an itchy rash over genitalia for three to four months duration. Examination revealed skin-coloured to violaceous papules, coalescing to form plaque at places, arranged linearly on the ventral aspect of the left side of penis and scrotum [Figure 1a]. Dermoscopy revealed reticulate white lines suggestive of Wickham striae

[Figure 1b], which corresponded to hypergranulosis in the histopathological examination of skin biopsy. While annular lichen planus is frequently observed in the penile region of men, the erosive variant predominantly affects the vulva in women. The linear lichen planus on the genitalia represents a rare clinical presentation.

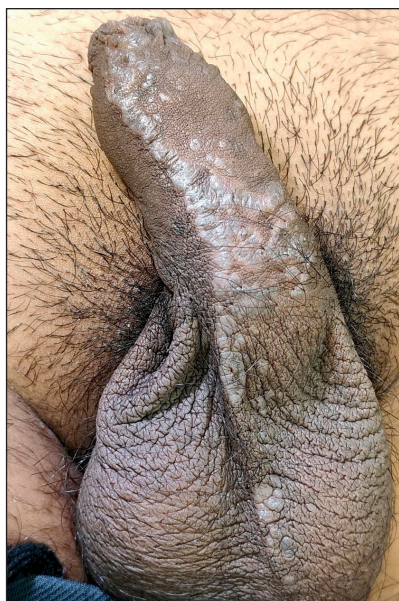

Figure 1a: Well-defined skin-coloured to violaceous flat-topped papules linearly arranged over the ventral aspect of the penis, extending over the scrotum.

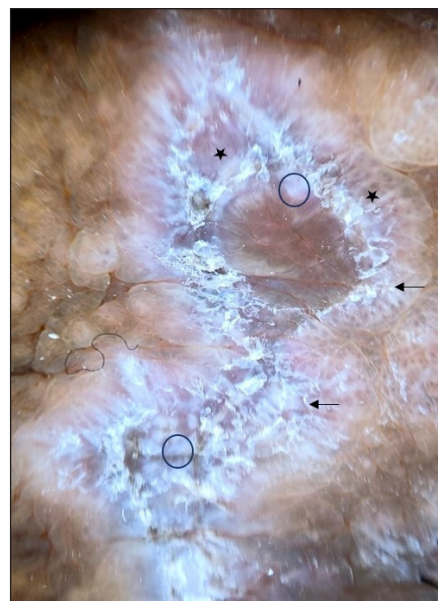


Figure 1b: Reticulate Wickham striae (black arrow), structureless white area (black circle), and blue grey globules on the brown background (black stars) (3Gen DermLite DL4 Dermoscope, CA, USA×10 polarised mode).

Declaration of patient consent: The authors certify that they have obtained all appropriate patient consent.

Financial support and sponsorship: Nil.

Conflicts of interest: There are no conflicts of interest.

Use of artificial intelligence (AI)-assisted technology for manuscript preparation: The authors confirm that there was no use of AI-assisted technology for assisting in the writing or editing of the manuscript and no images were manipulated using AI.

Departments of ¹Dermatology and ²Pathology, All India Institute of Medical Science, Nagpur, India.

Corresponding author:

Dr. Gitesh U Sawatkar,
Department of Dermatology, All India Institute of Medical Science,
Nagpur, India.
drgitesh@gmail.com

*Ariharasudhan Varadharajan¹, Prateek Nayak¹,
Gitesh U Sawatkar¹, Nisha Meshram²*

How to cite this article: Varadharajan A, Nayak P, Sawatkar GU, Meshram N. Linear lichen planus of the genitalia. Indian J Dermatol Venereol Leprol. 2025;91:S92. doi: 10.25259/IJDVL_1441_2024

Received: September, 2024 **Accepted:** December, 2024 **Epub Ahead of Print:** January, 2025 **Published:** April, 2025

DOI: 10.25259/IJDVL_1441_2024 **PMID:** 39912136

This is an open-access article distributed under the terms of the Creative Commons Attribution-Non Commercial-Share Alike 4.0 License, which allows others to remix, transform, and build upon the work non-commercially, as long as the author is credited and the new creations are licensed under the identical terms.