

Ultraviolet dermoscopy of cutaneous larva migrans

A middle-aged woman presented with itchy, red, raised lesions on her waist for 10 days. Examination revealed a well-defined serpiginous erythematous tract on the left flank [Figure 1]. Polarised dermoscopy (Dermlite DL5, 10x magnification) showed fine white scaling arranged in a serpiginous fashion with brownish-black dots and clods along the length [Figure 2a]. These brownish-black dots indicate spongiotic dermatitis, accompanied by an inflammatory infiltrate, vasodilation, red blood cell extravasation, and hemosiderin deposition. The parallelly arranged brown clods correspond to the helminth's body. Ultraviolet fluorescence dermoscopy revealed bluish fluorescence along the tracts, and enhanced visibility of hidden larval tracts [Figure 2b]. This technique aids in identifying the advancing larvae, guiding targeted biopsies, and facilitating appropriate treatment.

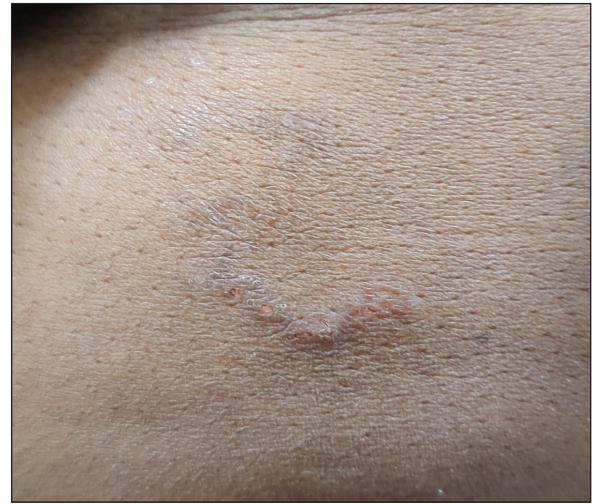

Figure 1: A well-defined serpiginous tract noted over the left flank.




Figure 2a: Dermoscopy of the lesion (Dermlite DL5, polarised mode, 10x magnification) revealing the presence of serpiginous scaling (arrow), with brownish-black dots and clods (circle) and parallel brown clods (square).




Figure 2b: Dermoscopy of the lesion (Dermlite DL5, ultraviolet mode, 10x magnification) shows the presence of bluish fluorescence overlying the serpiginous tracts (arrow) along with visualisation of the hidden larval tract (rectangle) originating from the previously thought area of termination (circle).

How to cite this article: Sivakumar A, Arora K, Kumar S. Ultraviolet dermoscopy of cutaneous larva migrans. Indian J Dermatol Venereol Leprol. doi: 10.25259/IJDVL_1835_2024

Received: December, 2024 **Accepted:** February, 2025 **Epub Ahead of Print:** April, 2025

DOI: 10.25259/IJDVL_1835_2024

This is an open-access article distributed under the terms of the Creative Commons Attribution-Non Commercial-Share Alike 4.0 License, which allows others to remix, transform, and build upon the work non-commercially, as long as the author is credited and the new creations are licensed under the identical terms.

Declaration of patient consent: The authors certify that they have obtained all appropriate patient consent.

Financial support and sponsorship: Nil.

Conflicts of interest: There are no conflicts of interest.

Use of artificial intelligence (AI)-assisted technology for manuscript preparation: The authors confirm that there was no use of artificial intelligence (AI)-assisted technology for assisting in the writing or editing of the manuscript and no images were manipulated using AI.

Aravind Sivakumar¹, Kashish Arora¹, Sheetanshu Kumar¹

¹Department of Dermatology, Jawaharlal Institute of Postgraduate Medical Education and Research, Puducherry, India

Corresponding author:

Dr. Sheetanshu Kumar,
Department of Dermatology, Jawaharlal Institute of Postgraduate Medical Education and Research, Puducherry, India.
kumar.sheetanshu@gmail.com