

Sporotrichoid Bowen disease in an immunosuppressed Indian patient

Sir,

Many infectious, inflammatory and neoplastic conditions have been reported to occur in a sporotrichoid pattern, besides sporotrichosis, whose classical presentation as multiple lesions along lymphatics lends its name to this pattern. Bowen disease or squamous cell carcinoma *in situ* usually occurs as a solitary lesion over sun-exposed sites with a 3–5% risk of progression to invasive carcinoma. Multiple lesions account for about 10–20% of all cases. It is less common in individuals of darker skin type and may be seen in association with various genodermatoses.¹ We report an interesting case of multiple Bowen disease occurring over the lower limb, in a sporotrichoid pattern in an immunosuppressed Indian patient.

A 58-year-old man with a past history of renal transplant for stage 5 chronic kidney disease, and on mycophenolate mofetil for 11 years, presented with three asymptomatic, hyperpigmented, crusted plaques over the left leg, arranged in a linear pattern. These had appeared in a distal to proximal distribution. He associated these with a minor trauma over the left foot sustained during gardening a few

months before the appearance of the first lesion. These lesions measured 0.5 × 0.5 cm to 0.5 × 1 cm with mild erythema, tenderness and underlying induration [Figures 1a and b]. There was no regional lymphadenopathy. He also had poorly controlled diabetes mellitus, hypertension and ischemic heart disease.

Differential diagnoses of deep fungal and atypical mycobacterial infection were kept and skin biopsy specimens from the distal plaque were sent for histopathological examination and relevant cultures. Histopathological examination revealed compact hyperkeratosis with a scale crust composed of parakeratosis, neutrophils and fibrin. The epidermis was acanthotic with full-thickness dysplasia with atypical keratinocytes of large size with hyperchromasia and dyskeratosis. The dermis showed capillary proliferation and lymphoplasmacytic infiltrate [Figures 2a and b]. These features indicated Bowen disease. Serial sections showed similar findings with no evidence of dermal invasion. A second biopsy from a proximal lesion showed similar features with the absence of dermal invasion confirmed on serial sections [Figures 3a and b]. Cultures

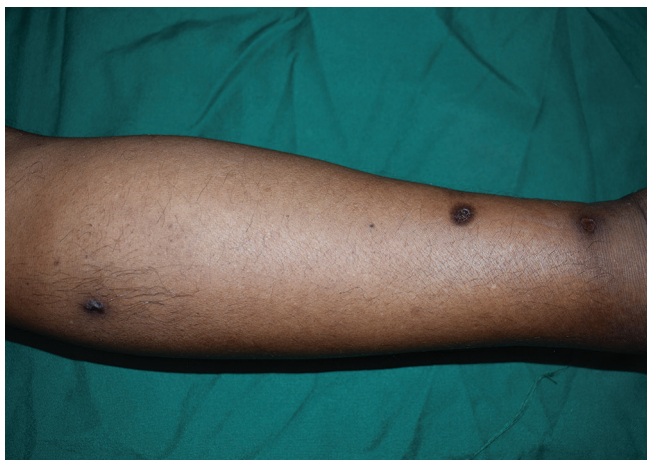


Figure 1a: Three hyperpigmented plaques with overlying scales along the lymphatics of the left leg in a sporotrichoid pattern

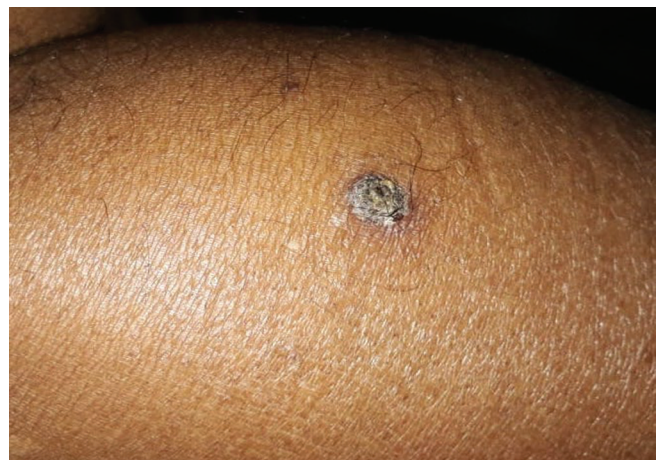

Figure 1b: Elevated plaque over left calf with a thick scale-crust, hyperpigmentation and surrounding mild erythema

How to cite this article: Dudani P, Khandpur S, Bhari N. Sporotrichoid Bowen disease in an immunosuppressed Indian patient. *Indian J Dermatol Venereol Leprol* 2021;87:839-41.

Received: July, 2020 Accepted: May, 2021 EPub Ahead of Print: October, 2021 Published: October 2021

DOI: 10.25259/IJDVL_959_20 PMID: 34623040

This is an open-access article distributed under the terms of the Creative Commons Attribution-Non Commercial-Share Alike 4.0 License, which allows others to remix, tweak, and build upon the work non-commercially, as long as the author is credited and the new creations are licensed under the identical terms.

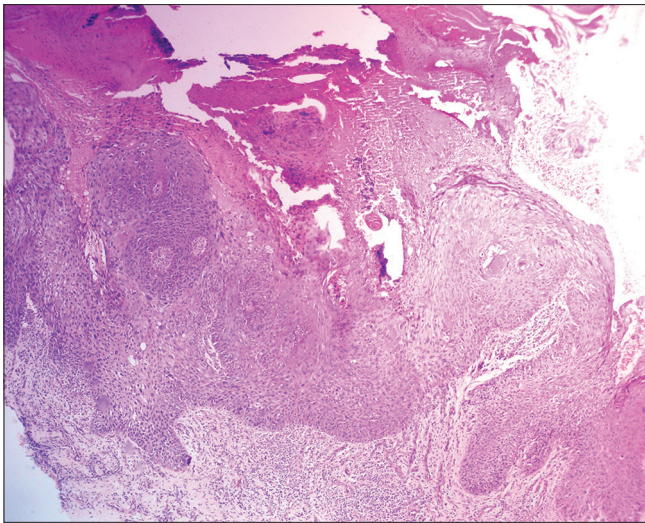


Figure 2a: Histopathological examination (H and E) showed acanthotic epidermis associated with hyperkeratosis and parakeratosis ×40

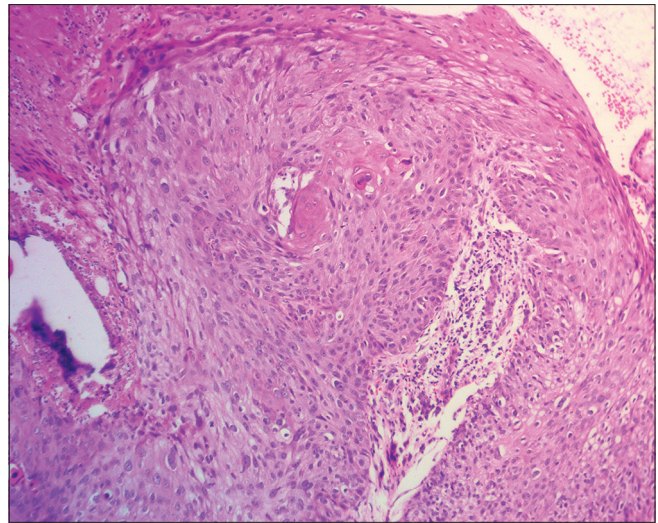


Figure 2b: The epidermis showed full-thickness dysplasia with dyskeratotic keratinocytes ×100

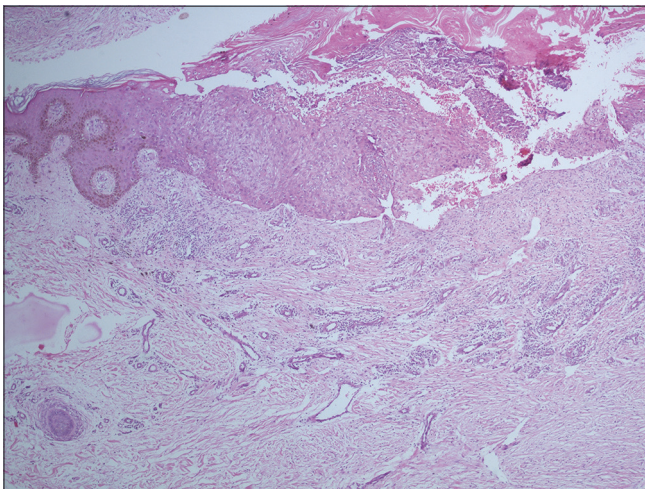


Figure 3a: Histopathological examination from a proximal plaque showed acanthotic epidermis with full-thickness dysplasia with dyskeratotic keratinocytes ×100

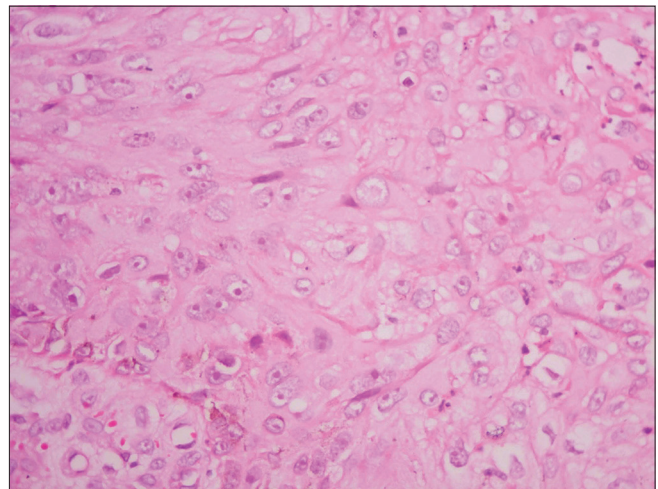


Figure 3b: The keratinocytes showed large nuclei with few dyskeratotic cells and atypical mitoses ×400

were negative for fungus, *Mycobacterium tuberculosis*, or atypical mycobacterial infection. On application of topical 5% 5-fluorouracil cream, once daily, the lesions resolved completely in ten weeks with hyperpigmentation. Based on similar biopsy findings in two distinct lesions and therapeutic response in all three, a diagnosis of sporotrichoid Bowen disease was made. On follow-up, the patient was found to have a growth over the upper pole of the native left-sided kidney, which on biopsy revealed a clear cell renal cell carcinoma.

The skin lesions resolved with treatment and duration similar to that described for non-linear Bowen disease, suggesting that linearly arranged Bowen disease behaves in a way similar to non-linear Bowen disease.² In most other disorders, such as lichen planus, psoriasis, pemphigus vulgaris and granuloma annulare, linear variants have been noted to have a poorer

response to treatment compared with non-linear lesions.³ The sporotrichoid or lymphocutaneous pattern, initially thought to be specific for sporotrichosis, has subsequently been reported in several other fungal, bacterial, protozoal and viral infections as well as inflammatory conditions such as granuloma annulare, rheumatoid nodules, lupus profundus and Sweet syndrome.⁴

We were able to find ten reports of neoplastic lesions occurring in this pattern, with four of them being metastases (three from squamous cell carcinoma and one from melanoma).⁵ The other neoplasms include keratoacanthoma, epithelioid sarcoma, Langerhans cell histiocytosis, lymphoma and peripheral nerve sheath tumor. A review of these reports showed no significant difference with respect to the anatomic site of involvement (equal for upper and lower limbs) or in survival with systemic or topical chemotherapy.⁴ While

lymphatic spread can explain infectious and malignant conditions, occurrence of benign tumors occurring in this pattern remains unexplained.

It is also worth noting that all three previously reported cases of sporotrichoid squamous cell carcinoma had occurred in immunocompetent individuals, while multiple lesions are otherwise more commonly reported in the background of immunosuppression.⁵ In our case, the co-occurrence of Bowen disease with well-differentiated renal cell carcinoma seems unrelated and merely a coincidence.

Declaration of patient consent

The authors certify that they have obtained all appropriate patient consent.

Financial support and sponsorship

Nil.

Conflicts of interest

There are no conflicts of interest.

Pankhuri Dudani, Sujay Khandpur, Neetu Bhari

Department of Dermatology and Venereology, All India Institute of Medical Sciences, New Delhi, India

Corresponding author:

Prof. Sujay Khandpur,
Department of Dermatology and Venereology, All India Institute of Medical Sciences, New Delhi, India.
sujoy_khandpur@yahoo.com

References

1. Gahalaut P, Rastogi MK, Mishra N, Chauhan S. Multiple pigmented Bowen disease: A diagnostic and therapeutic dilemma. *Case Rep Oncol Med* 2012;2012:342030.
2. Bargman H, Hochman J. Topical treatment of Bowen disease with 5-fluorouracil. *J Cutan Med Surg* 2003;7:101-5.
3. Happle R. Superimposed segmental manifestation of polygenic skin disorders. *J Am Acad Dermatol* 2007;57:690-9.
4. Abudu B, Cohen PR. Sporotrichoid keratoacanthomas: Case report and review of neoplasms presenting in a sporotrichoid pattern. *Cureus* 2018;10:e3196.
5. Ciocca O, Vassallo C, Brazzelli V, Fiandrino G, Rosso R, Borroni G. Sporotrichoid metastases to the skin from cutaneous squamous cell carcinoma in an immunocompetent patient. *Am J Dermatopathol* 2010;32:395-7.