

# Indian Journal of Dermatology, Venereology & Leprology

Journal indexed with SCI-E, PubMed, and EMBASE

Vol 74 | Issue 2 | Mar-Apr 2008

C O N T E N T S

## EDITORIAL

### Management of autoimmune urticaria

Arun C. Inamadar, Aparna Palit ..... 89

## VIEW POINT

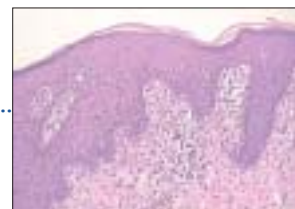### Cosmetic dermatology versus cosmetology: A misnomer in need of urgent correction

Shyam B. Verma, Zoe D. Draelos ..... 92

## REVIEW ARTICLE

### Psoriasiform dermatoses

Virendra N. Sehgal, Sunil Dogra, Govind Srivastava, Ashok K. Aggarwal ..... 94



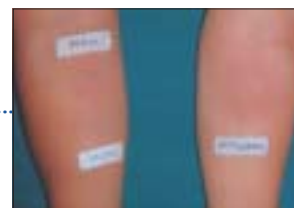## ORIGINAL ARTICLES

### A study of allergen-specific IgE antibodies in Indian patients of atopic dermatitis

V. K. Somani ..... 100

### Chronic idiopathic urticaria: Comparison of clinical features with positive autologous serum skin test

George Mamatha, C. Balachandran, Prabhu Smitha ..... 105



### Autologous serum therapy in chronic urticaria: Old wine in a new bottle

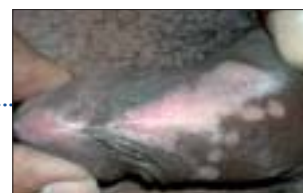A. K. Bajaj, Abir Saraswat, Amitabh Upadhyay, Rajetha Damisetty, Sandipan Dhar ..... 109

### Use of patch testing for identifying allergen causing chronic urticaria

Ashimav Deb Sharma ..... 114

### Vitiligoid lichen sclerosis: A reappraisal

Venkat Ratnam Attali, Sasi Kiran Attali ..... 118



**BRIEF REPORTS**

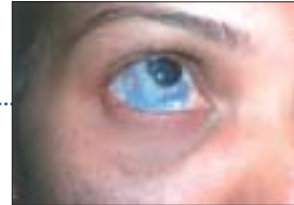**Activated charcoal and baking soda to reduce odor associated with extensive blistering disorders**

Arun Chakravarthi, C. R. Srinivas, Anil C. Mathew ..... 122



**Nevus of Ota: A series of 15 cases**

Shanmuga Sekar, Maria Kuruvila, Harsha S. Pai ..... 125



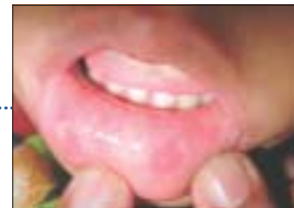**Premature ovarian failure due to cyclophosphamide: A report of four cases in dermatology practice**

Vikrant A. Saoji ..... 128

**CASE REPORTS**

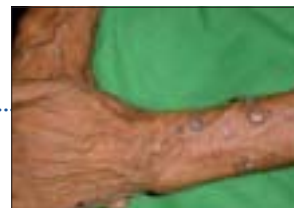**Hand, foot and mouth disease in Nagpur**

Vikrant A. Saoji ..... 133



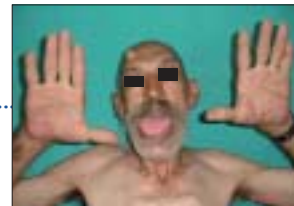**Non-familial multiple keratoacanthomas in a 70 year-old long-term non-progressor HIV-seropositive man**

Hemanta Kumar Kar, Sunil T. Sabhnani, R. K. Gautam, P. K. Sharma, Kalpana Solanki, Meenakshi Bhardwaj ..... 136



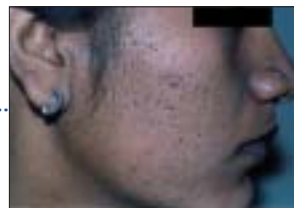**Late onset isotretinoin resistant acne conglobata in a patient with acromegaly**

Kapil Jain, V. K. Jain, Kamal Aggarwal, Anu Bansal ..... 139



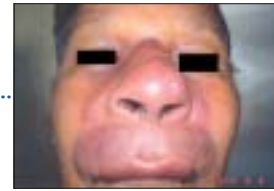**Familial dyskeratotic comedones**

M. Sendhil Kumaran, Divya Appachu, Elizabeth Jayaseelan ..... 142



**Nasal NK/T cell lymphoma presenting as a lethal midline granuloma**

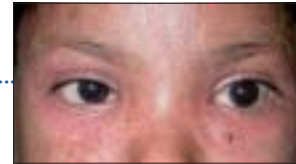Vandana Mehta, C. Balachandran, Sudha Bhat, V. Geetha, Donald Fernandes .....



145

**Childhood sclerodermatomyositis with generalized morphea**

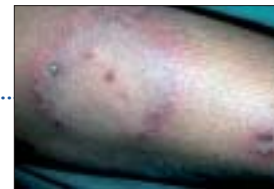Girishkumar R. Ambade, Rachita S. Dhurat, Nitin Lade, Hemangi R. Jerajani.....



148

**Subcutaneous panniculitis-like T-cell cutaneous lymphoma**

Avninder Singh, Joginder Kumar, Sujala Kapur, V. Ramesh.....



151

**LETTERS TO EDITOR**

**Using a submersible pump to clean large areas of the body with antiseptics**

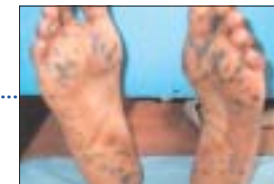C. R. Srinivas.....



154

**Peutz-Jeghers syndrome with prominent palmoplantar pigmentation**

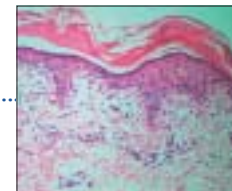
K. N. Shivaswamy, A. L. Shyamprasad, T. K. Sumathi, C. Ranganathan.....



154

**Stratum corneum findings as clues to histological diagnosis of pityriasis lichenoides chronica**

Rajiv Joshi .....



156

**Author's reply**

S. Pradeep Nair.....

157

**Omalizumab in severe chronic urticaria**

K. V. Godse.....

157

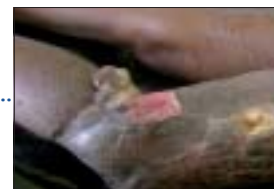**Hypothesis: The potential utility of topical eflornithine against cutaneous leishmaniasis**

M. R. Namazi .....

158

**Nodular melanoma in a skin graft site scar**

A. Gnaneshwar Rao, Kamal K. Jhamnani, Chandana Konda .....

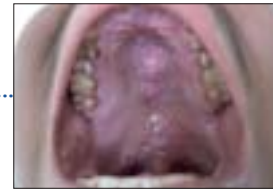

159

**Palatal involvement in lepromatous leprosy**

A. Gnaneshwar Rao, Chandana Konda, Kamal Jhamnani.....

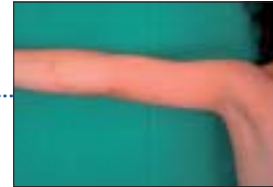161



**Unilateral nevoid telangiectasia with no estrogen and progesterone receptors in a pediatric patient**

F. Sule Afsar, Ragip Ortac, Gulden Diniz.....

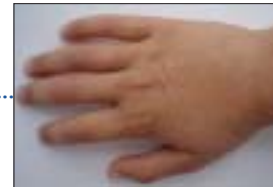163



**Eruptive lichen planus in a child with celiac disease**

Dipankar De, Amrinder J. Kanwar.....

164



**Xerosis and pityriasis alba-like changes associated with zonisamide**

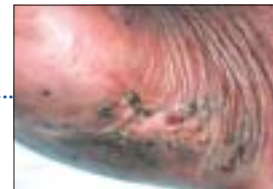Feroze Kaliyadan, Jayasree Manoj, S. Venkitakrishnan.....

165

**Treatment of actinomycetoma with combination of rifampicin and co-trimoxazole**

Rajiv Joshi.....

166



**Author's reply**

M. Ramam, Radhakrishna Bhat, Taru Garg, Vinod K. Sharma, R. Ray, M. K. Singh, U. Banerjee, C. Rajendran.....

168

**Vitiligo, psoriasis and imiquimod: Fitting all into the same pathway**

Bell Raj Eapen.....

169

**Author's reply**

Engin Şenel, Deniz Seçkin.....

169

**Multiple dermatofibromas on face treated with carbon dioxide laser: The importance of laser parameters**

Kabir Sardana, Vijay K. Garg.....

170

**Author's reply**

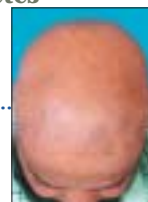D. S. Krupa Shankar, A. Kushalappa, K. S. Uma, Anjay A. Pai.....

170

**Alopecia areata progressing to totalis/universalis in non-insulin dependent diabetes mellitus (type II): Failure of dexamethasone-cyclophosphamide pulse therapy**

Virendra N. Sehgal, Sambit N. Bhattacharya, Sonal Sharma, Govind Srivastava, Ashok K. Aggarwal.....

171



**Subungual exostosis**

Kamal Aggarwal, Sanjeev Gupta, Vijay Kumar Jain, Amit Mital, Sunita Gupta.....

173

**Clinicohistopathological correlation of leprosy**

Amrish N. Pandya, Hemali J. Tailor ..... 174

**RESIDENT'S PAGE**

**Dermatographism**

Dipti Bhute, Bhavana Doshi, Sushil Pande, Sunanda Mahajan, Vidya Kharkar ..... 177

**FOCUS**

**Mycophenolate mofetil**

Amar Surjushe, D. G. Saple ..... 180

**QUIZ**

**Multiple papules on the vulva**

G. Raghu Rama Rao, R. Radha Rani, A. Amareswar, P. V. Krishnam  
Raju, P. Raja Kumari, Y. Hari Kishan Kumar ..... 185



**E-IDVL**

**Net Study**

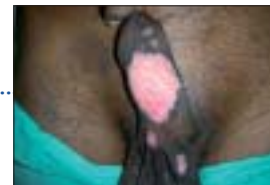**Oral isotretinoin is as effective as a combination of oral isotretinoin and topical anti-acne agents in nodulocystic acne**

Rajeev Dhir, Neetu P. Gehi, Reetu Agarwal, Yuvraj E. More ..... 187

**Net Case**

**Cutaneous diphtheria masquerading as a sexually transmitted disease**

T. P. Vetrichevvel, Gajanan A. Pise, Kishan Kumar Agrawal,  
Devinder Mohan Thappa ..... 187



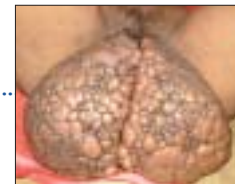**Net Letters**

**Patch test in Behcet's disease**

Ülker Gül, Müzeyyen Gönül, Seray Külcü Çakmak, Arzu Kılıç ..... 187

**Cerebriform elephantiasis of the vulva following tuberculous lymphadenitis**

Surajit Nayak, Basanti Acharjya, Basanti Devi, Satyadarshi Pattnaik,  
Manoj Kumar Patra ..... 188



**Net Quiz**

**Vesicles on the tongue**

Saurabh Agarwal, Krishna Gopal, Binay Kumar ..... 188



## Multiple papules on the vulva

A 26 year-old married woman presented with a two-year history of asymptomatic, multiple papular lesions on the vulva. There was no history of premarital or extramarital exposure. On clinical examination, there were multiple, small, firm, skin-colored papules on the vulva [Figure 1]. The lesions were nontender and there was no lymphadenopathy. Systemic examination including per vaginal and per rectum examinations, revealed no abnormality. Routine investigations were normal. Test for HBsAg, HIV I and II, VDRL were non-reactive. A 3 mm punch biopsy was done for the lesion. Histopathology showed a normal epidermis and the dermis showed a number of small cysts and ducts lined by two rows of cells. Some of the cysts were filled with keratin material. Walls of some of the ducts had epithelial extensions [Figure 2].

### WHAT IS YOUR DIAGNOSIS?

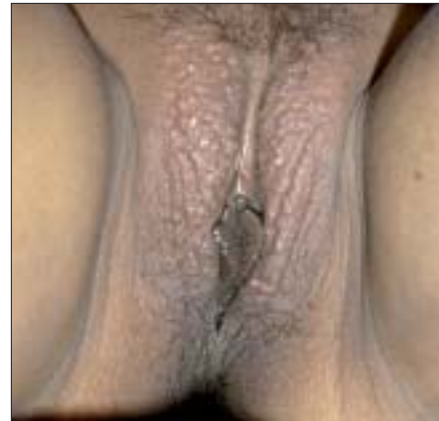

Figure 1: Multiple papules on vulva

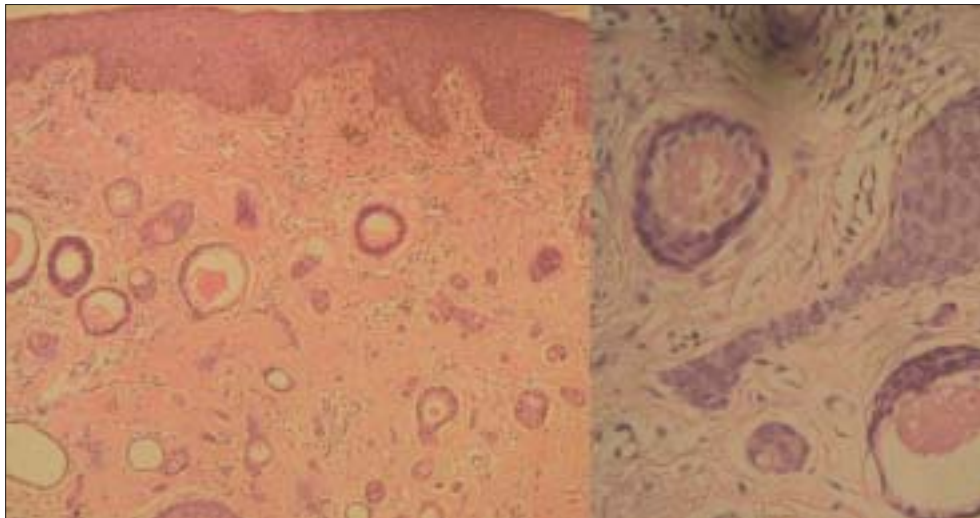


Figure 2: Small cysts lined by two rows of cells filled with keratin material, A. few ducts showing epithelial extensions (H & E, x200) B. High power view of the ducts (H & E, x400)

**How to cite this article:** Rao GRR, Rani RR, Amareswar A, Raju PVK, Kumari PR, Kumar YHK. Multiple papules on the vulva. Indian J Dermatol Venereol Leprol 2008;74:185-6.

**Received:** June, 2007. **Accepted:** July, 2007. **Source of Support:** Nil. **Conflict of Interest:** Nil.

## DIAGNOSIS: SYRINGOMA OF THE VULVA

### DISCUSSION

Syringoma is a benign tumor of eccrine sweat ducts characterized by single or multiple, small, firm, skin-colored or yellowish papules. These papules have rounded or flat-topped surfaces and may or may not be pruritic. The most common site is the periorbital region (lower eyelid); other areas are cheeks, axillae, abdomen and genitals.<sup>[1]</sup>

Vulvar syringomas are rare with only a few cases reported in literature.<sup>[2-6]</sup> They occur in young women after puberty.<sup>[2]</sup> The most common presentation is that of multiple flesh-colored or brownish papules on the labia majora. These lesions are clinically difficult to differentiate from epidermal cysts, steatocystoma multiplex, condyloma, Fox-Fordyce disease, cherry hemangioma, angiokeratoma, soft fibroma and lymphangioma circumscriptum.<sup>[7]</sup> They are one of the causes for vulvar pruritus. Some patients have exacerbation of pruritus and increase in the size of lesions during the summer or during menstruation. A diagnosis of vulvar syringomas should be considered if a patient with lichen simplex chronicus of labia major responds poorly to oral antihistamine and topical steroids.<sup>[2]</sup> Similarly, in men, syringomas can occur albeit rarely on the penis.<sup>[6]</sup> A skin biopsy is necessary to confirm the diagnosis.

No effective treatment modality has been documented. Treatment options include excision, cryotherapy, electrosurgery and carbon dioxide laser treatment. Topical steroids and oral antihistamines were not effective in controlling pruritus in our patient. Topical atropine and

topical tretinoin may be tried.<sup>[8]</sup> Carbon dioxide laser is an effective therapeutic modality in patients with intractable pruritus.<sup>[2]</sup>

**G. Raghu Rama Rao, R. Radha Rani,  
A. Amaeswar, P. V. Krishnam Raju,  
P. Raja Kumari<sup>1</sup>, Y. Hari Kishan Kumar**

Surya Skin Care and Research Center, Visakhapatnam, <sup>1</sup>Consultant Pathologist, Arya diagnostic labs, Visakhapatnam, India

**Address for Correspondence:** Dr. G. Raghurama Rao, Surya Skin Care and Research Center, #15-1-2, Gopal Sadan, Naoroji Road, Maharanipeta, Visakhapatnam - 530 002, Andhra Pradesh, India.  
E-mail: graghuramarao@hotmail.com

### REFERENCES

1. Kaddu S, Kerl H. Appendage tumors of the Skin. Fitzpatrick's Dermatology in general medicine; 6<sup>th</sup>ed. Vol. 1; McGraw - Hill Medical Publishers: p. 794-5.
2. Haung YH, Chaung YH, Kuo TT. Vulvar syringoma: A clinico pathologic and immunohistologic study of 18 patients and results of treatment. J Am Acad Dermatol 2003;48:735-9.
3. Tawade YV. Syringoma of the vulva. Indian J Dermatol Venereol Leprol 2000;66:326-7.
4. Isaacson D, Turner ML. Localized vulvar syringomas. J Am Acad Dermatol 1979;1:352-6.
5. Karam P, Benedetto AV. Syringomas: New approach to an old technique. Int J Dermatol 1996;35:219-20.
6. Zalla SA, Perry HO. An unusual case of syringoma. Arch Dermatol 1971;103:215-7.
7. Young AW Jr, Herman EW, Tovell HM. Syringoma of the vulva: Incidence, diagnosis and cause of pruritus. Obstet Gynaecol 1980;55:515-8.
8. Klunger N, Mishra S, Jain RK, Saxena S. Multiple eccrine hidrocystomas: Report of two cases treated unsuccessfully with atropine ointment. Indian J Dermatol Venereol Leprol 2004;70:367-9.