

WHAT IS YOUR DIAGNOSIS ?

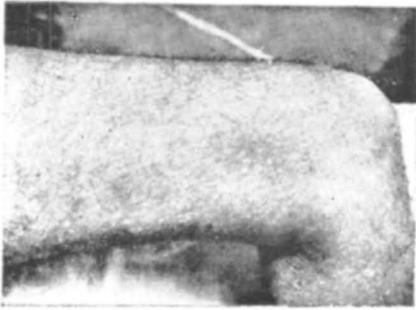


Fig. 1

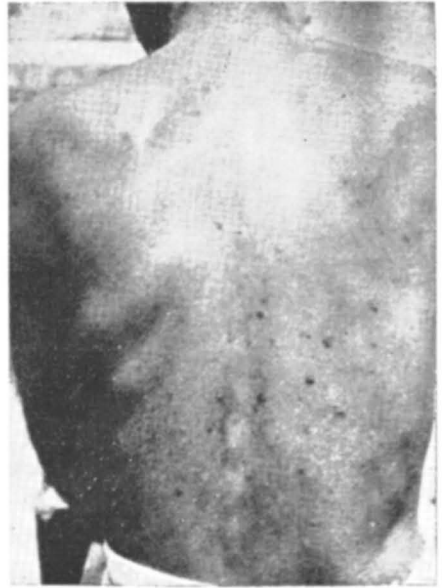

Fig. 2

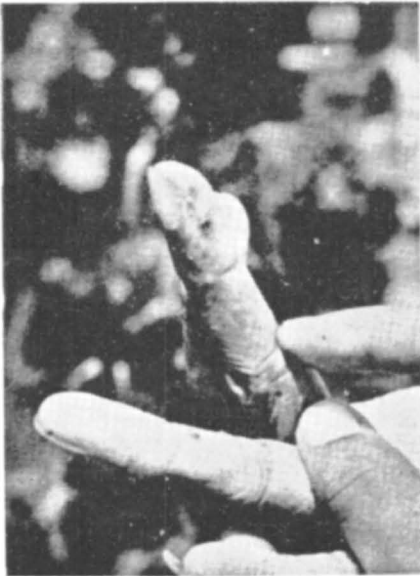

Fig. 3

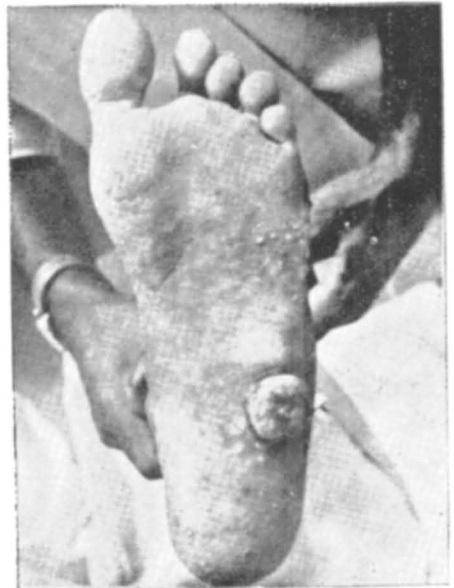

Fig. 4

(Question & Answer overleaf)

Fig. 1 : “ Rain drops on a dusty road ” appearance on the skin of thigh.

Fig. 2 : Pigmented warty lesions on the back and hypopigmented spots.

Fig. 3 : ‘ Keratoses ’ on the palms

Fig. 4 : Keratotic lesions and fungating growth left sole foot.

Differential diagnoses :

1. Xeroderma pigmentosum
2. Arsenical pigmentation and keratosis
3. Malignant Melanoma

He is a case of Chronic bronchial asthma and has taking several medicines including Ayurveda. Biopsy of a keratosis of palm revealed typical features of Arsenical Keratosis. Biopsy of the fungating growth showed Sq. Cell Ca. Final Diagnosis is Arsenical pigmentation and keratosis.

A 62 year old man came with the following manifestations of more than 2 years duration :

1. Generalised mild hyperpigmentation
2. Pea sized hypopigmented macules all over the body
3. Multiple keratosis particularly palms and soles ; and
4. Large fungating growth sole of left foot of 6 months duration.

DIAGNOSIS