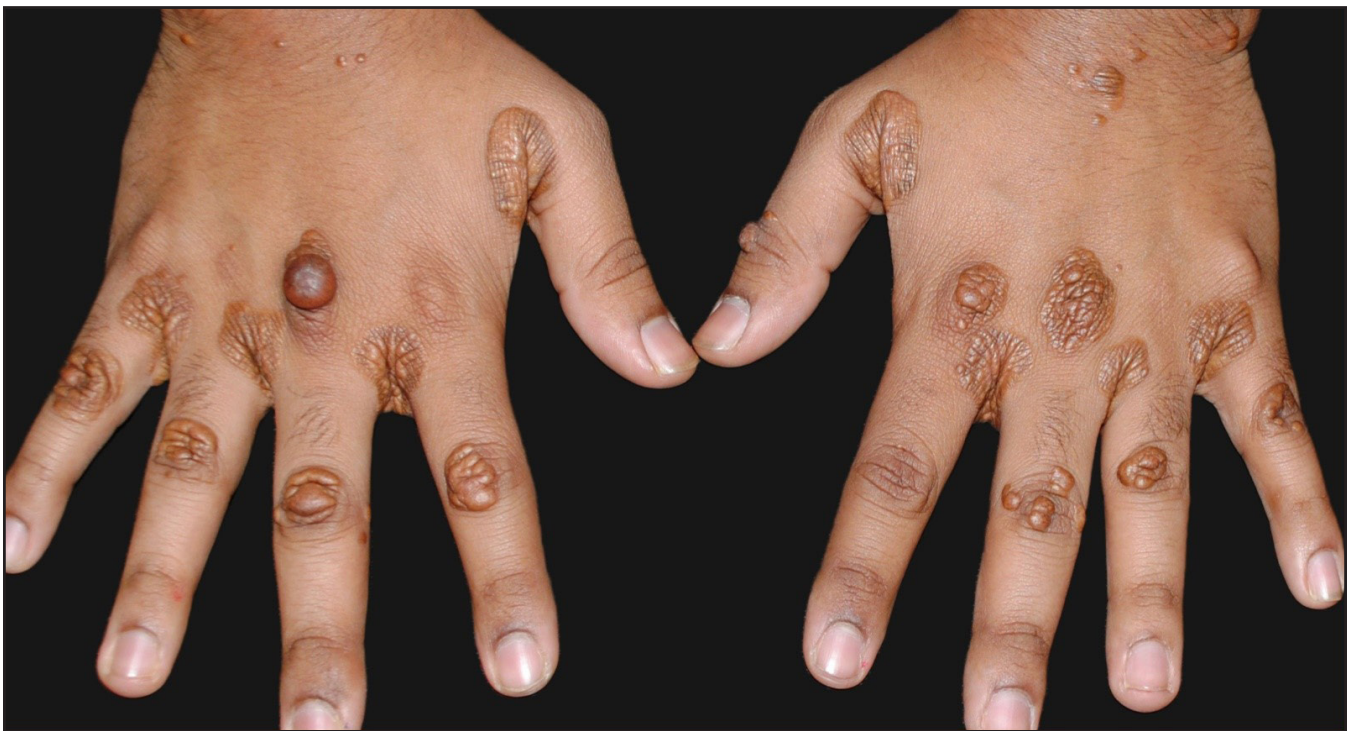


## Interdigital, tendon, and gluteal xanthomas in familial hypercholesterolemia

A 21-year-old male presented with multiple asymptomatic yellowish-brown papules, plaques, and nodules over web spaces, proximal interphalangeal joints, and metacarpophalangeal joints of both hands [Figure 1a], elbows [Figure 1b], and gluteal region [Figure 1c] since the age of six years. His father had died of myocardial infarction at 39 years and his paternal uncle aged 34 years was on treatment for coronary artery disease. Investigations

revealed elevated total cholesterol (723 mg/dl) and low-density lipoprotein (LDL) cholesterol (602 mg/dl). Heart echocardiography was normal. Genetic studies showed a missense mutation in the LDL-receptor gene (c.2054C>T). He was diagnosed as familial hypercholesterolemia and started on pravastatin and counselled regarding lifestyle modifications. Follow-up at the sixth month revealed persistence of xanthomas and normal cholesterol levels.



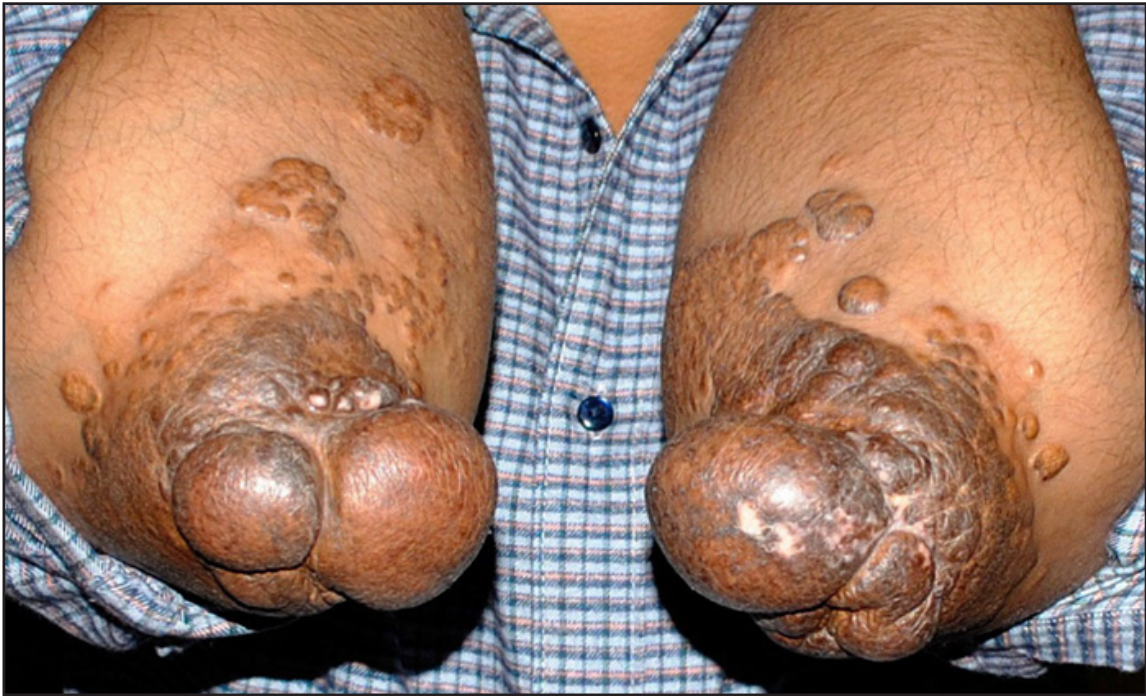**Figure 1a:** Interdigital and tendon xanthomas over both the hands.

**How to cite this article:** Kothari R, Khare S. Interdigital, tendon, and gluteal xanthomas in familial hypercholesterolemia. *Indian J Dermatol Venereol Leprol.* 2025;91:268-9. doi: 10.25259/IJDVL\_521\_2024

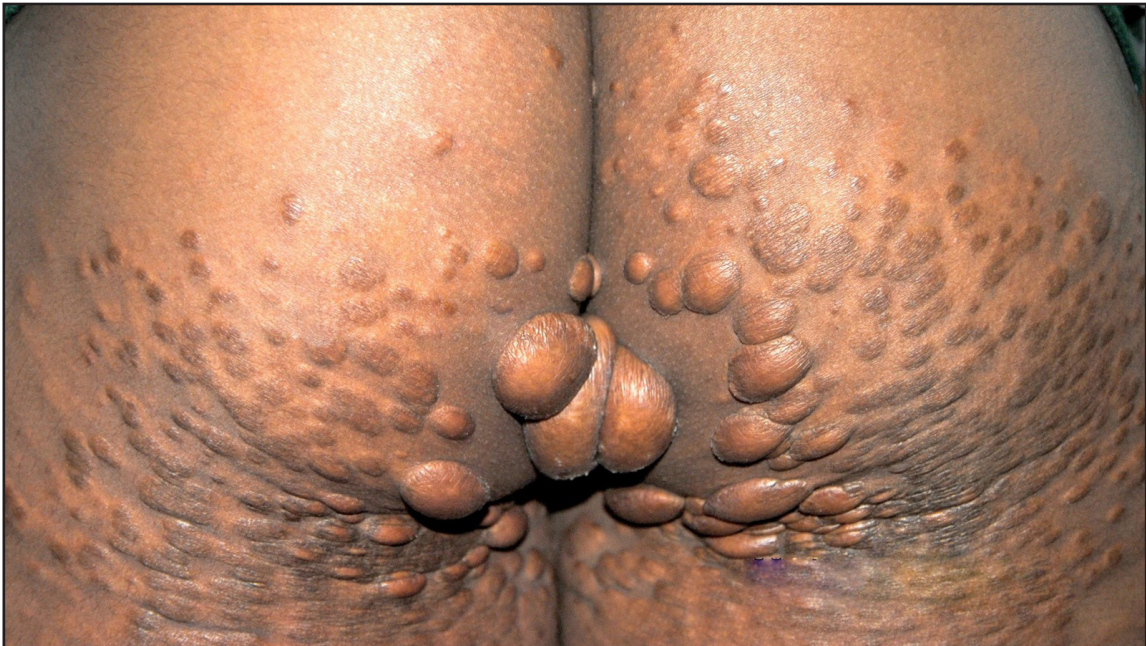**Received:** April, 2024 **Accepted:** April, 2024 **Epub Ahead of Print:** July, 2024 **Published:** February, 2025

**DOI:** 10.25259/IJDVL\_521\_2024 **PMID:** 39152848

This is an open-access article distributed under the terms of the Creative Commons Attribution-Non Commercial-Share Alike 4.0 License, which allows others to remix, transform, and build upon the work non-commercially, as long as the author is credited and the new creations are licensed under the identical terms.



**Figure 1b:** Tendon xanthomas over the elbows.



**Figure 1c:** Gluteal xanthomas.

**Declaration of patient consent:** The authors certify that they have obtained all appropriate patient consent.

**Financial support and sponsorship:** Nil.

**Conflicts of interest:** There are no conflicts of interest.

**Use of artificial intelligence (AI)-assisted technology for manuscript preparation:** The authors confirm that there was no use of AI-assisted technology for assisting in the writing or editing of the manuscript and no images were manipulated using AI.

**Corresponding author:**

Dr. Rohit Kothari,  
Department of Dermatology, 12 Air Force Hospital,  
Gorakhpur, India.  
rohitkothari3422@gmail.com

**Rohit Kothari<sup>1</sup>, Sanjay Khare<sup>2</sup>**

<sup>1</sup>Department of Dermatology, 12 Air Force Hospital, Gorakhpur,

<sup>2</sup>Department of Dermatology, Mahatma Gandhi Memorial Medical College,  
Indore, Madhya Pradesh, India.