

## Acral syringomas associated with hematological neoplasm

Sir,  
Syringomas are benign acrosyringial tumors that typically manifest in adolescent and middle-aged women as asymptomatic, flat or dome-shaped, yellowish-brown papules located on the lower eyelids. Their underlying etiology is unknown. Acral syringomas are rare in the medical literature. Unlike typical clinical syringomas, they have been described in older patients with no gender predominance and are associated with tumor pathology.

A 62-year-old woman with a history of invasive breast cancer, diagnosed 17 years ago, was treated with surgery, radiation therapy and tamoxifen and had suffered no relapses. She was also diagnosed with promyelocytic leukemia 2 years ago and was treated with oral methotrexate, mercaptopurine and tretinoin, but has been in complete remission. She did not have any dermatological disorders till then.

She sought a dermatology consultation when she developed multiple, asymptomatic brownish, non-follicular, confluent and symmetrical papules on the anterior side of both forearms and periocular area over the course of 2 years [Figure 1]. The lesions began shortly after the hematological diagnosis and before the initiation of anti-neoplastic treatment.

The histopathological examination showed glandular structures in the superficial dermis composed of double-cell layer tubular structures with no atypia or mitosis within an eosinophilic stroma [Figure 2]. Congo red staining was negative. Immunohistochemistry was negative for estrogen receptors, slightly positive for epithelial membrane antigen in the periphery and positive for carcinoembryonic antigen and p63 [Figure 3]. The findings were compatible with syringoma.

In the 2-year follow-up period, no recurrence of the hematological neoplasm was noted, but cutaneous lesions remain unchanged.

Syringomas are benign tumors of the acrosyringium. Clinically, they usually appear as flat or dome-shaped, yellowish-brown papules, located in the lower palpebral area of young to middle-aged women. The etiology is unknown. Friedman and Butler have classified them into four variants based on the clinical picture: localized, associated with Down's syndrome, generalized eruptive syringomas and an autosomal dominant familial form.<sup>1</sup> Syringomas have also been described in multiple atypical sites such as the trunk, upper and lower extremities, buttocks and genitals.<sup>2-6</sup>

Syringomas of acral location, affecting the distal end of the extremities, are rare in the medical literature. There have only been 13 cases published to date [Table 1]. They differ from typical palpebral syringomas because they appear in older patients, affect both sexes equally and are frequently associated with tumor pathology.<sup>7</sup> Cases of acral syringomas associated with syringomas of typical bilateral infraorbital location have also been described.

Histologically, they appear as glandular cords and ducts in the superficial dermis, composed of a double cell layer with no atypia, in a collagenous and homogeneous stroma. Some cells may show eccentric prolongations, when they are typically compared to 'comma' or 'tadpole tail-shaped' structures.

The clinical differential diagnosis includes lichenoid eruptions, mastocytosis, sarcoidosis, granuloma annulare and other granulomatous processes.

This is an open access article distributed under the terms of the Creative Commons Attribution-NonCommercial-ShareAlike 3.0 License, which allows others to remix, tweak, and build upon the work non-commercially, as long as the author is credited and the new creations are licensed under the identical terms.

For reprints contact: reprints@medknow.com

**How to cite this article:** Varas-Meis E, Prada-García C, Samaniego-González E, Rodríguez-Prieto MÁ. Acral syringomas associated with hematological neoplasm. Indian J Dermatol Venereol Leprol 2017;83:136.

**Received:** December, 2015. **Accepted:** June, 2016.

### Access this article online

#### Quick Response Code:

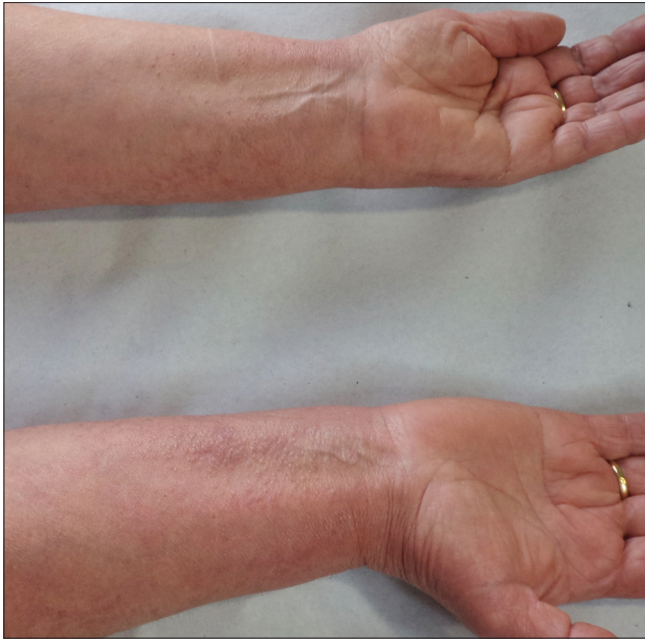

#### Website:

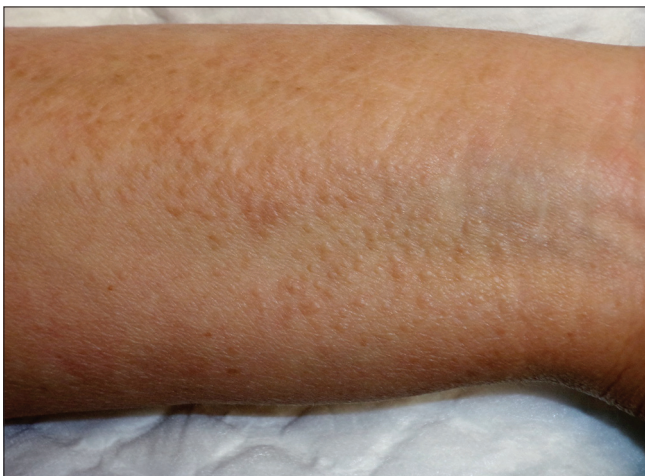www.ijdvl.com

#### DOI:

10.4103/0378-6323.192961



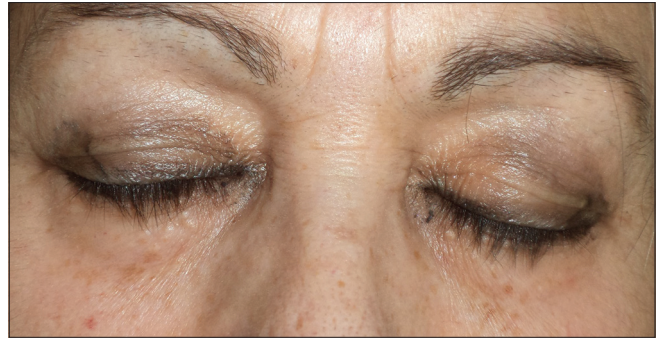**Figure 1a: Normal coloured to brownish papular, flat and smooth, confluent lesions of symmetrical distribution on anterior side of both wrists**



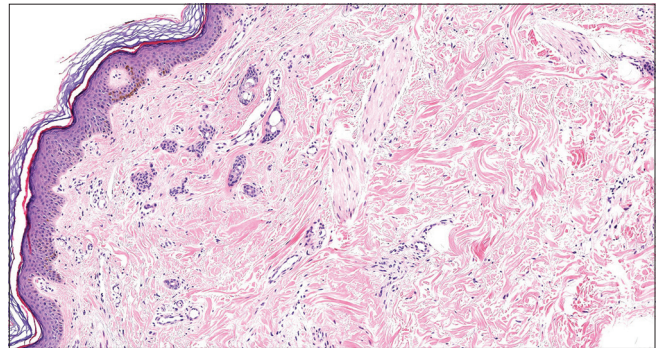
**Figure 1c: Normal coloured to brownish papular, flat and smooth, confluent lesions of symmetrical distribution on detailed lesions on forearm**

The lesions do not require treatment except for esthetic or symptomatic reasons. Surgical excision, cryotherapy, electrocoagulation, topical atropine, tretinoin and CO<sub>2</sub>, erbium-yttrium aluminum garnet, argon, or pulsed dye lasers have been used with inconsistent results.<sup>3,7,13</sup>

We were unable to find any previous reports of syringomas associated with hematological neoplasms which may be a triggering factor in the appearance of these lesions but are independent of



**Figure 1b: Normal coloured to brownish papular, flat and smooth, confluent lesions of symmetrical distribution on both lower eyelids**



**Figure 2: Glandular infiltration into the superficial dermis (H and E, x40)**

evolution. However, this could only be a coincidental association.

The mechanisms leading to the development of these lesions remain unclear. The immunosuppression and the hyperproliferative state associated with the hematological neoplasm could contribute to this atypical presentation of the syringomas. Although the association of acral syringoma and breast cancer has been reported, the 17-year difference in the presentation of our case prompted us to consider it as a coincidental finding.<sup>11</sup>

In conclusion, we believe, like other authors, that acral syringomas should constitute an independent class within the original classification of Friedman and Butler due to their unique clinical characteristics.<sup>4,7,12</sup>

#### **Financial support and sponsorship**

Nil.

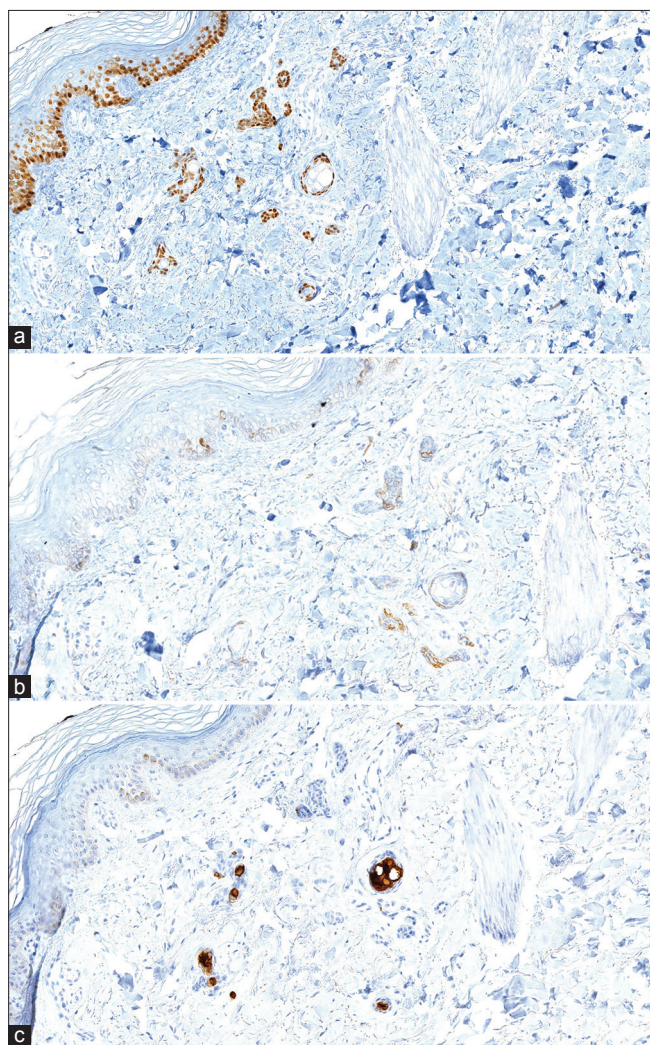
#### **Conflicts of interest**

There are no conflicts of interest.

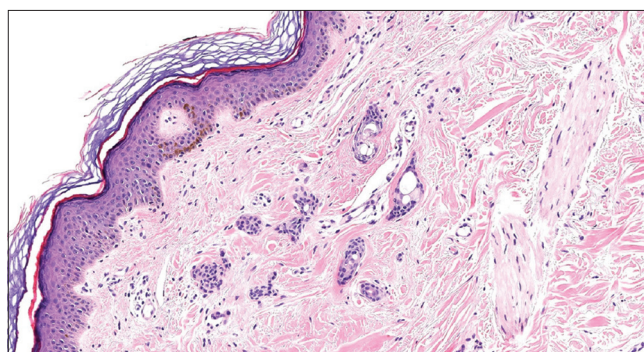
**Table 1: Previous reports of acral syringomas<sup>2-5, 7-13</sup>**

Case number	Sex	Age	Location	Time (months)	Associated diseases	Author	Year
1	Male	31	Back of hands		No	Hughes and Apisarnthanarax	1977
2	Female	35	Back of hands + infraorbital		No	Asai	1982
3	Male	52	Back of wrist and forearms	5-6	Clear cell acanthoma	Van den Broek	1982
4	Male	52	Anterior forearms	12	Carcinoid tumor	Berbis	1989
5	Male	69	Back of hands and anterior forearms	18	BCC superficial spreading melanoma Breslow 0.8	Metze	1990
6	Female	43	Back of hands and feet	6	Breast cancer, tamoxifen and CT	Garcia	1997
7	Male	43	Wrist and forearms		No	Patrizi	1998
8	Female	60	Forearms and breast scar		Breast tubular adenoma	Patrizi	1998
9	Female	43	Forearms	24	Photosensitivity reaction	Martin-García	2006
10	Female	28	Back of hands	192	No	Muniesa	2008
11	Female	27	Back of phalanges	180	No	Koh	2009
11	Female	41	Anterior forearms	48	Periorbital trichoepitheliomas	Balci	2009
12	Female	44	Back of forearms	48	No	Valdivieso-Ramos	2009
13	Female	62	Anterior forearms + periorbital	36	Promyelocytic leukemia	Varas-Meis and Prada	2015

BCC: Basal cell carcinoma, CT: Chemotherapy



**Figure 3: (a) Immunohistochemistry with p63 positive (x40). (b) Immunohistochemistry with slightly EMA positive (x40). (c) Immunohistochemistry with tubular lumen CEA positive result (x40)**



**Figure 3d: Detailed tubular infiltration (H and E, x40)**

**Eduardo Varas-Meis,  
Camino Prada-García, Elia Samaniego-González,  
Manuel-Ángel Rodríguez-Prieto**

Department of Dermatology, Hospital of León, León, Spain

**Address for correspondence:** Dr. Eduardo Varas-Meis,  
Department of Dermatology, Complejo Asistencial  
Universitario de León, Altos de Nava, s/n, León 24080, Spain.  
E-mail: edu.varas.meis@gmail.com

## REFERENCES

- Friedman SJ, Butler DF. Syringoma presenting as milia. *J Am Acad Dermatol* 1987;16(2 Pt 1):310-4.
- Balci DD, Atik E, Altintas S. Coexistence of acral syringomas and multiple trichoepitheliomas on the face. *J Cutan Med Surg* 2009;13:169-71.
- Koh MJ. Multiple acral syringomas involving the hands. *Clin Exp Dermatol* 2009;34:e438.
- Martín-García RF, Muñoz CM. Acral syringomas presenting as a photosensitive papular eruption. *Cutis* 2006;77:33-6.
- Metze D, Jurecka W, Gebhart W. Disseminated syringomas of the upper extremities. Case history and immunohistochemical and ultrastructural study. *Dermatologica* 1990;180:228-35.
- van den Broek H, Lundquist CD. Syringomas of the upper

- extremities with onset in the sixth decade. *J Am Acad Dermatol* 1982;6 (4 Pt 1):534-6.
7. Valdivielso-Ramos M, de la Cueva P, Gimeno M, Hernanz JM. Acral syringomas. *Actas Dermosifiliogr* 2010;101:458-60.
  8. Asai Y, Ishii M, Hamada T. Acral syringoma: Electron microscopic studies on its origin. *Acta Derm Venereol* 1982;62:64-8.
  9. Hughes PS, Apisarnthanarax P. Acral syringoma. *Arch Dermatol* 1977;113:1435-6.
  10. Berbis P, Fabre JF, Jancovici E, Privat Y, Benderitter T. Late-onset syringomas of the pper extremities associated with a carcinoid tumor. *Arch Dermatol* 1989;125:848-9.
  11. Garcia C, Kronic AL, Grichnik J, Viehman G, Clark RE. Multiple acral syringomata with uniform involvement of the hands and feet. *Cutis* 1997;59:213-4, 216.
  12. Patrizi A, Neri I, Marzaduri S, Varotti E, Passarini B. Syringoma: A review of twenty-nine cases. *Acta Derm Venereol* 1998;78:460-2.
  13. Muniesa C, Fortuño Y, Moreno A, González J. Papules on the dorsum of the fingers. *Actas Dermosifiliogr* 2008;99:812-3.