

features of cutaneous horn in 163 consecutive patients.⁵ The authors concluded that few dermoscopic features are significantly associated with underlying invasive SCC namely low height-to-base ratio, absence of terrace morphology and presence of base erythema and tenderness. They recorded lower height of the horn as compared to the diameter of the base in 67% cases of invasive squamous cell carcinoma. On the contrary, height of the horn was greater than base diameter in benign keratosis. All these features were seen in our patient. Terrace morphology is a feature presenting as structural horizontal contours on the side of the horn. On histopathology, it appears as ortho-hyperkeratosis with horizontal parallel lamellae of dead keratin. Base erythema is characterized by presence of red area within 5 mm of horn base that may be attributed to the increased perfusion. The close dermoscopic differentials include actinic keratosis, benign keratosis and SCC *in situ*. The differentiating dermoscopic features of cutaneous horn with underlying benign and malignant etiology have been tabulated in Table 1.

Thus, cutaneous horns could be a harbinger of malignancy as seen in our case. Though histopathology remains the diagnostic gold standard, dermoscopy can offer a clue to the underlying malignant etiology and affect the decision of therapeutic and diagnostic surgical excision.

Declaration of patient consent

The authors certify that they have obtained all appropriate patient consent.

Financial support and sponsorship

Nil.

Conflicts of interest

There are no conflicts of interest.

Archana Singal, Sonia Agrawal, Priyanka Gogoi¹

Departments of Dermatology and STD and ¹Pathology, University College of Medical Sciences and GTB Hospital (University of Delhi), New Delhi, India

Corresponding author:

Prof. Archana Singal,
Department of Dermatology and STD, University College
of Medical Sciences and GTB Hospital (University of Delhi),
New Delhi -110 095, India.
archanasingal@hotmail.com

References

1. Copcu E, Sivrioglu N, Culhaci N. Cutaneous horns: Are these lesions as innocent as they seem to be? *World J Surg Oncol* 2004;2:18.
2. Yu RC, Pryce DW, Macfarlane AW, Stewart TW. A histopathological study of 643 cutaneous horns. *Br J Dermatol* 1991;124:449-52.
3. Mantese SA, Diogo PM, Rocha A, Berbert AL, Ferreira AK, Ferreira TC. Cutaneous horn: A retrospective histopathological study of 222 cases. *An Bras Dermatol* 2010;85:157-63.
4. Shahi S, Bhandari TR, Pantha T. Verrucous carcinoma in a giant cutaneous horn: A case report and literature review. *Case Rep Otolaryngol* 2020;2020:7134789.
5. Pyne J, Sapkota D, Wong JC. Cutaneous horns: Clues to invasive squamous cell carcinoma being present in the horn base. *Dermatol Pract Concept* 2013;3:3-7.

Subcutaneous dirofilariasis in a Tunisian patient

Sir,

Human subcutaneous dirofilariasis is a rare helminthic infection caused by filarial worms of the genus *Dirofilaria* species, common in the southern USA. Its diagnosis is always challenging, especially in nonendemic regions, where most cases are diagnosed retrospectively.

A 19-year-old girl, a dog owner from East Central Tunisia, presented with two-month history of asymptomatic swelling of the lumbar area. There was no history of trauma, insect bite or foreign body. Examination revealed a single, soft, mobile, skin-colored subcutaneous nodule of 1 cm large size in the

right lumbar region, simulating lipoma. She had no other skin or systemic abnormalities. Hematological findings were within normal range, with no evidence of eosinophilia or hepatocellular dysfunction. An ultrasound scan showed a well-defined complex cystic structure containing an echogenic continuously moving structure, highly suggestive of a living worm [Figure 1]. By local excision under anesthesia, the encapsulated nodule was removed [Figure 2]. A thin, cylindrical, white worm, about 20 mm in length was found embedded in the subcutaneous fatty tissue. Parasitological examination identified a thick laminated cuticle with prominent longitudinal ridges, fitting with a filarial worm of the species *Dirofilaria repens* [Figure 3]. After the

How to cite this article: Idoudi S, Youssef M, Soua Y, Achour A, Babba H, Zili J. Subcutaneous dirofilariasis in a Tunisia patient. *Indian J Dermatol Venereol Leprol* 2021;87:390-2.

Received: November, 2019 Accepted: August, 2020 Published: April, 2021

DOI: 10.25259/IJDVL_995_19 PMID: *****

This is an open-access article distributed under the terms of the Creative Commons Attribution-Non Commercial-Share Alike 4.0 License, which allows others to remix, tweak, and build upon the work non-commercially, as long as the author is credited and the new creations are licensed under the identical terms.

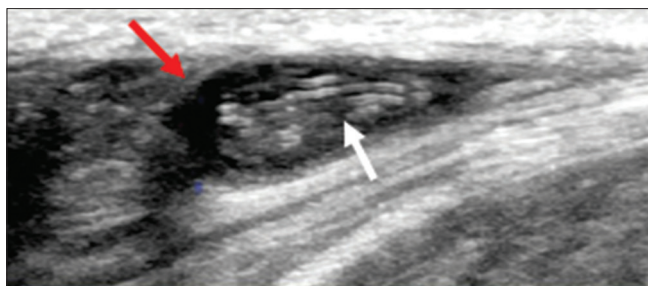


Figure 1: A well-defined complex cystic structure (red arrow) containing an echogenic moving structure highly suggestive of a living worm (white arrow)

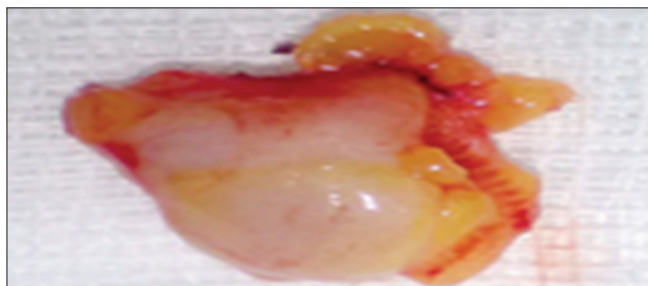


Figure 2: Excision of the worm with adjacent subcutaneous fat

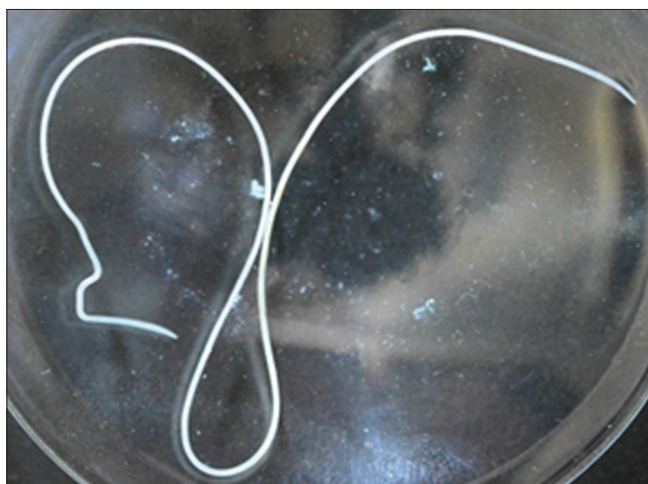

Figure 3: Thin, cylindrical, white worm at about 20 mm in length highly suggestive of *Dirofilaria repens*

surgery, the patient did not present any clinical evidence of recurrence within a follow-up period of three years.

Dirofilariasis is a zoonotic infection that accidentally affects humans. This emerging helminthic disease is caused by filarial nematodes of the genus *Dirofilaria*, which are transmitted by female mosquitoes of the *Culicidae* family, including *Aedes*, *Culex* and *Anopheles*¹. Two species of filarial nematodes are the cause of human dirofilariasis: *D. repens* and *D. immitis*. The latter is particularly endemic in tropical regions and responsible for pulmonary dirofilariasis, whereas *D. repens* causes subcutaneous nodules in Africa, Europe and Asia. We found only 16 previous reports of dirofilariasis to *D. repens* in Tunisia since 1990. Of these, six cases presented with subcutaneous nodules; four had conjunctival involvement in

the form of orbital cellulite-like lesion and conjunctival cyst); three presented in the form of breast lumps; two in the form of abscess-like nodule in the scrotum; and one had lesion in the labial area, resembling a sebaceous cyst-like tumor.²

Worldwide, 300 cases of visceral dirofilariasis and over 800 cases of cutaneous dirofilariasis are reported in literature. In the Mediterranean countries, particularly, asymptomatic infection in the dogs and the warm climate could explain the continuous spread of the disease.³ Clinically, cutaneous dirofilariasis caused by *D. repens* commonly appears as a solitary, erythematous, slowly growing subcutaneous nodule, localized to the exposed areas of the body. Its common differential diagnoses, include insect bites, infections, post inflammatory granuloma, sarcoidosis, and immune system mediated disorders.⁴ The peculiarity of this case is due to the localization of the lesion in the covered area and its presentation with no inflammatory reaction.

Diagnosis is based on the isolation of the worm in the cutaneous lesion. Further investigations including biological test are unnecessary, as peripheral blood eosinophilia is commonly missed. If found, it suggests circulation of the filaria in the blood, which is mainly observed in case of preexistent malignant neoplasia or immunodeficiency.⁵ Diagnosis could be confirmed by imaging, like high-resolution ultrasonography, which is considered as the imaging modality of choice to visualize the worm *in vivo*. Magnetic resonance imaging, though expensive, is more efficient in diagnosing the condition compared to ultrasonography.⁶ The serological diagnosis of species *Dirofilaria repens* and *Dirofilaria immitis* is currently possible, but remains nonspecific in practice. In our case, parasitological study of the isolated worm identified the species. Morphologically, cuticular ridges in *D. repens* are spaced at twice the height of each ridge, while *D. immitis* presents a smooth cuticle.⁷ There is no need for further screening of hidden infection because of its indolent nature. Surgical removal of the nodule or the worm presents the treatment of choice with no need to use anthelmintic treatment.

In conclusion, dirofilariasis is considered an emerging zoonotic disease mainly in the Mediterranean region and the eastern parts of the European continent. We do believe that it is not considered a threat to the public health system. We present this case to increase awareness about its cutaneous localization and suggest an approach for its diagnosis and its management.

Declaration of patient consent

The authors certify that they have obtained all appropriate patient consent.

Financial support and sponsorship

Nil.

Conflicts of interest

There are no conflicts of interest.

**Safa Idoudi, Monia Youssef, Yosra Soua,
Asma Achour¹, Hammouda Babba², Jameleddine Zili**

Departments of Dermatology, ¹Radiology and ²Parasitology, Fattouma Bourguiba University Hospital, Monastir, Tunisia

Corresponding author:

Dr. Safa Idoudi,
Department of Dermatology, Fattouma Bourguiba University Hospital,
Farhat Hached Street, Monastir 5000, Tunisia.
safaa.idoudi@gmail.com

References

1. Momčilović S, Gabrielli S, Golubović M, Tanha S, Miiłjan K, Sasa D, *et al.* Human dirofilariasis of buccal mucosa-First molecularly confirmed case and literature review. *Parasitol Int.* 2019;73:101960.
2. Ben Hassouna J, Jbir I, Mezghani B, El Amine O, Zemni I, Mrad K, *et al.* Dirofilariasis of the breast: Two new cases in Tunisia. *Med Sante Trop* 2015;25:327-30.
3. Genchi C, Kramer LH, Rivasi F. Dirofilarial infections in Europe. *Vector Borne Zoonotic Dis* 2011;11:1307-17.
4. Ashrafi K, Golchai J, Geranmayeh S. Human subcutaneous dirofilariasis due to *Dirofilaria* (*Nochtiella*) *repens*: Clinically suspected as Cutaneous Fascioliasis. *Iran J Public Health* 2010;39:105-9.
5. Kludkowska M, Pielok Ł, Frąckowiak K, Masny A, Gołąb E, Paul M. *Dirofilaria repens* infection as a cause of intensive peripheral microfilariemia in a polish patient: Process description and cases review. *Acta Parasitol* 2018;63:657-63.
6. Groell R, Ranner G, Uggowitz MM, Braun H. Orbital dirofilariasis: MR findings. *AJNR Am J Neuroradiol* 1999;20:285-6.
7. Orihel TC, Eberhard ML. Zoonotic filariasis. *Clin Microbiol Rev* 1998;11:366-81.