

# Fractional CO<sub>2</sub> laser with topical 1% terbinafine cream versus oral itraconazole in the management of onychomycosis: A randomized controlled trial

Eeshaan Ranjan, Sandeep Arora<sup>1</sup>, Neha Sharma<sup>2</sup>

Department of Dermatology, Military Hospital, Jammu, Jammu and Kashmir, India, <sup>1</sup>Department of Dermatology, Base Hospital, New Delhi, Delhi, India, <sup>2</sup>Department of Community Medicine & School of Public Health, PGIMER, Chandigarh, India

## Abstract

**Background:** Onychomycosis accounts for 20–40% of all nail disorders. It is difficult to cure with resistance to anti-fungal drugs, their side effects and drug interactions limiting treatment options. Itraconazole is a widely accepted oral medication used for onychomycosis while fractional CO<sub>2</sub> laser along with a topical anti-fungal has shown promising results for nail plate clearance in onychomycosis.

**Aim:** To compare the efficacy of fractional CO<sub>2</sub> laser with 1% terbinafine cream versus itraconazole in the management of onychomycosis.

**Methods:** A prospective, randomised, single-centre, two-arm, parallel-group interventional study was conducted at Command Hospital Air Force, Bangalore. Onychomycosis cases confirmed by KOH mount/culture-positive were included. Patients were randomly divided into two groups. Group A received 4 sessions of fractional CO<sub>2</sub> laser every fourth week with twice-daily application of 1% terbinafine cream; Group B received one-week pulse therapy with capsule itraconazole once every four-week for three pulses. The response was assessed by Onychomycosis Severity Index, a validated onychomycosis assessment scale, at baseline and at six months.

**Results:** Group A had 50 patients with a total of 98 nails. Clinical improvement was seen in 83/98 (84.7%) nails. The average reduction in Onychomycosis Severity Index was 8.65 ( $P < 0.05$ ). Group B had 50 patients with a total of 136 nails. Clinical improvement was seen in 104/136 (76.5%) nails. The average reduction in Onychomycosis Severity Index was 7.37 ( $P < 0.05$ ). Both groups showed statistically significant improvement measured by 'Reduction in Onychomycosis Severity Index' at six months; however, there was no significant difference between the two arms.

**Limitations:** The main limitations of the study are the small sample size and lack of long-term follow-up to assess recurrence of infection.

**Conclusion:** Fractional CO<sub>2</sub> laser with 1% terbinafine cream is an effective and safe method for inducing nail clearance in onychomycosis and has efficacy similar to itraconazole pulse therapy.

**Keywords:** Fractional CO<sub>2</sub> laser, itraconazole, onychomycosis, terbinafine

## Plain Language Summary

Onychomycosis is the fungal infection of nail. Reported incidence is 0.5–5 percent in India. Itraconazole is an antifungal medicine used for treatment. Side effects like headache, diarrhoea, liver abnormalities and contraindication like heart failure limit its use. Recent studies have found Fractional carbon-dioxide (FCO<sub>2</sub>) laser with anti-fungal cream to be effective. We conducted a study in a hospital in India to compare FCO<sub>2</sub> laser with 1% terbinafine cream versus itraconazole in management of onychomycosis. Patients were distributed into 2 groups of 50 each. First group was treated with FCO<sub>2</sub> laser, 4-sessions at 4-week intervals alongwith daily application of terbinafine. Second group was treated with Itraconazole 200 mg twice-daily, one-week per month for three months. Severity scores of nail infection and photographs were documented at baseline and at

**How to cite this article:** Ranjan E, Arora S, Sharma N. Fractional CO<sub>2</sub> laser with topical 1% terbinafine cream versus oral itraconazole in the management of onychomycosis: A randomized controlled trial. *Indian J Dermatol Venereol Leprol* 2023;89:47–53.

**Corresponding author:** Dr. Eeshaan Ranjan, Department of Dermatology, Military Hospital Jammu, Satwari Cantt, Jammu 180003, Jammu and Kashmir, India. eeshaan.ranjan@gmail.com

**Received:** January, 2021 **Accepted:** February, 2022 **Epub Ahead of Print:** April, 2022 **Published:** January, 2023

**DOI:** 10.25259/IJDVL\_98\_2021 **PMID:** 35389015

This is an open-access article distributed under the terms of the Creative Commons Attribution-Non Commercial-Share Alike 4.0 License, which allows others to remix, transform, and build upon the work non-commercially, as long as the author is credited and the new creations are licensed under the identical terms.

six months. Severity scores in both groups were similar at baseline and at 6 months, showing similar response with treatment. Patient satisfaction and compliance was better in first group, no side effects were observed. The study shows that FCO<sub>2</sub> laser with 1% terbinafine cream is equally effective in onychomycosis. It can be used in patients where itraconazole is contraindicated as it has no significant side effects and drug interactions.

## Introduction

Onychomycosis describes the fungal infection of the nail unit caused by dermatophytes, yeasts, or non-dermatophyte moulds.<sup>1</sup> Various workers have reported the incidence between 0.5 and 5% in the general population in India.<sup>2,3</sup> It can have significant negative effect on patients' quality of life and occupational functioning.<sup>4</sup> The most frequently implicated causative agents in onychomycosis are dermatophytes. Previously regarded as contaminants, yeasts and some moulds are now increasingly recognised as pathogens in fingernail infections.<sup>5</sup>

Itraconazole, a triazole antifungal, has the broadest spectrum of antifungal activity against dermatophytes, candida, and non-dermatophyte moulds. Intermittent therapy is effective and results in higher plasma concentrations, lower cumulative dose as compared to continuous therapy<sup>6</sup> and results in equal mycological and higher clinical cure when compared to the continuous regimen.<sup>7</sup> The common adverse effects include headache, nausea and gastrointestinal upset as well as asymptomatic liver function abnormalities. Hepatitis tends to occur with continuous therapy usually after four weeks. It is contraindicated in patients with congestive cardiac failure due to the increased risk of negative inotropic effects.<sup>8</sup>

Laser therapy for onychomycosis is a newer treatment modality. Using the principle of selective photothermolysis, lasers have a photothermal effect on fungi, with chitin augmenting the heating effect.<sup>9</sup> More recent trials have explored fractional carbon dioxide lasers in combination with topical treatment and found it to be a viable option for management of onychomycosis.<sup>10-15</sup>

In this context, we conducted a randomised controlled trial to compare the efficacy of a combination of fractional carbon dioxide laser with topical 1% terbinafine cream versus itraconazole in the management of onychomycosis and to find the possible superiority of one treatment over other.

## Methods

A prospective, randomised, interventional parallel-arm study was conducted at the dermatology department of Command Hospital Air Force, Bangalore from December 2017 to May 2019 after institutional ethical clearance and informed patient consent. All consecutive patients over the age of 18 years of either gender presenting with one or more toenails and/or fingernails onychomycosis were included. Diagnosis of onychomycosis was confirmed on demonstration of fungal hyphae on direct microscopy and fungal culture. Pregnant and lactating women, cases with negative KOH mount for fungal hyphae and negative fungal culture, persons on systemic or

topical anti-fungals in the past three months and those with nail disorders due to psoriasis, chronic eczema, lichen planus, bacterial infections, subungual hematoma were excluded.

All the cases were assessed clinically, and objectively scored using "Onychomycosis Severity Index"<sup>16</sup> [Table 1] and the pattern of involvement was determined as distal lateral subungual onychomycosis, proximal subungual onychomycosis, white superficial onychomycosis, total dystrophic onychomycosis. The patients were randomised through a draw of cards and allocated to either study arm. One study arm received treatment with fractional carbon dioxide laser once in four weeks along with the topical application of 1% terbinafine cream and the other was administered capsule itraconazole.

For topical anaesthesia before laser therapy, topical anaesthesia (lidocaine 7% w/w + tetracaine 7% w/w) was applied under occlusion on the infected nail and periungual area for 45 minutes. All the infected nails were treated with fractional carbon dioxide laser using pulse energy of 110 mJ, the energy density of 256 spots/cm<sup>2</sup>, a pulse interval of 0.5 mm, pulse duration of 0.1 milliseconds, and

**Table 1: Calculation of OSI<sup>16</sup>**

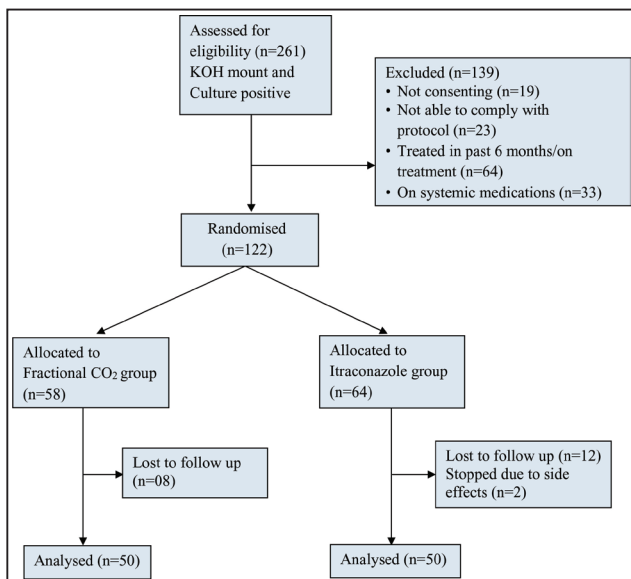
Area of involvement	
Affected nail percentage	Number of points
0	0
1-10	1
11-25	2
26-50	3
51-75	4
76-100	5
<b>Proximity of disease to matrix</b>	
Amount of involvement from distal edge	Number of points
<1/4	1
1/4-1/2	2
>1/2-3/4	3
>3/4	4
Matrix involvement	5
<b>Presence of dermatophytoma or subungual hyperkeratosis &gt;2 mm</b>	
Present	Number of points
No	0
Yes	10
Final score (OSI): (Score for area of involvement) × (score for proximity of disease to matrix) + 10 (if dermatophytoma or subungual hyperkeratosis >2 mm)	

a rectangular spot size of 2–10 mm length and 0.6–5 mm breadth. three passes were given in static operating mode over the affected area including 1 mm normal-appearing nail around them. Altogether four sessions of laser therapy were given, each at four-week intervals. Topical 1% terbinafine cream was then advised to be applied to the affected nails twice daily. In the other arm, itraconazole 200 mg twice daily was administered for one week per month for three months. Follow-up was performed at each visit at four-week intervals with an assessment of clinical improvement using Onychomycosis Severity Index score and photography. Analysis of the data was carried out six months after the institution of therapy. The data was maintained prospectively in a computerized database. Side effects, due to fractional carbon dioxide laser-like, erythema, itching or burning or oral itraconazole were monitored and followed up every week for 12 weeks. Liver function tests were done every month in patients taking itraconazole.

Data were tabulated into an excel sheet and analysed using SPSS version 16.0. The data were expressed in means and proportions. Repeated measurement analysis of variance was used to evaluate the changes in the Onychomycosis Severity Index score before and after treatments and the difference between the groups was evaluated using an independent *t*-test. A *P* value of <0.05 was taken as statistically significant.

**Results**

A total of 261 patients of onychomycosis were assessed for eligibility out of which 122 patients satisfying the above-mentioned criteria were identified and included in the study [Figure 1]. The data of 100 patients was analysed finally after excluding the patients lost to follow up.



**Figure 1:** CONSORT Statement of the study

**Table 2: Clinico-demographic distribution between two arms is shown**

	Fractional CO <sub>2</sub> laser	Itraconazole	Total*
<b>Age in years</b>			
≤30	8 (16%)	13 (26%)	21 (21%)
31–40	10 (20%)	8 (16%)	18 (18%)
41–50	13 (26%)	10 (20%)	23 (23%)
51–60	11 (22%)	16 (32%)	27 (27%)
>60	8 (16%)	3 (6%)	11 (11%)
Total	50 (100)	50 (100)	100 (100)
<b>Gender</b>			
Females	22 (44%)	30 (60%)	52 (52%)
Males	28 (56%)	20 (40%)	48 (48%)
Total	50 (100)	50 (100)	100 (100%)
<b>Type</b>			
Toenail	77 (78.6%)	101 (74.3%)	178 (76%)
Fingernail	21 (21.4%)	35 (25.7%)	56 (24%)
Total	98 (100)	136 (100)	234 (100%)
<b>Pattern of onychomycosis</b>			
DLSO	68 (69.4%)	109 (80.1%)	177 (75.6)
TDO	23 (23.5%)	17 (12.5%)	40 (17.1)
WSO	7 (7.1%)	10 (7.4%)	17 (7.3)
Total	98 (100%)	136 (100%)	234 (100%)

\*Figures in parenthesis indicate column percentage, DLSO: Distal lateral subungual onychomycosis, OSI: Onychomycosis Severity Index, PSO: Proximal subungual onychomycosis, WSO: White superficial onychomycosis, TDO: Total dystrophic onychomycosis

The clinico-demographic distribution between two arms is shown in [Table 2]. Both groups were matched for gender and age [Table 2]. The total number of nails studied in the fractional carbon dioxide laser arm was 98 among 50 patients and in the itraconazole arm were 136 among 50 patients. Most of the nails involved in both groups were toenails [Table 2]. The most common type of onychomycosis found in our study was distal lateral subungual onychomycosis, followed by total dystrophic onychomycosis type. White superficial onychomycosis type of onychomycosis was found to be the least common in both arms [Table 2].

At the end of the study, clinical improvement was seen in 83 nails out of 98 nails (84.7%) in the fractional carbon dioxide arm. In the itraconazole arm, clinical response was seen in 104 nails out of 136 nails (76.5%). The mean of Onychomycosis Severity Index scores in the itraconazole group was lower as compared to the fractional carbon dioxide group at baseline and higher as compared to fractional carbon dioxide after six months’ follow-up. However, the difference in the means among the patients in both the groups was not statistically significant [Table 3]. Also, improvement in terms of decrease in Onychomycosis Severity Index was higher in fractional carbon dioxide arm

**Table 3: Assessment of OSI before and after the treatment in both arms**

	Fractional CO <sub>2</sub> laser (Mean ± SD)	Itraconazole (Mean ± SD)	P-value
<b>All nails</b>			
OSI before treatment	17.06 ± 9.66	16.92 ± 9.59	0.911
OSI at 6 months	8.40 ± 9.76	9.55 ± 9.79	0.378
Mean reduction in OSI with treatment	8.65 ± 7.09	7.36 ± 6.65	0.157
<b>Toenail</b>			
OSI before treatment	18.13 ± 9.15	18.45 ± 9.10	0.813
OSI at 6 months	8.8 ± 9.41	10.56 ± 9.70	0.22
Mean reduction in OSI with treatment	9.32 ± 7.12	7.89 ± 6.09	0.15
<b>Fingernail</b>			
OSI before treatment	13.14 ± 11	12.48 ± 9.73	0.814
OSI at 6 months	6.95 ± 11	6.63 ± 9.59	0.908
Mean reduction in OSI with treatment	6.19 ± 6.58	5.85 ± 7.96	0.872
<b>DLSO</b>			
OSI before treatment	14.35 ± 8.87	15.52 ± 9.32	0.409
OSI at 6 months	5.30 ± 7.21	8.76 ± 8.61	0.650
Mean reduction in OSI with treatment	9.05 ± 7.11	6.76 ± 6.08	0.243
<b>TDO</b>			
OSI before treatment	26.78 ± 5.31	26.29 ± 6.63	0.797
OSI at 6 months	19.21 ± 9.67	18.58 ± 13.43	0.864
Mean reduction in OSI with treatment	7.57 ± 7.34	7.71 ± 8.68	0.956
<b>WSO</b>			
OSI before treatment	11.42 ± 6.60	16.20 ± 8.29	0.22
OSI at 6 months	3.0 ± 5.19	2.80 ± 3.67	0.92
Mean reduction in OSI with treatment	8.42 ± 6.52	13.40 ± 6.36	0.13

as compared to itraconazole arm but it was not found to be statistically significant ( $P$ -value 0.157) [Table 3]. Among the toenails of study subjects of fractional carbon dioxide and itraconazole groups, though the means of Onychomycosis Severity Index scores were higher in the itraconazole group compared to the fractional carbon dioxide group, at baseline and after six months follow-up, the difference in the means among the patients in both the groups were not statistically significant. Also, improvement in terms of decrease in Onychomycosis Severity Index was higher in fractional carbon dioxide arm but it was not found to be statistically significant [Table 3].

Similarly, in the fingernails of study subjects of fractional carbon dioxide and itraconazole groups, the means of Onychomycosis Severity Index scores were lower in the

itraconazole group compared to the fractional carbon dioxide group, at baseline and after six months follow-up, the difference in the means among the patients in both the groups were not statistically significant ( $P > 0.05$ ). However, improvement in terms of decrease in Onychomycosis Severity Index was higher in the fractional carbon dioxide arm but it was not found to be statistically significant [Table 3].

Also, all types of onychomycosis responded to fractional carbon dioxide with topical terbinafine, as well as itraconazole as assessed by a decrease in Onychomycosis Severity Index. The response was found to be statistically significant in both groups [Table 3].

## Discussion

Onychomycosis is known to be difficult to treat. Reported cure rates for combination treatment with both topical and systemic antifungals range from 59.2 to 88.2%.<sup>17</sup> Antifungal drugs are contraindicated in active liver, renal diseases and long-term treatment leads to poor patient compliance. This has led to the need for non-pharmacologic treatment modalities for rapid treatment of nail infection. Laser therapy for onychomycosis, although described, is yet to be recognised as a treatment modality. It is thought that the fungal elements get decomposed by heat because temperatures exceeding 50°C lead directly to thermal killing.<sup>18</sup> Further fungicidal effect is achieved through the absorption of energy by fungal chromophores like xanthomegnin, chitin and melanin.

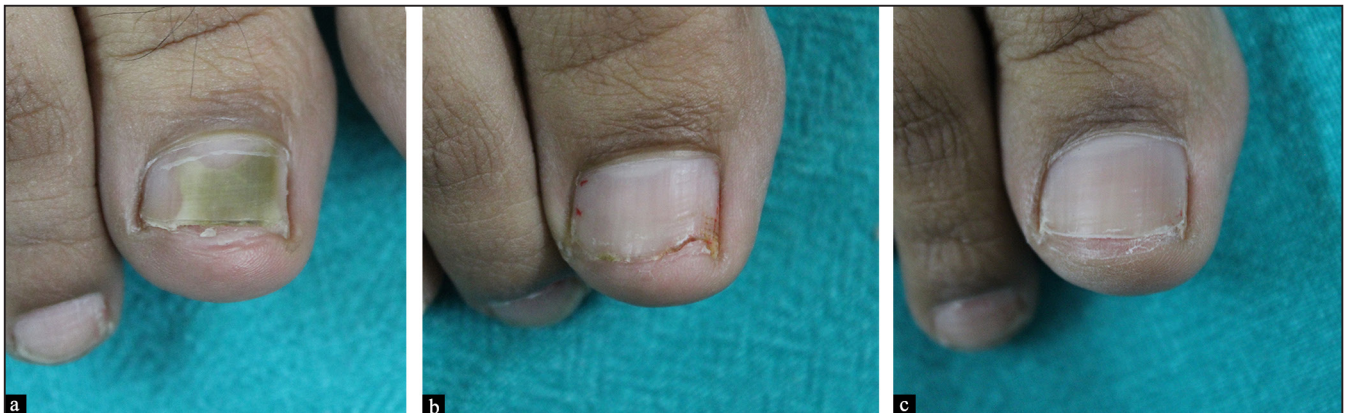Bhatta *et al.*<sup>11</sup> Lim *et al.*<sup>13</sup> and Arora *et al.*<sup>14</sup> also conducted a clinical trial using multiple sessions of fractional carbon dioxide laser along with a topical antifungal agent. Treatment of onychomycosis by urea occlusion prior to a single session of fractional carbon dioxide laser has also been reported.<sup>19</sup> Lim *et al.*<sup>13</sup> reported that 71% of participants (17 participants) had full or >60% normal-appearing nails at three months after the last treatment. Bhatta *et al.*<sup>11</sup> reported that 73.32% of participants (55 participants) had fully or >60% normal-appearing nails. However, a validated objective score was not used for assessment in these studies. Arora *et al.*<sup>14</sup> also used Onychomycosis Severity Index for assessment of onychomycosis and reported improvement in 88% of nails (44 nails) with a significant reduction in Onychomycosis Severity Index at the end of six months. In the present study, the efficacy of fractional carbon dioxide laser along with 1% terbinafine cream was compared with capsule itraconazole among 100 cases of onychomycosis. Similar to the previous reported studies, we found that fractional carbon dioxide laser along with 1% terbinafine cream was effective in 84.7% of nails. Not only it was effective in achieving nail plate clearance in onychomycosis, but it also had similar efficacy to oral itraconazole.

## Clinico-epidemiologic characteristics

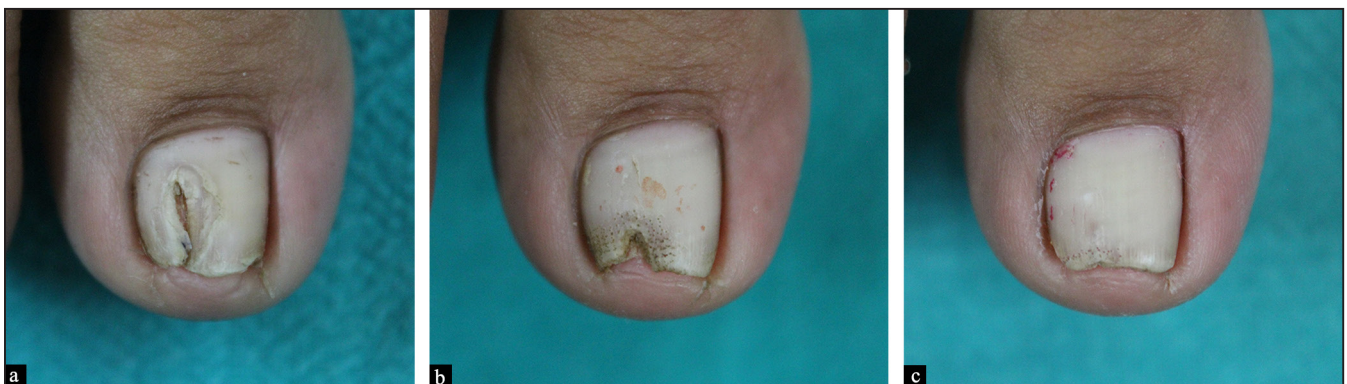Gender and age distribution among the two study arms was found to be similar to previous studies<sup>11,12</sup> [Table 2]. Most

**Table 4: Comparison table of past studies**

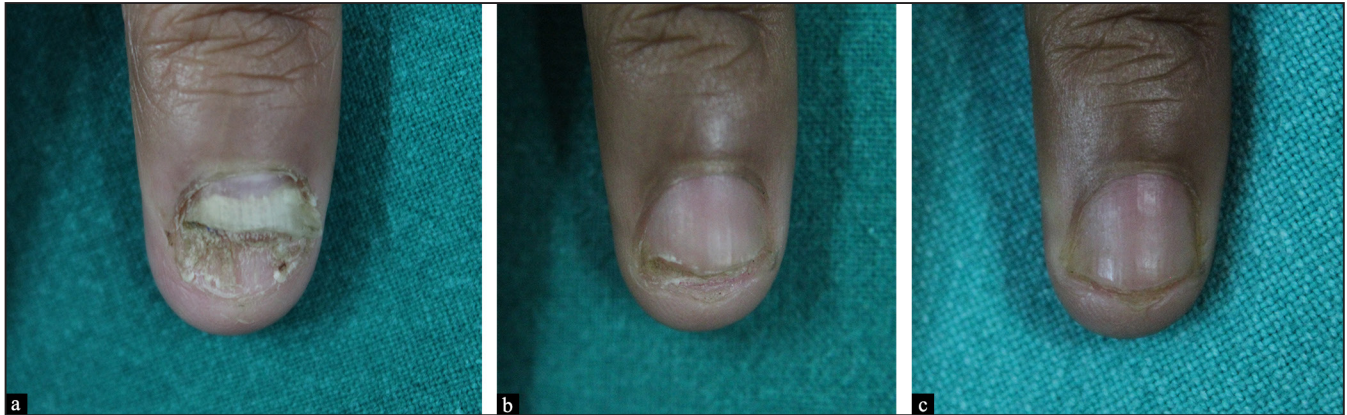
Author	No. of patients	Treatment protocol	Assessment tool	Result
Zhou <i>et al.</i> <sup>10</sup>	29 (115 nails)	Fractional CO <sub>2</sub> laser and 1% luliconazole cream for 6 months	12 sessions at 2-week intervals Follow up at 6 months	Clinical efficacy rate and mycological clearance rate 92% showed response 34% complete response 8% no response
Bhatta <i>et al.</i> <sup>11</sup>	75 (356 nails)	Fractional CO <sub>2</sub> laser and 1% terbinafine cream for 3 months	3 sessions at 4-week intervals Follow up at 6 months	Scoring Clinical Index for Onychomycosis 80% showed response 33% complete response 20% no response
Shi <i>et al.</i> <sup>12</sup>	30 (124 nails)	Fractional CO <sub>2</sub> laser and 1% terbinafine cream for 6 months	12 sessions at 2-week intervals Follow up at 6 months	Clinical efficacy rate and mycological clearance rate 68.5% showed response
Lim <i>et al.</i> <sup>13</sup>	24 (119 nails)	Fractional CO <sub>2</sub> laser and amorolfine cream for 3 months	3 sessions at 4-week intervals Follow up at 6 months	Clinical efficacy rate (based on area of involvement) 92% showed response 50% complete response 8% no response
Arora <i>et al.</i> <sup>14</sup>	26 (50 nails)	Fractional CO <sub>2</sub> laser and 1% terbinafine cream for 6 months	3 sessions at 4-week intervals Follow up at 6 months	Onychomycosis Severity Index 88% showed response
Zaki <i>et al.</i> <sup>15</sup>	40	Fractional CO <sub>2</sub> laser and topical tioconazole 28% solution for 16 weeks	Five sessions at 3-weeks interval Follow up at 4 months	Scoring Clinical Index for Onychomycosis 95% showed response



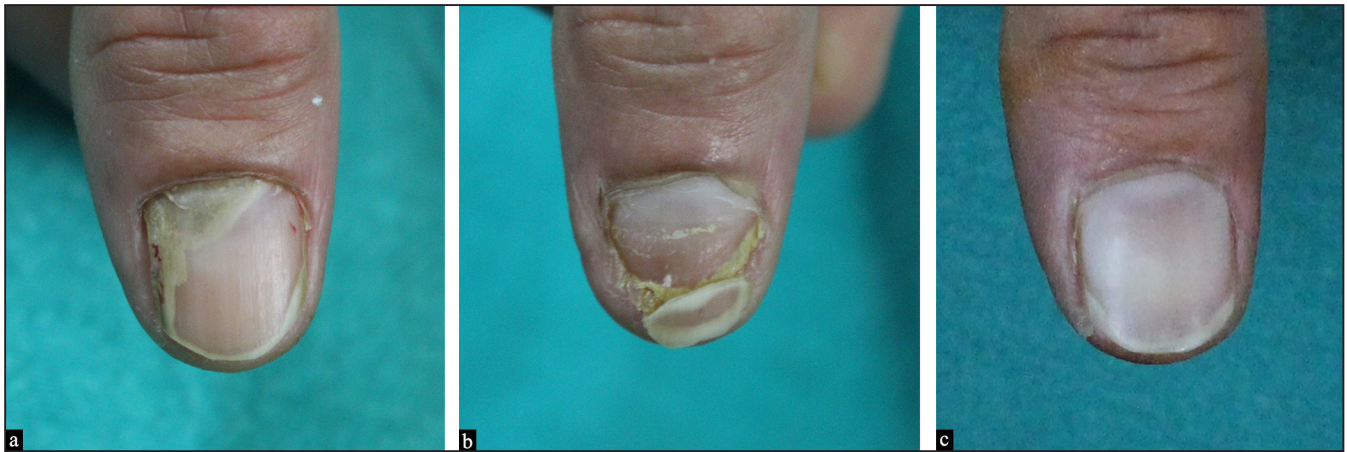**Figure 2:** Right great toenail with onychomycosis treated with fractional CO<sub>2</sub> laser combined with 1% terbinafine cream (a) before treatment (b) after 4 months (c) at 6 months



**Figure 3:** Right great toenail with onychomycosis treated with fractional CO<sub>2</sub> laser combined with 1% terbinafine cream (a) before treatment (b) after 4 months (c) at 6 months



**Figure 4:** Fingernail with onychomycosis treated with capsule itraconazole (a) before treatment (b) after 4 months (c) at 6 months



**Figure 5:** Right thumbnail with onychomycosis treated with capsule itraconazole (a) before treatment (b) after 4 months (c) at 6 months

of the nails involved in both groups were toenails [Table 2]. This was found to be similar to studies by Bhatta *et al.*<sup>11</sup> and Zhou *et al.*<sup>10</sup>

#### Types of onychomycosis

Most common type of onychomycosis found in our study was distal lateral subungual onychomycosis, 69.4% and 80.1% in fractional carbon dioxide laser arm and itraconazole arm, respectively. Lim *et al.*<sup>13</sup> also found distal lateral subungual onychomycosis and total dystrophic onychomycosis to be the most common type of onychomycosis in their study.

#### Onychomycosis Severity Index

Mean Onychomycosis Severity Index scores in fractional carbon dioxide group and itraconazole group at baseline were  $17.06 \pm 9.66$  and  $16.92 \pm 9.59$ , respectively. This is similar to a study by Zhou *et al.*<sup>10</sup> who also used Onychomycosis Severity Index as a measure of severity of onychomycosis and found a baseline Onychomycosis

Severity Index of  $18.0 \pm 11.5$  and  $16.6 \pm 10.6$  in two study groups. Mean Onychomycosis Severity Index scores in the fractional carbon dioxide group and itraconazole group at six months after treatment initiation were  $8.40 \pm 9.76$  and  $9.55 \pm 9.79$ , respectively. Significant improvement in terms of reduction in the Onychomycosis Severity Index was found in both arms. It was higher in the fractional carbon dioxide arm ( $8.65 \pm 7.09$ ) as compared to the itraconazole arm ( $7.36 \pm 6.65$ ). However, this was not found to be statistically significant with *P*-value of 0.157 (*P* > 0.05) [Table 3]. Our study showed considerable improvement post-treatment in both groups when compared with the baseline. However, the difference between the two groups was statistically insignificant.

A few patients experienced mild pain during laser treatment. There was no bleeding or oozing during or after treatment. No adverse effects were reported during the observation period. Similar effects were seen in previous

studies by Zhou *et al.*<sup>10</sup> and Bhatta *et al.*<sup>11</sup> Two patients in the itraconazole arm had side effects of nausea and diarrhoea and dropped out of the study.

#### Limitations

The major limitations of our study were the small sample size and unavailability of long-term follow-up data. The main limitation of fractional carbon dioxide laser is the high cost and low availability of treatment as compared to itraconazole.

#### Conclusion

Fractional carbon dioxide laser along with 1% terbinafine cream and capsule itraconazole are both significantly effective in the management of onychomycosis. The efficacy of fractional carbon dioxide laser along with 1% terbinafine cream is comparable to oral itraconazole alone, with no statistically significant difference. However, patients treated with fractional carbon dioxide laser along with 1% terbinafine cream did not show any adverse effects and had better satisfaction and compliance as compared to the itraconazole group. Hence, fractional carbon dioxide laser along with 1% terbinafine cream seems to be a promising therapy that can lead to results similar to the gold standard agent itraconazole with no significant and serious adverse effects.

#### Declaration of patient consent

The authors certify that they have obtained all appropriate patient consent.

#### Financial support and sponsorship

Nil.

#### Conflicts of interest

There are no conflicts of interest.

#### References

- Weitzman I, Summerbell RC. The dermatophytes. *Clin Microbiol Rev* 1995;8:240–59.
- Karmakar S, Kalla G, Joshi KR, Karmakar S. Dermatophytoses in a desert district of western Rajasthan. *Indian J Dermatol Venereol Leprol* 1995;61:280–3.
- Sobhanadri C, Rao DT, Babu KS. Clinical and mycological study of superficial fungal infections at Government General Hospital: Guntur and their response to treatment with Hamycin, Dermostatin and Dermamycin. *Indian J Dermatol Venereol* 1970;36:209–14.
- Elewski BE. Onychomycosis: Pathogenesis, diagnosis, and management. *Clin Microbiol Rev* 1998;11:415–29.
- Midgley G, Moore MK, Cook JC, Phan QG. Mycology of nail disorders. *J Am Acad Dermatol* 1994;31:S68–74.
- Gupta AK, Ryder JE. The use of oral antifungal agents to treat onychomycosis. *Dermatol Clin* 2003;21:469–79.
- Havu V, Brandt H, Heikkilä H, Hollmen A, Oksman R, Rantanen T, *et al.* A double-blind, randomized study comparing itraconazole pulse therapy with continuous dosing for the treatment of toe-nail onychomycosis. *Br J Dermatol* 1997;136:230–4.
- Cathcart S, Cantrell W, Elewski BE. Onychomycosis and diabetes. *J Eur Acad Dermatol Venereol* 2009;23:1119–22.
- Lipner SR, Scher RK. Onychomycosis: Treatment and prevention of recurrence. *J Am Acad Dermatol* 2019;80:853–67.
- Zhou BR, Lu Y, Permatasari F, Huang H, Li J, Liu J, *et al.* The efficacy of fractional carbon dioxide (CO<sub>2</sub>) laser combined with luliconazole 1% cream for the treatment of onychomycosis: A randomized, controlled trial. *Medicine (Baltimore)* 2016;95:e5141.
- Bhatta AK, Keyal U, Huang X, Zhao JJ. Fractional carbon dioxide (CO<sub>2</sub>) laser-assisted topical therapy for the treatment of onychomycosis with carbon dioxide. *J Am Acad Dermatol* 2016;74:916–23.
- Shi J, Li J, Huang H, Permatasari F, Liu J, Xu Y, *et al.* The efficacy of fractional carbon dioxide (CO<sub>2</sub>) laser combined with terbinafine hydrochloride 1% cream for the treatment of onychomycosis. *J Cosmet Laser Ther* 2017;19:353–9.
- Lim E-H, Kim H, Park Y-O, Lee Y, Seo Y-J, Kim C-D, *et al.* Toenail onychomycosis treated with a fractional laser and topical antifungal cream carbon dioxide. *J Am Acad Dermatol* 2014;70:918–23.
- Arora S, Lal S, Janney MS, Ranjan E, Donaparthi N, Dabas R. Fractional CO<sub>2</sub> laser in the management of onychomycosis. *J Mar Med Soc* 2020;22:50–3.
- Zaki AM, Abdo HM, Ebadah MA, Ibrahim SM. Fractional CO<sub>2</sub> laser plus topical antifungal versus fractional CO<sub>2</sub> laser versus topical antifungal in the treatment of onychomycosis. *Dermatol Ther* 2020;33(1): e13155.
- Carney C. A new classification system for grading the severity of onychomycosis: Onychomycosis Severity Index. *Arch Dermatol* 2011;147:1277–82.
- Baran R, Sigurgeirsson B, de Berker D, Kaufmann R, Lecha M, Faergemann J, *et al.* A multicentre, randomized, controlled study of the efficacy, safety and cost-effectiveness of a combination therapy with amorolfine nail lacquer and oral terbinafine compared with oral terbinafine alone for the treatment of onychomycosis with matrix involvement. *Br J Dermatol* 2007;157:149–57.
- Demirseren DD. New therapeutic options in the management of superficial fungal diseases. *Dermatol Ther* 2019:e12855.
- Arora S, Ranjan E. Urea occlusion prior to single session fractional CO<sub>2</sub> laser as a treatment in onychomycosis. *Indian J Dermatol Venereol Leprol* 2020;86:331–33.