

WHAT IS YOUR DIAGNOSIS ?

A 12 year old male patient presented with scaly patches on the body noticed since infancy. He was born to consanguinous parents and one of 4 siblings. There was no family history of similar problem. Lesions were mainly asymptomatic.

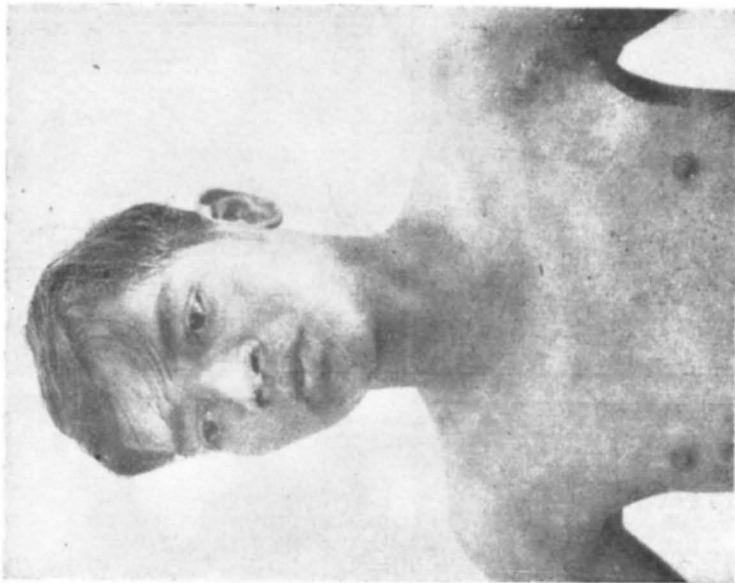

Fig. 1

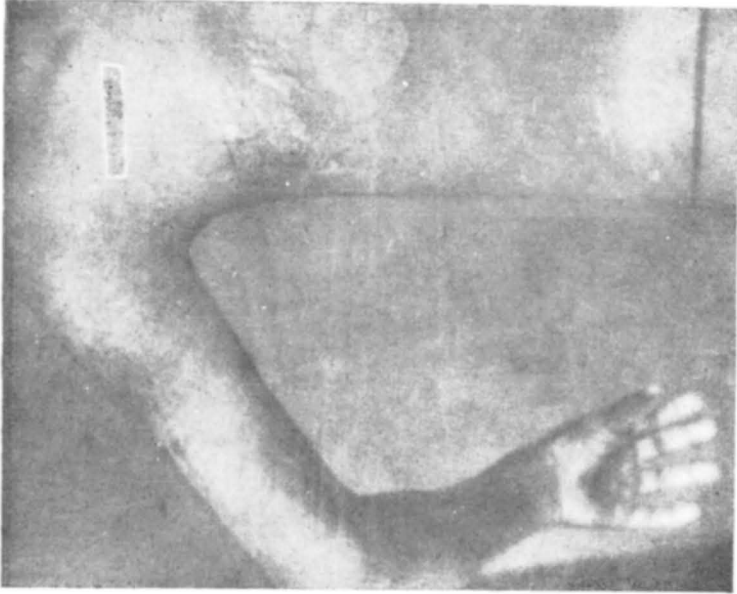


Fig. 2

Examination showed multiple areas of scaling with roughly polycyclic borders in the axillae, neck and scapular regions. Lesions were rather symmetrically distributed. Differential diagnosis :

1. Flexural psoriasis
2. Ichthyosis linearis circumflexa
3. Lamellar ichthyosis.



The early onset of the disease with a negative family history suggested a recessively inherited dermatoses. The peculiar polycyclic borders which were raised and scaly were consistent with a diagnosis of ichthyosis linearis circumflexa. No hair abnormalities were detected and no eye lesions.

Final diagnosis : Ichthyosis linearis circumflexa