

Indian Journal of Dermatology, Venereology & Leprology

Journal indexed with SCI-E, PubMed, and EMBASE

Vol 74 | Issue 2 | Mar-Apr 2008

C O N T E N T S

EDITORIAL

Management of autoimmune urticaria

Arun C. Inamadar, Aparna Palit 89

VIEW POINT

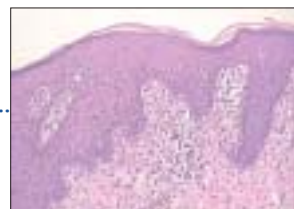Cosmetic dermatology versus cosmetology: A misnomer in need of urgent correction

Shyam B. Verma, Zoe D. Draelos 92

REVIEW ARTICLE

Psoriasiform dermatoses

Virendra N. Sehgal, Sunil Dogra, Govind Srivastava, Ashok K. Aggarwal 94



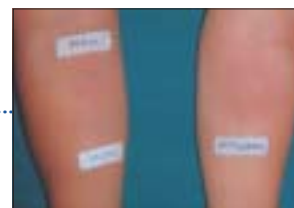ORIGINAL ARTICLES

A study of allergen-specific IgE antibodies in Indian patients of atopic dermatitis

V. K. Somani 100

Chronic idiopathic urticaria: Comparison of clinical features with positive autologous serum skin test

George Mamatha, C. Balachandran, Prabhu Smitha 105



Autologous serum therapy in chronic urticaria: Old wine in a new bottle

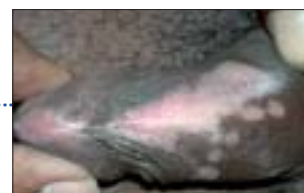A. K. Bajaj, Abir Saraswat, Amitabh Upadhyay, Rajetha Damisetty, Sandipan Dhar 109

Use of patch testing for identifying allergen causing chronic urticaria

Ashimav Deb Sharma 114

Vitiligoid lichen sclerosus: A reappraisal

Venkat Ratnam Attali, Sasi Kiran Attali 118



BRIEF REPORTS

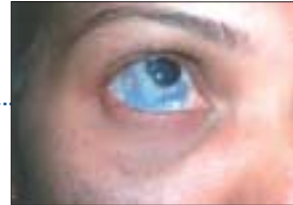Activated charcoal and baking soda to reduce odor associated with extensive blistering disorders

Arun Chakravarthi, C. R. Srinivas, Anil C. Mathew 122



Nevus of Ota: A series of 15 cases

Shanmuga Sekar, Maria Kuruvila, Harsha S. Pai 125



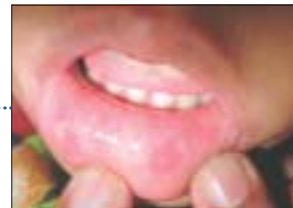Premature ovarian failure due to cyclophosphamide: A report of four cases in dermatology practice

Vikrant A. Saoji 128

CASE REPORTS

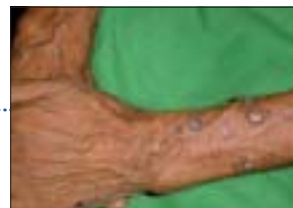Hand, foot and mouth disease in Nagpur

Vikrant A. Saoji 133



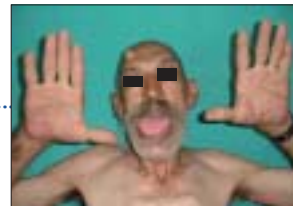Non-familial multiple keratoacanthomas in a 70 year-old long-term non-progressor HIV-seropositive man

Hemanta Kumar Kar, Sunil T. Sabhnani, R. K. Gautam, P. K. Sharma, Kalpana Solanki, Meenakshi Bhardwaj 136



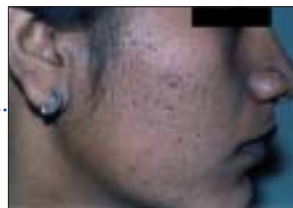Late onset isotretinoin resistant acne conglobata in a patient with acromegaly

Kapil Jain, V. K. Jain, Kamal Aggarwal, Anu Bansal 139



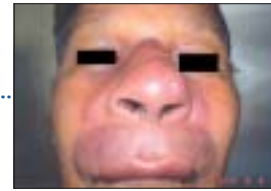Familial dyskeratotic comedones

M. Sendhil Kumaran, Divya Appachu, Elizabeth Jayaseelan 142



Nasal NK/T cell lymphoma presenting as a lethal midline granuloma

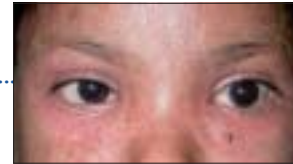Vandana Mehta, C. Balachandran, Sudha Bhat, V. Geetha, Donald Fernandes



145

Childhood sclerodermatomyositis with generalized morphea

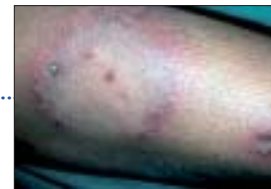Girishkumar R. Ambade, Rachita S. Dhurat, Nitin Lade, Hemangi R. Jerajani.....



148

Subcutaneous panniculitis-like T-cell cutaneous lymphoma

Avninder Singh, Joginder Kumar, Sujala Kapur, V. Ramesh.....



151

LETTERS TO EDITOR

Using a submersible pump to clean large areas of the body with antiseptics

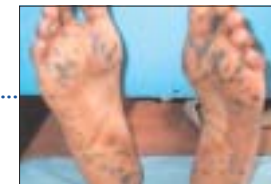C. R. Srinivas



154

Peutz-Jeghers syndrome with prominent palmoplantar pigmentation

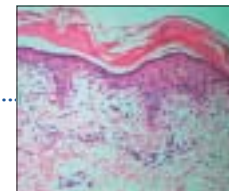
K. N. Shivaswamy, A. L. Shyamprasad, T. K. Sumathi, C. Ranganathan



154

Stratum corneum findings as clues to histological diagnosis of pityriasis lichenoides chronica

Rajiv Joshi



156

Author's reply

S. Pradeep Nair

157

Omalizumab in severe chronic urticaria

K. V. Godse.....

157

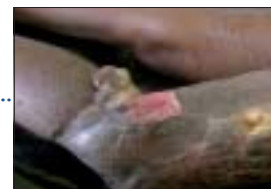Hypothesis: The potential utility of topical eflornithine against cutaneous leishmaniasis

M. R. Namazi

158

Nodular melanoma in a skin graft site scar

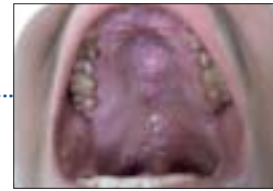A. Gnaneshwar Rao, Kamal K. Jhamnani, Chandana Konda



159

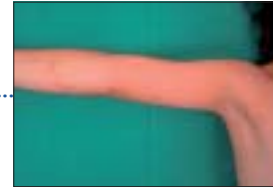Palatal involvement in lepromatous leprosy

A. Gnaneshwar Rao, Chandana Konda, Kamal Jhamnani..... 161



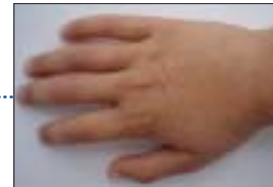Unilateral nevoid telangiectasia with no estrogen and progesterone receptors in a pediatric patient

F. Sule Afsar, Ragip Ortac, Gulden Diniz 163



Eruptive lichen planus in a child with celiac disease

Dipankar De, Amrinder J. Kanwar..... 164

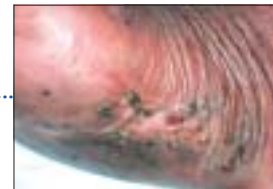

Xerosis and pityriasis alba-like changes associated with zonisamide

Feroze Kaliyadan, Jayasree Manoj, S. Venkitakrishnan..... 165

Treatment of actinomycetoma with combination of rifampicin and co-trimoxazole

Rajiv Joshi 166



Author's reply

M. Ramam, Radhakrishna Bhat, Taru Garg, Vinod K. Sharma, R. Ray, M. K. Singh, U. Banerjee, C. Rajendran 168

Vitiligo, psoriasis and imiquimod: Fitting all into the same pathway

Bell Raj Eapen 169

Author's reply

Engin Şenel, Deniz Seçkin 169

Multiple dermatofibromas on face treated with carbon dioxide laser: The importance of laser parameters

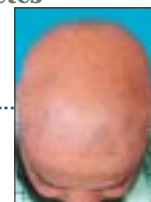Kabir Sardana, Vijay K. Garg 170

Author's reply

D. S. Krupa Shankar, A. Kushalappa, K. S. Uma, Anjay A. Pai..... 170

Alopecia areata progressing to totalis/universalis in non-insulin dependent diabetes mellitus (type II): Failure of dexamethasone-cyclophosphamide pulse therapy

Virendra N. Sehgal, Sambit N. Bhattacharya, Sonal Sharma, Govind Srivastava, Ashok K. Aggarwal 171



Subungual exostosis

Kamal Aggarwal, Sanjeev Gupta, Vijay Kumar Jain, Amit Mital, Sunita Gupta..... 173

Clinicohistopathological correlation of leprosy

Amrish N. Pandya, Hemali J. Tailor 174

RESIDENT'S PAGE

Dermatographism

Dipti Bhute, Bhavana Doshi, Sushil Pande, Sunanda Mahajan, Vidya Kharkar 177

FOCUS

Mycophenolate mofetil

Amar Surjushe, D. G. Saple 180

QUIZ

Multiple papules on the vulva

G. Raghu Rama Rao, R. Radha Rani, A. Amareswar, P. V. Krishnam
Raju, P. Raja Kumari, Y. Hari Kishan Kumar 185



E-IDVL

Net Study

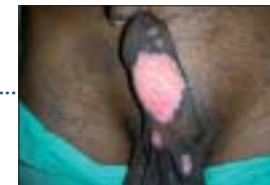Oral isotretinoin is as effective as a combination of oral isotretinoin and topical anti-acne agents in nodulocystic acne

Rajeev Dhir, Neetu P. Gehi, Reetu Agarwal, Yuvraj E. More 187

Net Case

Cutaneous diphtheria masquerading as a sexually transmitted disease

T. P. Vetrichevvel, Gajanan A. Pise, Kishan Kumar Agrawal,
Devinder Mohan Thappa 187



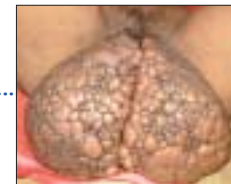Net Letters

Patch test in Behcet's disease

Ülker Gül, Müzeyyen Gönül, Seray Külcü Çakmak, Arzu Kılıç 187

Cerebriform elephantiasis of the vulva following tuberculous lymphadenitis

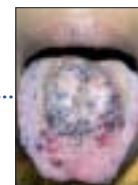Surajit Nayak, Basanti Acharjya, Basanti Devi, Satyadarshi Pattnaik,
Manoj Kumar Patra 188



Net Quiz

Vesicles on the tongue

Saurabh Agarwal, Krishna Gopal, Binay Kumar 188



Author's reply

Sir,

The readers' interest in our article is appreciated as well as

their survey of literature. Here are the parameters: make - union medical laser UML 25; de-bulking in continuous wave an continuous mode 9 w to 12 w depending on size of lesion; terminal vaporization - 6.3 w uper pulse continuous; excisions - 6.3 w super pulse continuous coagulation 6W continuous wave; continuous mode - de-focused; asepsis - 10% povidone iodine 5 minutes prior to procedure; anesthesia - 2% lignocaine with adrenaline through a 30 g needle.

The spot size was 0.3 mm. Irradiances cannot be precisely calculated as the hand piece is a focusing hand piece. Hence the figures below are approximate:

- Power: 0.5 to 25 watts, continuously scalable by one decimal place
- Modes: continuous, super pulse [10 w]
- Repeat: 400 Hz
- Beam diameter: 0.3 mm
- On time: .01, 0.1, 0.2, 0.3, 0.5 sec
- Off time: 0.01 to 0.1 sec in continuous and super pulse modes
- Guide beam: Helium Neon, flux adjustable

Since we used a beam diameter of 0.3 mm, the fluence can be calculated as follows:

- Diameter = 0.3 mm = 0.003 cm,
- Hence radius [r] = 0.0015 cm
- Therefore $r^2 = 0.00000225$
- $\Pi r^2 = 0.000007065$
- Irradiance = Power [w] / Spot size[Πr^2]
= $4.2 / 0.000007065 = 594479 \text{ w/cm}^2$
- Super pulse is 0.9 milli seconds = 0.0009 sec
- Fluence = irradiance x time = 594479×0.0009
= 382 J/cm^2

The detailed delivery capabilities of the machine used by us are shown in Table 1.

True ultra pulse laser is a combination of very short pulse width and high amplitude and is the patented technology

of one particular manufacturer; others marketed under the same name give the pulse width but not the amplitude and are no different from gated super pulse lasers in terms of their tissue effects. True ultra pulse laser is very expensive and cannot be recommended to all readers of our journal for indications where it is not needed. Besides, the haloed pages of our journal cannot be used to further the commercial interests of one manufacturer.

Pulse dye laser is not cited as this article is written to encourage Indian dermatologists to use an affordable device that is somewhat skill dependent and not to digress into the realm of expensive and difficult to maintain technologies.

**D. S. Krupa Shankar, A. Kushalappa,
K. S. Uma, Anjay A. Pai**

Departments of Dermatology and Pathology, Manipal Hospital,
Bangalore - 560 017, India

Address for correspondence: Dr. Krupa Shankar DS, Department of Dermatology, Manipal Hospital, Rustom Bagh, Airport Road, Bangalore - 560 017, India. E-mail: dermakrupa@yahoo.com

Table 1: Delivery capabilities of the machine used

Power	Irradiance W/cm ²	Fluence J/cm ²
0.5	70771	63
1	141542	127
2	283085	254
3	424628	382
4.2	594479	535
6	849256	764
6.3	900000	810
9	1285714	1157