

# Cutaneous phaeohyphomycosis caused by *Exophiala dermatitidis*: A case report and literature review

Mei Chen, Jingdong Zhang, Zhengbang Dong, Fei Wang

Department of Dermatology, Zhongda Hospital, School of Medicine, Southeast University, Nanjing, China

**Address for correspondence:** Dr. Fei Wang, Department of Dermatology, Zhongda Hospital, Southeast University, Dingjiaqiao Road, No. 87, Nanjing, Jiangsu 210009, China. E-mail: ffwangfei@163.com

## ABSTRACT

We report a case of cutaneous phaeohyphomycosis caused by *Exophiala dermatitidis*. An adult male presented with a 1 month history of erythematous swelling and ulcer on the right forearm. *E. dermatitidis* was identified from the lesion through microscopic examination, *in vitro* culture, cutaneous biopsy and molecular analysis. He was treated with oral itraconazole (400 mg/day) and showed improvement.

**Key words:** Cutaneous, *Exophiala dermatitidis*, phaeohyphomycosis

## INTRODUCTION

*Exophiala dermatitidis* which belongs to the dematiaceous fungi, is ubiquitous in nature and being gradually recognized as a cause of human disease. It often causes an opportunistic infection in immunosuppressed patients or those with chronic diseases and is rare in the immunocompetent. *Exophiala dermatitidis* causes phaeohyphomycosis of the internal organs and rarely occurs in cutaneous or subcutaneous tissues. When noted, the dermal infection usually appears as a mycotic cyst, nodule, or mass.<sup>[1]</sup> We report a case of cutaneous phaeohyphomycosis in a healthy man caused by *E. dermatitidis*.

## CASE REPORT

A 78-year-old man from Nanjing, China, presented with a 1 month history of an erythematous swelling and ulcer on the right forearm. The lesion first appeared as an asymptomatic erythematous patch and enlarged gradually with mild pain. After 2 weeks,

he developed scattered hemorrhagic blisters and ulcers accompanied by severe pain. He was treated with penicillin with no significant improvement. Subsequently, vasculitis was considered as a possible diagnosis and he was given prednisone therapy. However, lesions continue to extend and were associated with severe pain so he was referred to our hospital. He had neither past medical history nor evidence of underlying diseases or immunodeficiency. Physical examination revealed a well-demarcated, erythematous, non-fluctuant swelling on the right forearm with some hemorrhagic blisters, ulcers and purulent discharge on the surface. There was significant warmth and tenderness [Figure 1]. Routine laboratory tests were within the normal range except for an elevated white blood cell count of  $9.53 \times 10^9/L$  ( $3.5-9.5 \times 10^9/L$ ) and neutrophils 80.7% (40–75%). A series of laboratory investigations were carried out in an attempt to assess possible underlying conditions such as immunodeficiency and disseminated infections

This is an open access article distributed under the terms of the Creative Commons Attribution-NonCommercial-ShareAlike 3.0 License, which allows others to remix, tweak, and build upon the work non-commercially, as long as the author is credited and the new creations are licensed under the identical terms.

**For reprints contact:** reprints@medknow.com

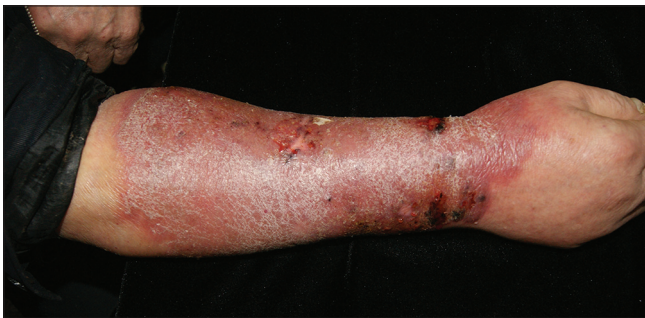**How to cite this article:** Chen M, Zhang J, Dong Z, Wang F. Cutaneous phaeohyphomycosis caused by *Exophiala dermatitidis*: A case report and literature review. Indian J Dermatol Venereol Leprol 2016;82:173-7.

**Received:** January, 2015. **Accepted:** August, 2015.


Access this article online	
<b>Quick Response Code:</b>	<b>Website:</b> www.ijdvl.com
	<b>DOI:</b> 10.4103/0378-6323.171013

yielding normal or negative results. An X-ray of right upper extremity was also normal.

A 10% potassium hydroxide preparation of exudate from the lesion revealed dark, branched, septate hyphae lacking chlamydoconidia [Figure 2]. Culture on Sabouraud's dextrose agar grew black, slow-growing colonies suggesting the presence of dematiaceous fungus [Figure 3]. Slide culture revealed tube-like phialides with aggregation of smooth, oval, unicellular conidia at their tips [Figure 4]. The colonies grew well on Sabouraud's dextrose agar at different temperatures (27°C, 35°C, 38°C, 40°C and 42°C). The *in vitro* susceptibility of the strain to antifungal agents was tested by the broth dilution technique using the M38-A2 method for antifungal susceptibility testing of filamentous fungi published by Clinical and Laboratory Standards Institute in America.<sup>[2]</sup> The minimum inhibitory concentrations of amphotericin B, fluconazole, itraconazole, voriconazole, terbinafine, micafungin and anidulafungin against this isolate were respectively, 4 µg/ml, 4 µg/ml, 0.5 µg/ml, 0.125 µg/ml, 0.25 µg/ml, 4 µg/ml and 4 µg/ml.



**Figure 1: Erythematous swelling and ulcer on the right forearm**



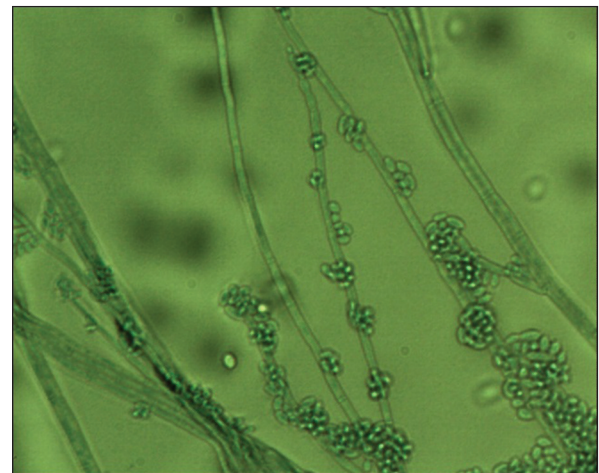
**Figure 3: Black, slow-growing colonies on Sabouraud's dextrose agar**

Biopsy from the lesion revealed acanthosis and a pandermal granulomatous infiltrate accompanied by neutrophils [Figure 5]. Periodic acid-Schiff and Gomori methenamine silver stains showed a large number of spores and hyphae in the dermis [Figures 6 and 7].

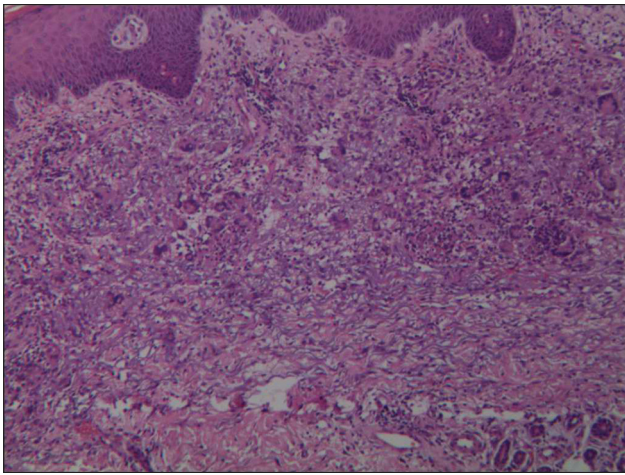
Ribosomal deoxyribonucleic acid internal transcribed spacer sequences and 18S ribosomal deoxyribonucleic acid sequences were analyzed for further confirmation of the previous results. The primers of internal transcribed spacer and 18S ribosomal deoxyribonucleic acid were designed as follows: Fungus-ED1-F: TCGTGTCCAATGTCTGAGTATATTAC; Fungus-ED2-R: GTGCTCAGTGAAGAAGCTCCG; Fungus-NS1-F: GTAGTCATATGCTTGTCTC; Fungus-NS8-R: TCCGCAGGTTACCTACGGA. The internal transcribed spacer and 18S ribosomal deoxyribonucleic acid region were amplified



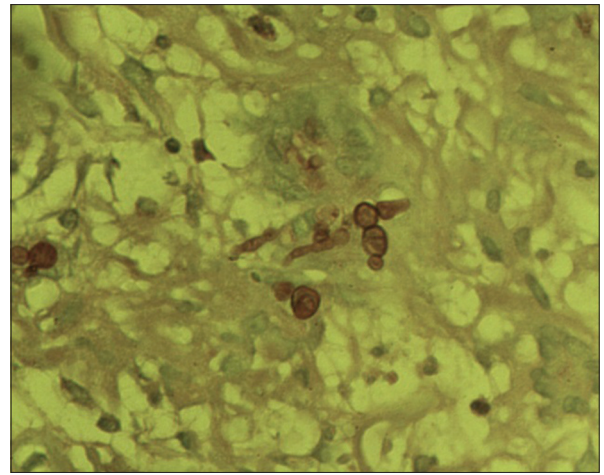
**Figure 2: Dark branched septate hyphae noted on direct microscopic examination (x400)**



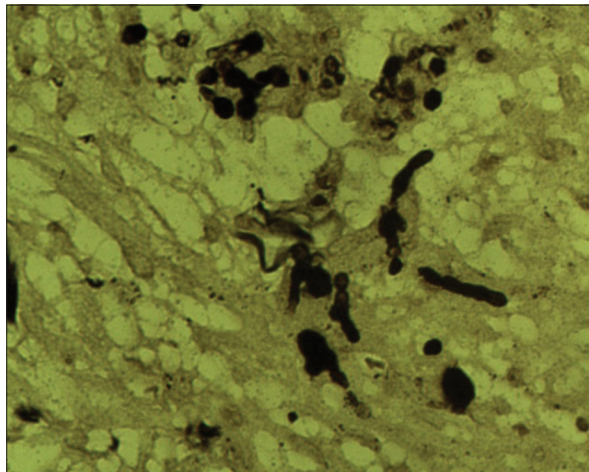
**Figure 4: Tube-like phialides with aggregates of smooth, oval, unicellular conidia at their tips were seen on slide culture (x400)**



**Figure 5: Granulomatous inflammation and neutrophils throughout the dermis (H and E, x100)**



**Figure 6: Spores and hyphae in the dermis (Periodic acid-Schiff, x400)**



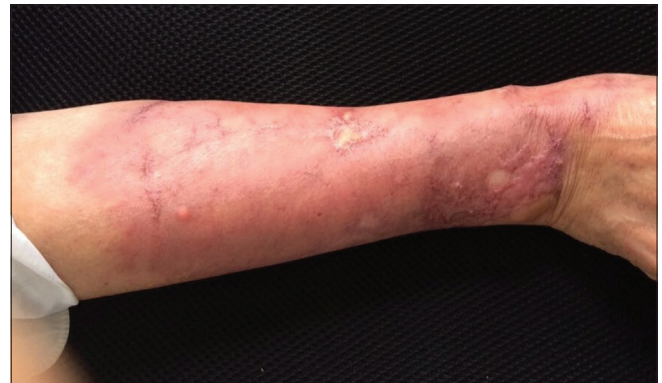**Figure 7: Abundant hyphae and spores (Gomori methenamine silver, x400)**

by polymerase chain reaction and underwent sequencing. The identification of *E. dermatitidis* was performed through deoxyribonucleic acid sequence alignment with accession numbers KJ652927 and DQ823107 (<http://blast.ncbi.nlm.nih.gov/Blast.cgi>).

We made a final diagnosis of cutaneous phaeohyphomycosis caused by *E. dermatitidis*. The patient was treated with oral itraconazole, 400 mg/day for 10 weeks with improvement of lesions [Figure 8]. At present, the patient continues to receive oral itraconazole and is on regular follow-up.

## DISCUSSION

The term “phaeohyphomycosis” is used to describe cutaneous, subcutaneous and systemic infections caused by hyphomycetous fungi which develop as



**Figure 8: The lesions were clinically improved two months later**

dematiaceous and septated hyphae in the host tissue.<sup>[3]</sup> *Exophiala* is the pathogen commonly responsible for phaeohyphomycosis. *E. dermatitidis* is the only species that can grow in temperatures  $>40^{\circ}\text{C}$  with negative nitrate assimilation. Compared with other *Exophiala*, *E. dermatitidis* rarely causes cutaneous or subcutaneous infection but is more likely to cause disseminated infections of specific systems such as brain, heart, lungs and digestive tract with a mortality rate of 40%.<sup>[4,5]</sup> We reviewed all published cases of cutaneous and subcutaneous *E. dermatitidis* infection reported in the English literature [Table 1].

In a recent review, Suzuki *et al.* identified the following predisposing factors for infection with *E. dermatitidis*: peritoneal dialysis, leukemia, steroid use, human immunodeficiency virus infection, cancer, bronchiectasis, diabetes mellitus and multiple myeloma.<sup>[13]</sup> However, our patient and two previously reported cases had no prior underlying factors, history of trauma or immunocompromised states [Table 1].

**Table 1: Reported cases of cutaneous and subcutaneous phaeohyphomycosis caused by *Exophiala dermatitidis***

Age/gender	Clinical manifestation	Underlying factor(s)	Treatment	Outcome	References
78/male	Erythematous swelling and ulcer on the right forearm	None	Itraconazole	Better	Our case
17/male	Confluent nodule on the right forearm 1 year	None	Itraconazole and surgery	Cure	[6]
60/male	A mass in the left calf for 4 months	Nephrectomy for renal-cell carcinoma with no recurrence, angina pectoris and peptic ulcer	Surgical excision	Cure	[7]
55/female	A mass in the left calf	Polymyositis being treated with prednisone, 20 mg/day	Surgery and systemic 5-fluorocytosine, 150 mg/kg/day	Died	[7]
74/male	A cystic mass on the volar aspect of the right little finger	Burn of the right little finger	Cyst removal	Cure	[8]
39/female	A necrotic ulcer in the right posterior palatal mucogingiva	Acute myeloid leukemia	Amphotericin B (50 mg/day) and itraconazole (200 mg/day)	Cure	[9]
58/female	A painful nodule on the right hand	Rheumatoid arthritis, intra-articular steroid injection before development of the nodule	Itraconazole, 200 mg daily for 1 month followed by surgical excision	Cure	[10]
42/male	A linear yellow longitudinal ridging on the right great toe nail for 1 year	None	Itraconazole	Cure	[11]
51/female	Bilateral black pigmentation of the big toe nails for 8 years	Diabetes	Topical bifonazole solution	Cure	[12]

Clinical presentations of the disease caused by *E. dermatitidis* vary among different geographic locations. Although this fungus is primarily reported to cause cerebral infections in immunocompetent young individuals of Southeast Asia origin, it commonly remains localized as a subclinical colonization of the respiratory tract in patients with cystic fibrosis in Europe. The possibility of involvement of race-dependent virulence has been suggested as an explanation of this observation.<sup>[14]</sup> Cutaneous or subcutaneous infection with *E. dermatitidis* usually presents with a nodule, a cyst or mass; we were unable to find any published reports of the infection presenting as an erythematous swelling with ulcers.

In our case, the histological and culture findings supported the diagnosis but final identification of the causative organism was achieved by sequencing of 18s ribosomal deoxyribonucleic acid and internal transcribed spacer region of the fungus since the morphological distinction in culture between the *E. dermatitidis* and other species of *Exophiala* is very difficult. The susceptibility of the organisms to antifungal agents is an important factor affecting the development and outcome of *Exophiala* infection. Due to the rarity of the disease, no large controlled studies of antifungal agents has been performed. Itraconazole and amphotericin B appear to be effective against *Exophiala* isolates *in vitro* at minimal inhibitory concentrations <1 mg/ml.<sup>[15,16]</sup> The minimal inhibitory

concentration of itraconazole (0.5 mg/ml) against the strain isolated from our patient is consistent with the therapeutic effect that was achieved. Previously reported cases [Table 1] were treated with antifungal agents, antifungal agents combined with surgery or surgery alone with satisfactory results except in one patient who died.

#### Acknowledgments

This work was supported by the Institute of Dermatology, Chinese Academy of Medical Sciences and Peking Union Medical College.

#### Financial support and sponsorship

Nil.

#### Conflicts of interest

There are no conflicts of interest.

#### REFERENCES

- Patel AK, Patel KK, Darji P, Singh R, Shivaprakash MR, Chakrabarti A. *Exophiala dermatitidis* endocarditis on native aortic valve in a postrenal transplant patient and review of literature on *E. dermatitidis* infections. *Mycoses* 2013;56:365-72.
- Clinical and Laboratory Standards Institute (CLSI). Reference Method for Broth Dilution Antifungal Susceptibility Testing of Filamentous Fungi; Approved Standard M38-A2, 2<sup>nd</sup> edn. Wayne, PA: Clinical and Laboratory Standards Institute, 2008.
- Ajello L, Georg LK, Steigbigel RT, Wang CJ. A case of phaeohyphomycosis caused by a new species of *Phialophora*. *Mycologia* 1974;66:490-8.

4. Revankar SG, Patterson JE, Sutton DA, Pullen R, Rinaldi MG. Disseminated phaeohyphomycosis: Review of an emerging mycosis. *Clin Infect Dis* 2002;34:467-76.
5. Patel AK, Patel KK, Darji P, Singh R, Shivaprakash MR, Chakrabarti A. *Exophiala dermatitidis* endocarditis on native aortic valve in a postrenal transplant patient and review of literature on *E. dermatitidis* infections. *Mycoses* 2013;56:365-72.
6. Russo JP, Raffaeli R, Ingratta SM, Rafti P, Mestroni S. Cutaneous and subcutaneous phaeohyphomycosis. *Skinmed* 2010;8:366-9.
7. Crosby JH, O'Quinn MH, Steele JC Jr, Rao RN. Fine-needle aspiration of subcutaneous phaeohyphomycosis caused by *Wangiella dermatitidis*. *Diagn Cytopathol* 1989;5:293-7.
8. Scott JW, Luckie J, Pfister WC, Padhye AA, Standard PG, Bohan CA, *et al.* Phaeohyphomycotic cyst caused by *Wangiella dermatitidis*. *Mykosen* 1986;29:243-7.
9. Myoken Y, Sugata T, Fujita Y, Kyo T, Fujihara M, Katsu M, *et al.* Successful treatment of invasive stomatitis due to *Exophiala dermatitidis* in a patient with acute myeloid leukemia. *J Oral Pathol Med* 2003;32:51-4.
10. Woollons A, Darley CR, Pandian S, Arnstein P, Blackee J, Paul J. Phaeohyphomycosis caused by *Exophiala dermatitidis* following intra-articular steroid injection. *Br J Dermatol* 1996;135:475-7.
11. Park KY, Kim HK, Suh MK, Seo SJ. Unusual presentation of onychomycosis caused by *Exophiala (Wangiella) dermatitidis*. *Clin Exp Dermatol* 2011;36:418-9.
12. Matsumoto T, Matsuda T, Padhye AA, Standard PG, Ajello L. Fungal melanonychia: Ungual phaeohyphomycosis caused by *Wangiella dermatitidis*. *Clin Exp Dermatol* 1992;17:83-6.
13. Suzuki K, Nakamura A, Fujieda A, Nakase K, Katayama N. Pulmonary infection caused by *Exophiala dermatitidis* in a patient with multiple myeloma: A case report and a review of the literature. *Med Mycol Case Rep* 2012;1:95-8.
14. Matos T, de Hoog GS, de Boer AG, de Crom I, Haase G. High prevalence of the neurotrope *Exophiala dermatitidis* and related oligotrophic black yeasts in sauna facilities. *Mycoses* 2002;45:373-7.
15. Gold WL, Vellend H, Salit IE, Campbell I, Summerbell R, Rinaldi M, *et al.* Successful treatment of systemic and local infections due to *Exophiala* species. *Clin Infect Dis* 1994;19:339-41.
16. Clancy CJ, Wingard JR, Hong Nguyen M. Subcutaneous phaeohyphomycosis in transplant recipients: Review of the literature and demonstration of *in vitro* synergy between antifungal agents. *Med Mycol* 2000;38:169-75.