

Symmetrical erythematous annular and scaly patches

A 52 year-old woman presented with a two-year history of pruritic, burning and expanding red rings involving the entire body. She had marked fatigue, anorexia and weight loss. Examination revealed a cachectic woman with symmetrical erythematous annular and scaly patches involving the trunk [Figure 1], lower limbs and back. A few pustules and vesicles were present on the trunk. Intertriginous areas showed erosions. Glossitis and stomatitis were also present.

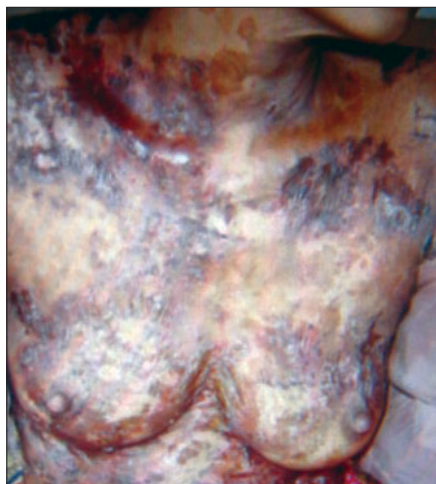

Figure 1: Erythematous scaly annular and serpiginous plaques with areas of erosions and pigmentation on the trunk

Investigations revealed a hemoglobin (Hb) value of 7.5 gm%, hyperglycemia (postprandial blood sugar, PPBS = 320 mg%), abnormal glucose tolerance test results and aminoaciduria. Skin biopsy showed intraepidermal cleft, vacuolated pale epidermal cells with pyknotic nuclei and neutrophils in the upper epidermis [Figure 2].

WHAT IS YOUR DIAGNOSIS?

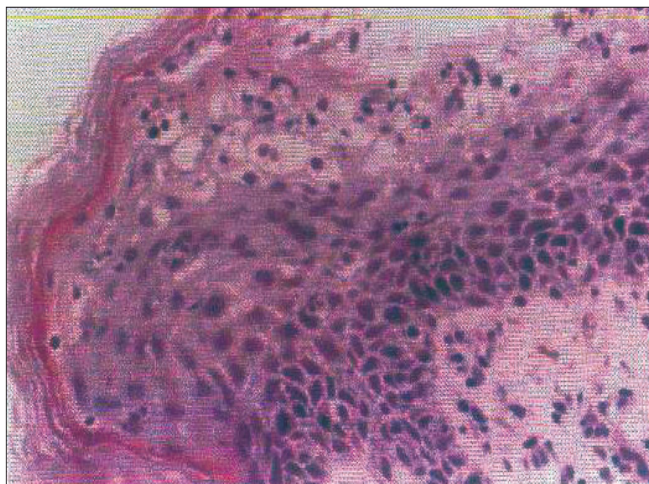


Figure 2: Intraepidermal cleft and vacuolated pale epidermal cells (H and E, x400)

How to cite this article: Riyaz N, Rajan U, Anuradha KB. Symmetrical erythematous annular and scaly patches. Indian J Dermatol Venereol Leprol 2007;446.

Received: May, 2005. **Accepted:** October, 2006. **Source of Support:** Nil. **Conflict of Interest:** None declared.

ANSWER: GLUCAGONOMA SYNDROME

The skin lesions are suggestive of necrolytic migratory erythema (NME), which is characteristic of glucagonoma syndrome, confirmed by skin biopsy. Glucagonoma was confirmed by ultrasonography (USG) and computed tomography (CT). Ultrasonography of the abdomen showed a uniform hypoechoic, oval mass lesion in the tail of the pancreas, 3.7 x 3 cm in size, closely abutting the superior pole of the kidney. Other organs were of normal size and echo pattern. CT scan of the abdomen revealed a well-enhanced soft tissue lesion, 56 x 40 x 30 mm in size, with a speck of calcification in the region of the tail of the pancreas [Figure 3]. There was a near-total subsidence following surgery [Figure 4].

DISCUSSION

Necrolytic migratory erythema (NME) is a rare skin condition characteristically present as irregular annular eruptions with serpiginous advancing borders. Vesicles, pustules or bullae

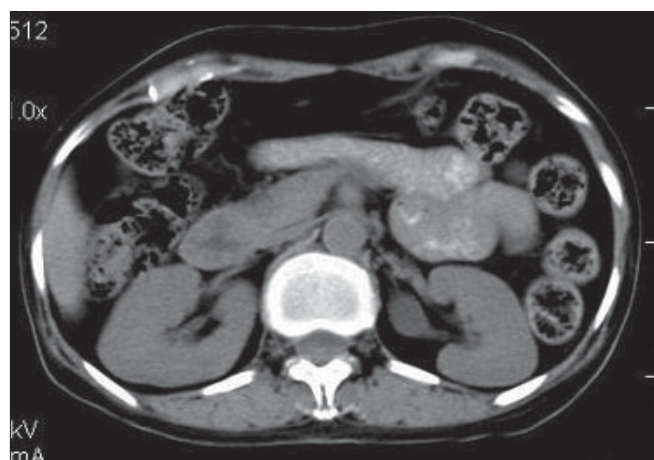

Figure 3: CT scan of the abdomen showing a well-enhanced, soft tissue lesion 56 x 40 x 30 mm in size with a speck of calcification in the tail of the pancreas

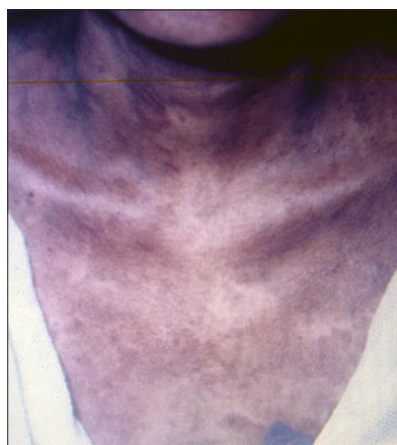


Figure 4: Improvement of skin lesions after surgery

may be seen in the advancing margins or at the centre of the lesions that subsequently erode, become crusted and heal with hyperpigmentation. The lesions occur most commonly on the perineum, distal extremities, lower abdomen and face.^[1,2] NME usually appears as a paraneoplastic process in patients with glucagonoma.^[2] In 1974, Mallinson *et al*, defined the glucagonoma syndrome as necrolytic migratory erythema with glucagonoma, diabetes mellitus, anemia and weight loss.

Rarely does NME have no correlation with glucagonoma and in such cases, may be related to celiac disease, malabsorption, chronic pancreatitis, hepatic cirrhosis or extra-pancreatic, glucagon-secreting tumors (renal, duodenal or pulmonary).^[3-6]

There are many theories about the pathogenesis of NME. The role of glucagon in the causation of NME is supported by the following facts: 1) increased levels of glucagon yield greater amounts of epidermal arachidonic acid, which causes inflammatory changes in the skin; 2) the cure of NME after surgical removal of the tumor with consequent normalisation of serum glucagon levels; and 3) the remission of the rash after therapy with somatostatin analogues like octreotide, which is a potent inhibitor of glucagon release.^[7] Other theories that could explain the genesis of NME are based on the secondary effects of glucagon. Glucagon stimulates glycogenolysis, gluconeogenesis, ketogenesis and consequently, a systemic catabolic state. The hypoaminoacidemia secondary to increased gluconeogenesis is suggested by some reports to be a cause of NME.

Surgery is the mainstay of treatment for glucagonoma, which results in a marked improvement of the skin lesions. In patients with hepatic metastasis, streptozocin, dacarbazine and octreotide have proved beneficial.^[8,9] Improvement of the skin lesions has been observed with zinc, omega-3-triglyceride and amino acid supplementation.^[4] Distal pancreatectomy was done for our patient followed by marked improvement of skin lesions.

Glucagonoma is a high-grade malignant tumor with a 50% chance of metastasis. The diagnosis of NME is a matter of great importance as it can lead to early detection of glucagonoma.

Najeeba Riyaz, Uma Rajan, Anuradha KB
Department of Dermatology, Medical College, Calicut, India

Address for Correspondence: Dr. Najeeba Riyaz, Arakkal
Chalapuram, Calicut - 673002, Kerala, India.
E-mail: saif_gem@hotmail.com

REFERENCES

1. Sweet RD. A dermatosis specifically associated with tumour of pancreatic alpha cells. *Br J Dermatol* 1974;90:301-8.
2. Wilkinson DS. Necrolytic migratory erythema with pancreatic carcinoma. *Proc R Soc Med* 1971;64:1197-8.
3. Marinkovich MP, Botella R, Datloff J, Sangueza OP. Necrolytic migratory erythema without glucagonoma in patients with liver disease. *J Am Acad Dermatol* 1995;32:605-9.
4. Blacford S, Wright S, Roberts DL. Necrolytic migratory erythema without glucagonoma: The role of dietary essential fatty acids. *Br J Dermatol* 1991;125:460-2.
5. Kelly CP, Johnson CF, Nolan N, Keeling PW, Weir DG. Necrolytic migratory erythema with elevated plasma enteroglucagon in celiac disease. *Gastroenterology* 1989;96:1350-3.
6. Mullans EA, Cohen PR. Iatrogenic necrolytic migratory erythema. A case report and review of non-glucagonoma associated necrolytic migratory erythema. *J Am Acad Dermatol* 1998;38:866-73.
7. Peterson LL, Shaw JC, Acott KM, Mueggler PA, Parker F. Glucagonoma syndrome: In vitro evidence that glucagon increases epidermal arachidonic acid. *J Am Acad Dermatol* 1984;11:468-73.
8. Bewly AP, Ross JS, Bunker CB, Staughton RC. Successful treatment of a patient with octreotide-resistant necrolytic migratory erythema. *Br J Dermatol* 1996;134:1101-4.
9. van der Loos TL, Lambrecht ER, Lambers JC. Successful treatment of glucagonoma related necrolytic migratory erythema with dacarbazine. *J Am Acad Dermatol* 1987;16:468-72.