

Use of mechanical pencil with needle for slit making in hair restoration surgery

Clinical Challenge

One of the most popular techniques used by surgeons for slit creation during hair restoration surgeries is the use of needles or blades. Owing to their smaller length, producing a slit with a Nokor needle or an 18/19G needle exerts strain on the surgeon, increases the duration of surgery and makes angulation of the slit difficult, perhaps harming the deep plexus.¹

Solution

We propose a solution for the above-mentioned problem by using an autoclaved mechanical lead pencil as a holder for the hypodermic/ Nokor needle. Because it was readily available,

less priced and had a sturdy lead retainer, we selected a metallic 2 mm mechanical lead pencil. Using clean scissors, we snipped the needle hub on an 18G/19G or Nokor needle. Instead of lead, the needle without its hub was inserted inside the mechanical pencil. By covering the needle with micropore tape, we changed the needle's diameter to achieve the desired size [Figure 1].

The depth of the needle can be changed as needed with the use of the mechanical pencil. The enhanced ergonomics using the pencil as a needle holder, offer the surgeon easy slit making with minimal effort also cutting down the length of the procedure [Figure 2 and Video 1].

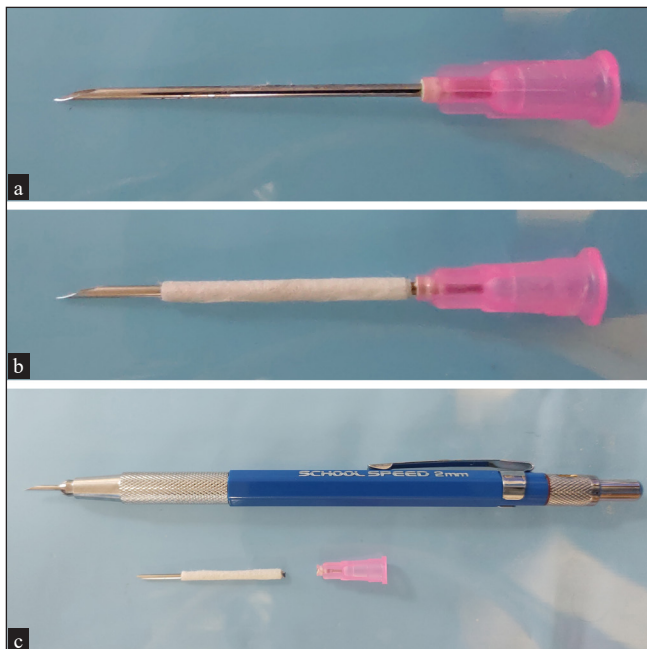


Figure 1: (a) showing 19G needle with needle hub; (b) 19G needle wrapped with micropore paper tape to increase the diameter of the needle; (c) Mechanical lead pencil with 19G needle in situ.

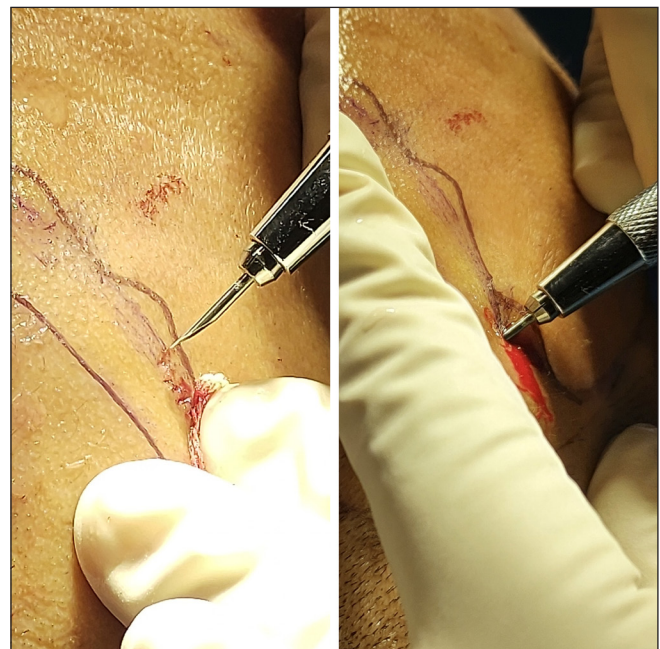

Figure 2: Slit making in hair restoration surgery using mechanical lead pencil with 19G needle.

How to cite this article: Vendhan S, Neema S, Vasudevan B, Bala N. Use of mechanical pencil with needle for slit making in hair restoration surgery. *Indian J Dermatol Venereol Leprol.* 2024;90:260–1. doi: 10.25259/IJDVL_806_2023

Received: August, 2023 **Accepted:** September, 2023 **Epub Ahead of Print:** November, 2023 **Published:** February, 2024

DOI: 10.25259/IJDVL_806_2023 **PMID:** 38031679 **Video available on:** https://doi.org/10.25259/IJDVL_806_2023

This is an open-access article distributed under the terms of the Creative Commons Attribution-Non Commercial-Share Alike 4.0 License, which allows others to remix, tweak, and build upon the work non-commercially, as long as the author is credited and the new creations are licensed under the identical terms.

Declaration of patient consent

The authors certify that they have obtained all appropriate patient consent.

Financial support and sponsorship

Nil.

Conflicts of interest

There are no conflicts of interest.

Use of artificial intelligence (AI)-assisted technology for manuscript preparation

The authors confirm that there was no use of artificial intelligence (AI)-assisted technology for assisting in the writing or editing of the manuscript and no images were manipulated using AI.

Video 1: Demonstration of slit making using mechanical pencil with 19G needle.

**Senkadhir Vendhan, Shekhar Neema¹,
Biju Vasudevan², Nishu Bala³**

Department of Dermatology, Dr. Babasaheb Ambedkar Memorial Hospital,
Central Railway, IRHS, Byculla, Mumbai, Maharashtra,

¹Department of Dermatology Command Hospital, Lucknow, Uttar Pradesh,

²Department of Dermatology, Armed Forces Medical College, Pune,

³Department of Dermatology, Command Hospital,
Pune, Maharashtra, India.

Corresponding author:

Dr. Senkadhir Vendhan,

Department of Dermatology,

Dr. Babasaheb Ambedkar Memorial Hospital, Central Railway,

IRHS, Byculla, Mumbai, Maharashtra, India.

vendhan100@gmail.com

Reference

1. Atodaria PR, Venkataram A, Mysore V, Atodaria KP. Optimal hair transplant recipient site slit design: Minimizing vascular damage. *Indian J Plast Surg* 2021;54:471–6.