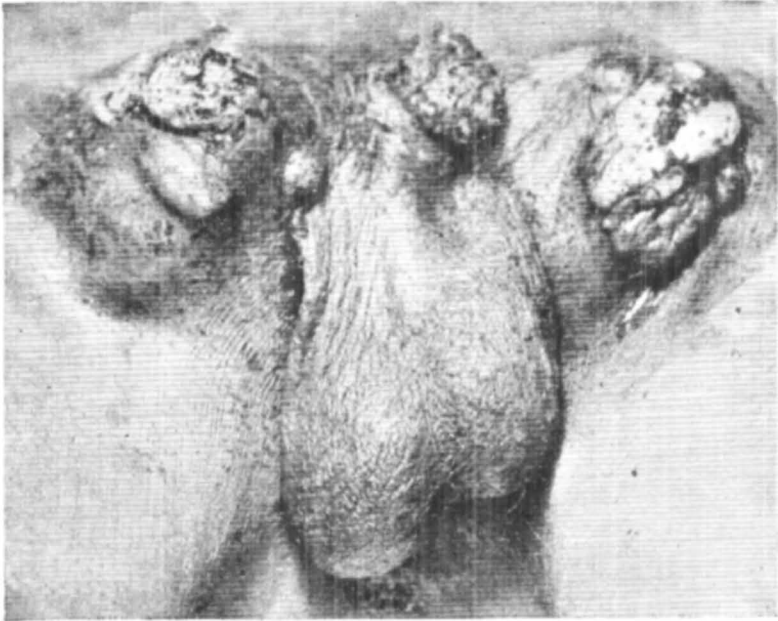


WHAT IS YOUR DIAGNOSIS ?



Nineteen year old male patient underwent a total amputation of penis 3 months prior to admission, for a reddish irregular growth on the glans penis. One month before admission patient developed swellings in both inguinal regions which later ulcerated and began to discharge pus. He gave history of exposure to venereal disease 2 years prior to the onset of symptoms.

Examination showed a pale emaciated young man. General systemic review revealed no abnormalities. Local examination showed firm indurated swellings in both inguinal regions with irregular unhealthy ulceration on the surface and pus discharge. Ulcerations were also present at the amputation scar and site of urethroplasty in the perineum.

Differential diagnosis .

1. Squamous cell carcinoma penis with secondaries
2. Granuloma venereum with pseudobuboes
3. Tuberculosis cutis orificialis with scrofuloderma

(Answer Page No. 33)