

Disseminated cutaneous rhinosporidiosis

Surajit Nayak, Basanti Acharjya, Basanti Devi, Antaryami Sahoo, Nilachal Singh

Department of Skin and VD, MKCG Medical College and Hospital, Berhampur, Orissa, India.

Address for correspondence: Dr. Surajit Nayak, Department of Skin and VD, MKCG Medical College, Berhampur - 760 010, Orissa, India.
E-mail: surajitnyk@yahoo.co.in

ABSTRACT

A 48-year-old male patient presented to Skin and VD outpatient with multiple granulomatous growths of different sizes all over the body, including numerous subcutaneous swellings mimicking lipomas of 2 years duration. Two and half years back he was operated for a polypoidal growth of left nostril with subsequent recurrence. Fine needle aspiration cytology and histopathology of the cutaneous lesion confirmed the diagnosis as rhinosporidiosis. We report this rare case of disseminated cutaneous rhinosporidiosis.

Key Words: Disseminated, Rhinosporidiosis, Subcutaneous

INTRODUCTION

Rhinosporidiosis, a chronic granulomatous, infective disease is caused by a cyanobacterium, *Microcystis aeruginosa* (previously thought to be caused by *R. seeberi*). Though it occurs universally, rhinosporidiosis is endemic in south Asia, being mainly reported from southern India and Sri Lanka. This disease is commonly seen in adult men and the possible mode of transmission to humans is by direct contact with spores through dust, through infected clothing and fingers and through swimming in stagnant water.^[1] Clinically it is characterized by development of pedunculated and sessile polypoid lesions on the mucosa of nose, eyes and larynx and very rarely on other parts of the body like skin, viscera and brain. Subcutaneous lesions are extremely rare. We present a case of nasal rhinosporidiosis with cutaneous and subcutaneous dissemination.

CASE REPORT

A 48-year-old male, office worker, presented to the Skin and VD department with numerous, reddish, shiny, globular swellings all over the body including face and scalp [Figure 1].

The lesions were present since two years. On examination, lesions were found to be nontender, highly vascular and were bleeding on touch. The size varied from pinhead to huge tumoral growths, lying singly and also in clusters. Surface was moist and shiny with a few lesions showing hemorrhagic crusts. Though most of the lesions were sessile, a few larger lesions were pedunculated. In addition, multiple subcutaneous lumps of different sizes were seen over the face, trunk and extremities [Figure 1]. The overlying skin was normal in appearance and free from underlying mass.

Anterior rhinoscopy revealed an erythemathous, warty, polypoidal growth protruding out from the left nostril [Figure 2]. Nasopharynx and oral cavity examination showed no visible growth. The patient had undergone surgery for the nasal growth 2.5 years back, which was the only lesion at that time, but reappeared again after four months and other lesions started appearing subsequently in due course. The patient was thin built with pallor and having gross pitting edema of both extremities. He was a chronic alcoholic and a known asthmatic, under prolonged oral steroid therapy. Patient was married with two children and denied any sexual contact outside marriage.

How to cite this article: Nayak S, Acharjya B, Devi B, Sahoo A, Singh N. Disseminated cutaneous rhinosporidiosis. Indian J Dermatol Venereol Leprol 2007;73:185-7.

Received: August, 2006. **Accepted:** December, 2006. **Source of Support:** Nil. **Conflict of Interest:** None declared.

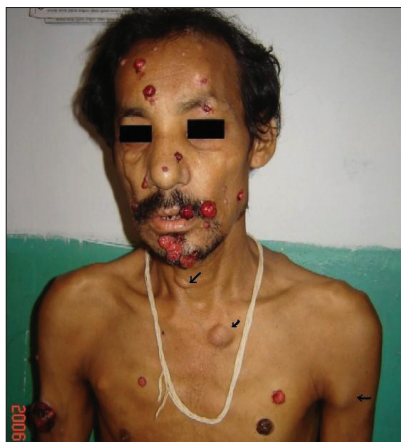

Figure 1: Cutaneous and subcutaneous (arrows) lesions

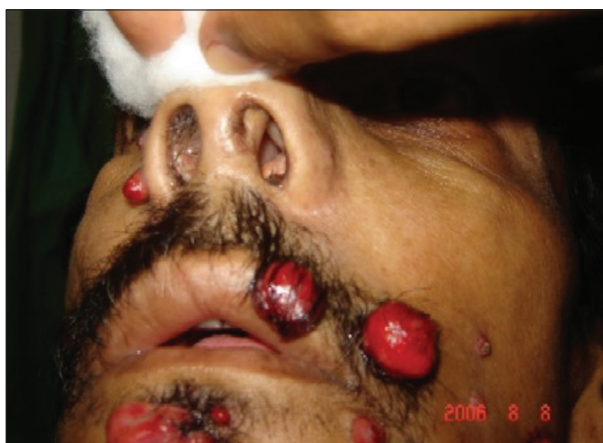

Figure 2: Polypoidal lesion seen through left nose and satellite lesions on face

Other systemic examinations revealed no abnormality. Hematological examination showed moderate anemia (8.8 gm%) and all biochemical parameters were within normal range. Chest X-ray and ultrasonography of abdomen and pelvis showed no abnormality. Serological tests for HIV and syphilis were negative.

Fine needle aspiration cytology (FNAC) from subcutaneous nodules yielded thick, purulent material, which on 10% KOH showed sporangia of *R. seeberi* at different stages of development [Figure 3]. Bits of tissue from multiple sites were sent for histopathological study, which showed organisms in various stages of maturation in a fibromyxomatous stroma containing chronic inflammatory cells, which include macrophages, lymphocytes and neutrophils [Figure 4]. A final diagnosis of nasal rhinosporidiosis with cutaneous dissemination was made. The patient was advised to take dapson 100 mg orally daily for six months and discharged. He was referred to the Department of Surgery for excision and electrodesiccation.

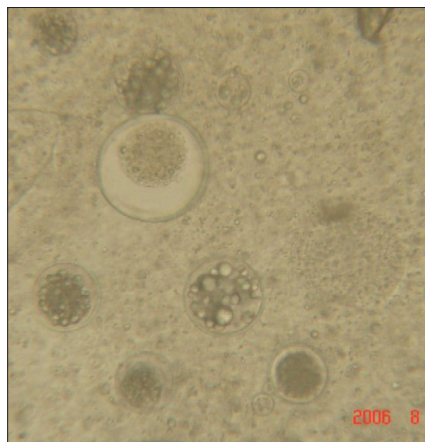


Figure 3: FNAC Showing sporangia in different stages of maturation

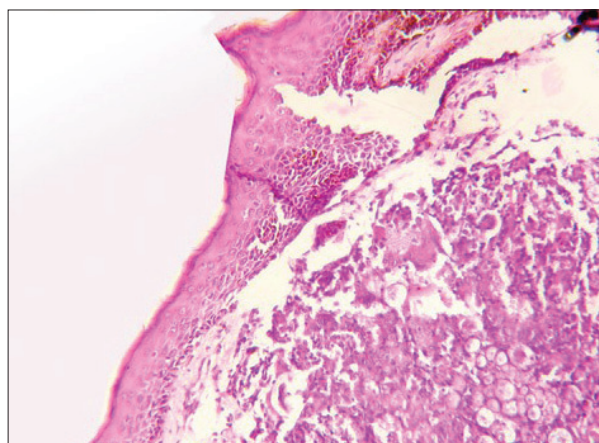


Figure 4: Skin biopsy: Numerous sporangia within granulomatous inflammation (H and E, x200)

DISCUSSION

Rhinosporidiosis, a chronic granulomatous disease, first reviewed in 1998,^[2] has been known to mankind for over a hundred years. The organism was first described by Malbran in 1892 as a sporozoon, as a protozoan by Seeber and as a phycomyces by Ashworth in 1923.^[3] Its taxonomic position was unclear till date, but a recent isolation of a prokaryotic cyanobacterium *Microcystis aeruginosa* by Ahluwalia *et al*^[4] from water samples of ponds and rivers where patients were bathing and detection of both large cells and nanocytes of *M. aeruginosa* inside round bodies of rhinosporidiosis by light and electron microscope has virtually ended all etiological controversies surrounding rhinosporidiosis. This new finding may justify a change in the name “rhinosporidiosis” that has been traditionally associated with the fungus *R. seeberi*. The presumed mode of infection from the natural aquatic habitat of the organism is through the traumatized epithelium (“transepithelial infection”)^[5] most commonly in nasal sites. Mode of spread is by three means:

1. **Autoinoculation:** This was considered by Karunaratne^[6] in his classical monograph on rhinosporidiosis, to be the explanation for the occurrence of satellite lesions adjacent to granulomas, especially in the upper respiratory sites and for local spread.
2. **Hematogenous spread:** There is evidence for hematogenous spread of rhinosporidiosis to anatomically distant sites.^[7] The development of subcutaneous granulomata all over the body, without breach of the overlying skin, could be attributed to such hematogenous dissemination, from a subclinical, upper respiratory focus of infection.
3. **Direct inoculation** of the organism in traumatized skin, otherwise known as primary cutaneous type. Our case shows both hematogenous and autoinoculation modes of transmission.

A diagnosis of the disease can be made by simple aspiration cytology and examination of aspirated material with 10% KOH or by Papanicolaou smear and finding the organism in different stages of maturation even in the absence of a histopathological study. However, a definitive diagnosis of rhinosporidiosis is by histopathology on biopsied or resected tissues, with the identification of the pathogen in its diverse stages of maturation. In the absence of specific tests for immune responses in diseased hosts, it is not surprising that there was very little data, till recently, on the immune responses in rhinosporidiosis. Chronic alcoholism and prolonged steroid abuse for asthma might have contributed to immunosuppression and subsequent development of a severe variety of metastatic disease in our case. Various authors, even in immunocompetent patients have described similar disseminated cases.^[8,9]

The disease needs to be differentiated from bacillary angiomatosis and coccidiomycosis, with both having a different clinical presentation and histopathological findings. Besides, in coccidiomycosis, finding spores of small size (less than 60 µm in diameter) is an easy distinction.^[10] Our patient was discharged and was advised to take dapsone, despite the fact that it is quite ineffective.^[9,11] Surgery (surgical removal and electrodesiccation) remains the treatment of choice.^[12] But it is a well-established fact that dapsone is the only drug having some anti-rhinosporidial effect,^[13,14] which arrests maturation of sporangia and promotes fibrosis in

stroma, when used as an adjunct to surgery. Great caution should be exercised during surgical excision as it can lead to hematological dissemination in a limited variety of the disease.

With detection of a definite organism, research is focused on culture and evaluation of curative drugs. Hopefully, once medical therapy becomes available, surgery may be a treatment of the past.

REFERENCES

1. Kamal MM, Luley AS, Mundhada SG, Bohhate SK. Rhinosporidiosis. Diagnosis by scrape cytology. *Acta Cytol* 1995;39:931-5.
2. Arseculeratne SN, Ajello L. *Rhinosporidium seeberi*. In: Hay RJ, Ajello L, editors. *Topley and Wilson Microbiology and Microbial infection, Medical Mycology*. 9th ed. 1998. p. 595-615.
3. Ashworth JH. On *Rhinosporidium seeberi* with special reference to its sporulation and affinities. *Trans Royal Soc Edinb* 1923;53:301-42.
4. Ahluwalia KB, Maheshwari N, Deka RC. Rhinosporidiosis: A study that resolves etiologic controversies. *Am J Rhinol* 1997;11:479-83.
5. Karunaratne WA. The pathology of rhinosporidiosis. *J Path Bact* 1934;XLII:193-202.
6. Karunaratne WA. Rhinosporidiosis in Man. The Athlone Press: London, England; 1964. p.146
7. Rajam RV, Viswanathan GC. Rhinosporidiosis: A study with a report of a fatal case with systemic dissemination. *Indian J Surg* 1955;17:269-98.
8. Agarwal S, Sharma KD, Shrivastava JB. Generalized rhinosporidiosis with visceral involvement: Report of a case. *Arch Dermatol* 1959;80:22-6.
9. Thappa DM, Venkatesan S, Sirka CS, Jaisankar TJ, Gopalkrishnan, Ratnakar C. Disseminated cutaneous rhinosporidiosis. *J Dermatol* 1998;25:527-32.
10. Longley BJ. Fungal diseases. In: Elder D, Elenitsas R, Jaworsky C, Johnson B, editors. *Lever's Histopathology of the skin*. 8th ed. Lippincott Williams and Wilkins: Philadelphia; 1997. p. 517-52.
11. Muhammed K, Abdul KL. Subcutaneous rhinosporidiosis. *Indian J Dermatol Venereol Leprol* 1997;63:320-2.
12. Vijaikumar M, Thappa DM, Karthikeyan K, Jayanthi S. Verrucous lesion of the palm. *Postgrad Med J* 2002;78:302,305-6.
13. Nair KK. Clinical trial of diamino-diphenylsulphone (DDS) in nasal and nasopharyngeal rhinosporidiosis. *Laryngoscope* 1979;89:291-5.
14. Job A, Venkateswaran S, Mathan M, Krishnaswami H, Raman R. Medical therapy of rhinosporidiosis with dapsone. *J Laryngol Otol* 1993;107:809-12.