

# Indian Journal of Dermatology, Venereology & Leprology

Journal indexed with SCI-E, PubMed, and EMBASE

Vol 74 | Issue 2 | Mar-Apr 2008

C O N T E N T S

## EDITORIAL

### Management of autoimmune urticaria

Arun C. Inamadar, Aparna Palit ..... 89

## VIEW POINT

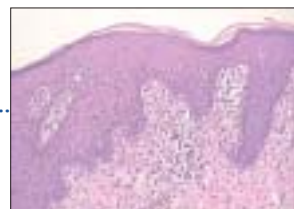### Cosmetic dermatology versus cosmetology: A misnomer in need of urgent correction

Shyam B. Verma, Zoe D. Draelos ..... 92

## REVIEW ARTICLE

### Psoriasiform dermatoses

Virendra N. Sehgal, Sunil Dogra, Govind Srivastava, Ashok K. Aggarwal ..... 94



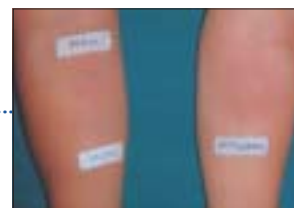## ORIGINAL ARTICLES

### A study of allergen-specific IgE antibodies in Indian patients of atopic dermatitis

V. K. Somani ..... 100

### Chronic idiopathic urticaria: Comparison of clinical features with positive autologous serum skin test

George Mamatha, C. Balachandran, Prabhu Smitha ..... 105



### Autologous serum therapy in chronic urticaria: Old wine in a new bottle

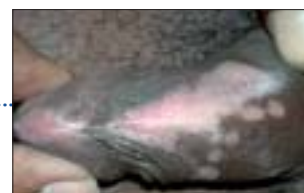A. K. Bajaj, Abir Saraswat, Amitabh Upadhyay, Rajetha Damisetty, Sandipan Dhar ..... 109

### Use of patch testing for identifying allergen causing chronic urticaria

Ashimav Deb Sharma ..... 114

### Vitiligoid lichen sclerosis: A reappraisal

Venkat Ratnam Attali, Sasi Kiran Attali ..... 118



**BRIEF REPORTS**

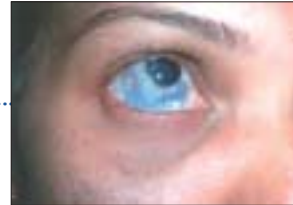**Activated charcoal and baking soda to reduce odor associated with extensive blistering disorders**

Arun Chakravarthi, C. R. Srinivas, Anil C. Mathew ..... 122



**Nevus of Ota: A series of 15 cases**

Shanmuga Sekar, Maria Kuruvila, Harsha S. Pai ..... 125



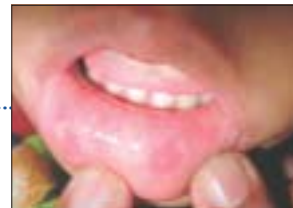**Premature ovarian failure due to cyclophosphamide: A report of four cases in dermatology practice**

Vikrant A. Saoji ..... 128

**CASE REPORTS**

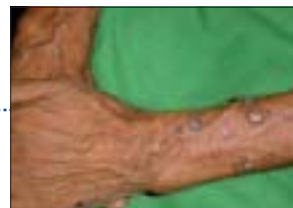**Hand, foot and mouth disease in Nagpur**

Vikrant A. Saoji ..... 133



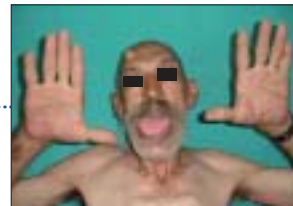**Non-familial multiple keratoacanthomas in a 70 year-old long-term non-progressor HIV-seropositive man**

Hemanta Kumar Kar, Sunil T. Sabhnani, R. K. Gautam, P. K. Sharma, Kalpana Solanki, Meenakshi Bhardwaj ..... 136



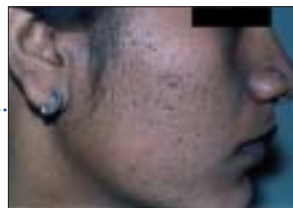**Late onset isotretinoin resistant acne conglobata in a patient with acromegaly**

Kapil Jain, V. K. Jain, Kamal Aggarwal, Anu Bansal ..... 139



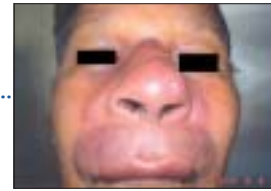**Familial dyskeratotic comedones**

M. Sendhil Kumaran, Divya Appachu, Elizabeth Jayaseelan ..... 142



**Nasal NK/T cell lymphoma presenting as a lethal midline granuloma**

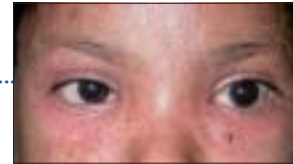Vandana Mehta, C. Balachandran, Sudha Bhat, V. Geetha, Donald Fernandes .....



145

**Childhood sclerodermatomyositis with generalized morphea**

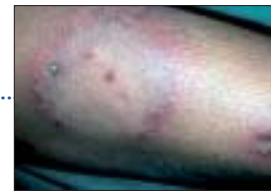Girishkumar R. Ambade, Rachita S. Dhurat, Nitin Lade, Hemangi R. Jerajani.....



148

**Subcutaneous panniculitis-like T-cell cutaneous lymphoma**

Avninder Singh, Joginder Kumar, Sujala Kapur, V. Ramesh.....



151

**LETTERS TO EDITOR**

**Using a submersible pump to clean large areas of the body with antiseptics**

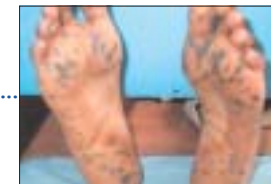C. R. Srinivas .....



154

**Peutz-Jeghers syndrome with prominent palmoplantar pigmentation**

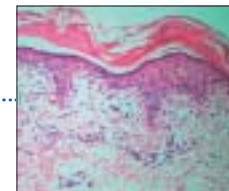
K. N. Shivaswamy, A. L. Shyamprasad, T. K. Sumathi, C. Ranganathan .....



154

**Stratum corneum findings as clues to histological diagnosis of pityriasis lichenoides chronica**

Rajiv Joshi .....



156

**Author's reply**

S. Pradeep Nair .....

157

**Omalizumab in severe chronic urticaria**

K. V. Godse.....

157

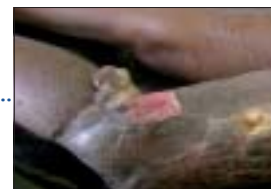**Hypothesis: The potential utility of topical eflornithine against cutaneous leishmaniasis**

M. R. Namazi .....

158

**Nodular melanoma in a skin graft site scar**

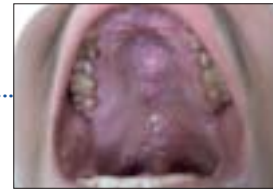A. Gnaneshwar Rao, Kamal K. Jhamnani, Chandana Konda .....



159

**Palatal involvement in lepromatous leprosy**

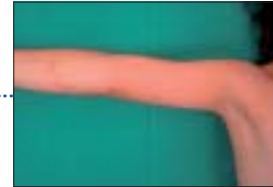A. Gnaneshwar Rao, Chandana Konda, Kamal Jhamnani.....



161

**Unilateral nevoid telangiectasia with no estrogen and progesterone receptors in a pediatric patient**

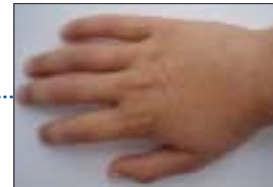F. Sule Afsar, Ragip Ortac, Gulden Diniz.....



163

**Eruptive lichen planus in a child with celiac disease**

Dipankar De, Amrinder J. Kanwar.....



164

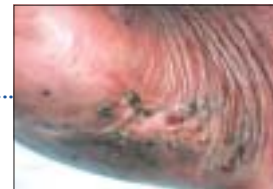**Xerosis and pityriasis alba-like changes associated with zonisamide**

Feroze Kaliyadan, Jayasree Manoj, S. Venkitakrishnan.....

165

**Treatment of actinomycetoma with combination of rifampicin and co-trimoxazole**

Rajiv Joshi.....



166

**Author's reply**

M. Ramam, Radhakrishna Bhat, Taru Garg, Vinod K. Sharma, R. Ray, M. K. Singh, U. Banerjee, C. Rajendran.....

168

**Vitiligo, psoriasis and imiquimod: Fitting all into the same pathway**

Bell Raj Eapen.....

169

**Author's reply**

Engin Şenel, Deniz Seçkin.....

169

**Multiple dermatofibromas on face treated with carbon dioxide laser: The importance of laser parameters**

Kabir Sardana, Vijay K. Garg.....

170

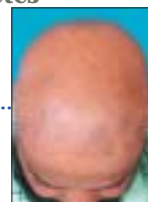**Author's reply**

D. S. Krupa Shankar, A. Kushalappa, K. S. Uma, Anjay A. Pai.....

170

**Alopecia areata progressing to totalis/universalis in non-insulin dependent diabetes mellitus (type II): Failure of dexamethasone-cyclophosphamide pulse therapy**

Virendra N. Sehgal, Sambit N. Bhattacharya, Sonal Sharma, Govind Srivastava, Ashok K. Aggarwal.....



171

**Subungual exostosis**

Kamal Aggarwal, Sanjeev Gupta, Vijay Kumar Jain, Amit Mital, Sunita Gupta.....

173

**Clinicohistopathological correlation of leprosy**

Amrish N. Pandya, Hemali J. Tailor ..... 174

**RESIDENT'S PAGE**

**Dermatographism**

Dipti Bhute, Bhavana Doshi, Sushil Pande, Sunanda Mahajan, Vidya Kharkar ..... 177

**FOCUS**

**Mycophenolate mofetil**

Amar Surjushe, D. G. Saple ..... 180

**QUIZ**

**Multiple papules on the vulva**

G. Raghu Rama Rao, R. Radha Rani, A. Amareswar, P. V. Krishnam  
Raju, P. Raja Kumari, Y. Hari Kishan Kumar ..... 185



**E-IDVL**

**Net Study**

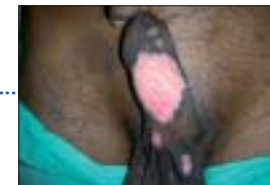**Oral isotretinoin is as effective as a combination of oral isotretinoin and topical anti-acne agents in nodulocystic acne**

Rajeev Dhir, Neetu P. Gehi, Reetu Agarwal, Yuvraj E. More ..... 187

**Net Case**

**Cutaneous diphtheria masquerading as a sexually transmitted disease**

T. P. Vetrichevvel, Gajanan A. Pise, Kishan Kumar Agrawal,  
Devinder Mohan Thappa ..... 187



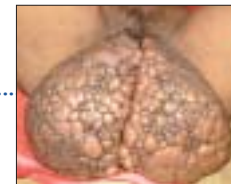**Net Letters**

**Patch test in Behcet's disease**

Ülker Gül, Müzeyyen Gönül, Seray Külcü Çakmak, Arzu Kılıç ..... 187

**Cerebriform elephantiasis of the vulva following tuberculous lymphadenitis**

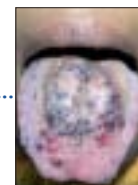Surajit Nayak, Basanti Acharjya, Basanti Devi, Satyadarshi Pattnaik,  
Manoj Kumar Patra ..... 188



**Net Quiz**

**Vesicles on the tongue**

Saurabh Agarwal, Krishna Gopal, Binay Kumar ..... 188



## Author's reply

Sir,

We thank Dr. Joshi for his interest in our paper and his thoughtful comments about the management of actinomycetomas. There is a great need for more sensitive diagnostic tests that will confirm the presence of mycetoma. Although the clinical presentation is characteristic in many cases, laboratory diagnosis is required to know if mycetoma is eumycotic or actinomycotic. In addition, identification of the organism causing actinomycetoma may lead to better-directed therapy using drugs effective against the isolated bacterium.

Fortunately, many of the different organisms causing actinomycetoma are susceptible to the same drugs, making it possible to embark on treatment even if the antibiotic sensitivity of the causative organism is not known. While there are no randomized studies comparing monotherapy with combination therapy, observational studies show that the latter is more effective.<sup>[1]</sup> The usefulness of combination treatments was demonstrated in a fairly large group of 144 patients with actinomycetoma. In that study, the most effective combinations were streptomycin plus co-trimoxazole and streptomycin plus daspone.<sup>[1]</sup> Other studies in smaller groups of patients have also identified treatments useful in this disorder;<sup>[2]</sup> these combinations are likely to be effective in most patients. But clearly, more work is necessary.

It is true that admission to a hospital places financial strain on patients and may lead to drop-outs. However, in our study, all the drop-outs occurred after discharge from hospital. Nevertheless, admission can be avoided if gentamicin is injected intramuscularly in the intensive phase of the schedule described in our paper.<sup>[3]</sup> The pharmacokinetics of gentamicin after intravenous and intramuscular administration appear to be similar.<sup>[4]</sup> Since administration of the drug and monitoring for toxicity is familiar to medical practitioners, it may be possible for the patient to receive injections from any medical facility near his home. After 4 weeks, the patient can be switched to the maintenance phase, which requires oral medications alone.

The response to combination therapy with rifampicin and co-trimoxazole in the reported patient is impressive. If results are similar in a larger number of patients, it would be a useful addition to the treatments available for this neglected disease. Careful clinical evaluation and a chest X-ray to exclude concurrent tuberculosis would, of course, be mandatory to avoid inadvertently administering rifampicin monotherapy for tuberculosis in people who have both infections.<sup>[5]</sup>

**M. Ramam, Radhakrishna Bhat, Taru Garg,  
Vinod K. Sharma, R. Ray<sup>1</sup>, M. K. Singh<sup>1</sup>,  
U. Banerjee<sup>2</sup>, C. Rajendran<sup>3</sup>**

Departments of Dermatology and Venereology, <sup>1</sup>Pathology,  
<sup>2</sup>Microbiology, <sup>3</sup>Mycology, All India Institute of Medical Sciences,  
New Delhi, India

**Address for correspondence:** M. Ramam, Department of Dermatology  
and Venereology, All India Institute of Medical Sciences, New Delhi -  
110 029, India. E-mail: mramam@hotmail.com

## REFERENCES

1. Mahgoub ES. Medical management of mycetoma. Bull WHO 1976;54:303-9.
2. Desai SC, Pardanani DS, Kher YR, Mehta RS, Sreedevi N, Wagle UD, *et al.* Therapeutic investigations on actinomycetomas. Indian J Surg 1970;32:448-61.
3. Ramam M, Bhat R, Garg T, Sharma VK, Ray R, Singh MK, *et al.* A modified two-step treatment for actinomycetomas. Indian J Dermatol Venereol Leprol 2007;73:235-9.
4. Gerner O, Harari D, Mishal J, Segal S. Comparative pharmacokinetics of once daily intravenous and intramuscular gentamicin in patients with post partum endometritis. Arch Gynecol Obstet 2001;265:34-35.
5. Fahal AH, Azziz KA, Saliman SH, Galib HV, Mahgoub S. Dual infection with mycetoma and tuberculosis: Report of two cases. East Afr Med J 1995;72:749-50.