

A six year-old girl with several skeletal deformities and cutaneous lesions

Mahnaz Banihashemi, Mohammad Javad Yazdanpanah, Fakhralzaman Pezeshkpoor

Department of Dermatology, Mashhad University of Medical Sciences, Mashhad, Iran.

Address for correspondence: Dr. Mahnaz Banihashemi, Ahmmd Abad Ave, Ghaem Hospital, Department of Dermatology, Mashhad University of Medical Sciences, Mashhad, Iran. E-mail: dr_banihaashemi@yahoo.com

A six year-old girl with normal mental development presented with unilateral, atrophic patches since birth, short stature and scoliosis. There was no history of similar complaints in the family. On examination, we found multiple atrophic patches distributed along Blaschko's lines [Figure 1], yellowish soft nodules and telangiectasia on her body surface. She also had limb deformities, scoliosis, bilateral syndactyly, and absence of toes of the right foot. Her hair and nails were normal; her teeth were hypoplastic and multiple

papillomas were seen on the buccal mucosa. Examination of the eyes revealed an iris coloboma and an obstructed right tear duct. Biopsy of a yellowish nodule showed a remarkably thinned dermis occupied by adipose tissue [Figure 2]. X-rays showed hypoplasia of the right ankle and right clavicle and aplasia of right fibula.

WHAT IS YOUR DIAGNOSIS?

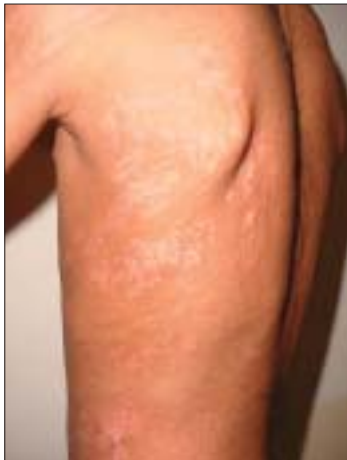

Figure 1: Multiple atrophic patches distributed along Blaschko's lines

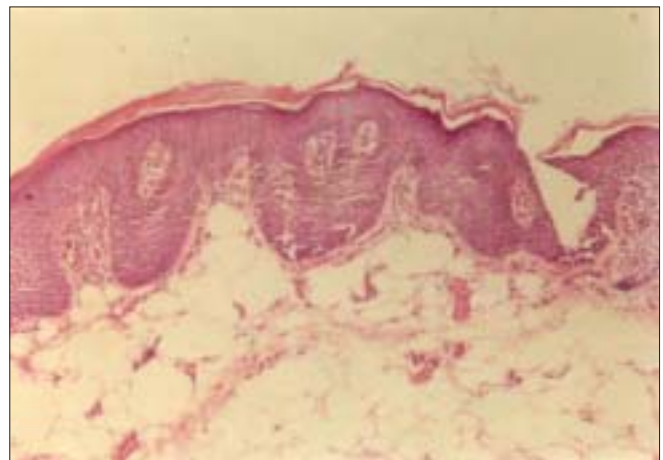


Figure 2: Remarkable decrease in thickness of dermis (H & E, x100)

How to cite this article: Banihashemi M, Yazdanpanah MJ, Pezeshkpoor F. A six year-old girl with several skeletal deformities and cutaneous lesions. *Indian J Dermatol Venereol Leprol* 2008;74:427-8.

Received: June, 2007. **Accepted:** October, 2007. **Source of Support:** Nil. **Conflict of Interest:** None Declared.

Diagnosis: Focal Dermal Hypoplasia (Goltz syndrome)

Focal dermal hypoplasia (FDH) or Goltz syndrome is characterized by multiple abnormalities of the mesodermal and ectodermal tissue. As a result, patients suffer from cutaneous, bone, oral, dental and ocular disorders. This case had typical linear skin atrophy on the trunk, exuberant “fat herniations,” iris coloboma and several skeletal abnormalities such as severe scoliosis, severe hypoplasia of the right ankle, an underdeveloped right clavicle and aplasia of the right fibula.

DISCUSSION

Focal dermal hypoplasia or Goltz syndrome is a rare congenital and mesoectodermal dysplasia with multisystemic involvement. Most of the reported cases are sporadic and males are only rarely affected by this syndrome. The genetic alterations responsible for focal dermal hypoplasia are not fully known, but due to the preponderance of female patients, inheritance is thought to be X-linked dominant, although the causative gene is unknown. Characteristic cutaneous features include asymmetric linear streaks of atrophy, linear hypo- or hyperpigmentation along the lines of Blasckho; fat herniation and telangiectasia usually present at birth.^[1]

Oral manifestations are regular findings in FDH including multiple papillomas of the mucous membranes besides other oral and dental abnormalities. Enamel hypoplasia is the most commonly reported dental manifestation. Other features include oligodontia, microdontia, delayed eruption, and extra teeth.^[2] Ocular abnormalities are common and include coloboma, strabismus, microphthalmus, anophthalmia, keratoconus, and corneal opacification.^[1]

Skeletal anomalies have been seen in 60% of the patients and include asymmetric involvement of the hands and feet, syndactyly especially between the third and fourth fingers,

ectrodactyly, polydactyly, absence or hypoplasia of digits. The face, trunk and limbs may be asymmetrical. Cervical rib or absence of the left first rib has been reported. Short stature and slender build are usual.^[1,3] Scoliosis occurs in 20% of the cases; clavicular dysplasia and spina bifida occulta can also occur. Typical “lobster claw” deformity is a hallmark of Goltz syndrome but was not present in our patient.^[3,4]

The characteristic radiological change seen in this syndrome is osteopathia striata of the long bones; it is not a pathognomonic radiographic sign but it was considered of great value for our FDH diagnosis.^[4,5] Internal organ abnormalities are only present in 10% of all cases. Cardiac anomalies, horse-shoe kidneys, umbilical, inguinal, epigastric, or diaphragmatic hernias and intestinal malrotation and mediastinal dextroposition have been reported.^[1] Such patients often require reconstructive surgery and skin lesions can be improved cosmetically with laser treatment.^[1]

FDH is diagnosed most frequently at birth. Our patient had all the typical features of Goltz syndrome with multiple skeletal abnormalities.

REFERENCES

1. Harper JI, Trembath RC. Genetics and genodermatoses. In: Burns T, Breathnach S, Cox N, *et al*, editors. Rook's text book of dermatology. Black Well Science; 2004. p. 12,69-70.
2. Al-Guamdi K, Crawford PJ. Focal dermal hypoplasia-oral and dental findings. *Int J Paediatr Dent* 2003;13:121–6.
3. Riyaz N, Riyaz A, Chandran R, Rakesh SV. Focal Dermal Hypoplasia (Goltz syndrome). *Indian J Dermatol Venereol Leprol* 2005;71:279-81.
4. Goltz RW. Focal dermal hypoplasia syndrome: An update. *Arch Dermatol* 1992;128:1108–10.
5. Mianda SB, Delmaestro D, Bertoli R, Marinho T, Lucas E. Focal dermal hypoplasia with exuberant fat herniations and skeletal deformities. *Pediatr Dermatol* 2005;22:420-3.