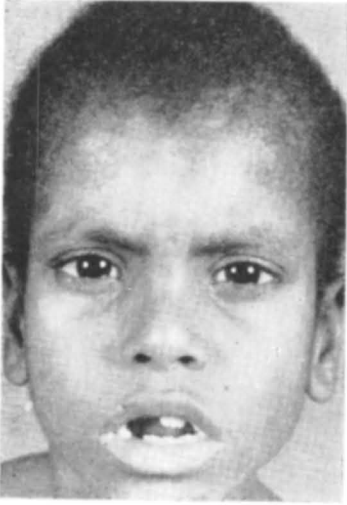
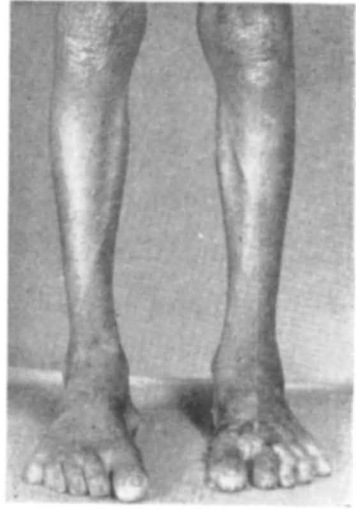
## WHAT IS YOUR DIAGNOSIS ?



**Fig. 1**

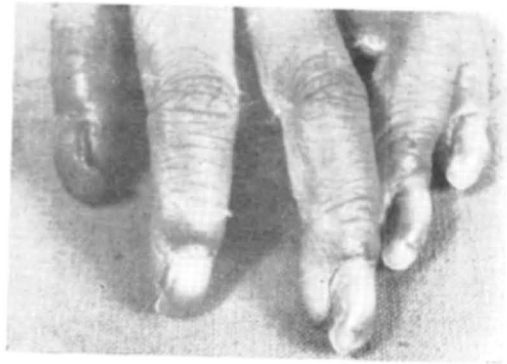


**Fig. 2**

Fig. 1: Showing kinky hair and leucokeratosis.

Fig. 2: Showing hyperkeratosis on knee and follicular hyperkeratosis on legs

Fig. 3: Curved and thickened nails



**Fig. 3**

### **Differential Diagnoses :**

1. Pityriasis Rubra Pilaris
2. Follicular Ichthyosis
3. Pachyonychia Congenita
4. Epidermolysis Bullosa dystrophica

*(Diagnosis overleaf)*

## **DIAGNOSIS**

The combination of kinky hair, leucokeratosis, follicular hyperkeratosis, curved and dystrophic nails makes this a case of Pachyonychia Congenita.

This is an 8 year old male child, one of 10 children born to consanguinous parents who was noticed to have thickened nails and kinky hair at birth. Since early childhood he suffered from painful blisters on hands and feet. One of his siblings died at the age of three years had similar skin problem. Another sibling has anonychia. Two other siblings have widespread follicular hyperkeratosis.