

Indian Journal of Dermatology, Venereology & Leprology

Journal indexed with SCI-E, PubMed, and EMBASE

Vol 74 | Issue 2 | Mar-Apr 2008

C O N T E N T S

EDITORIAL

Management of autoimmune urticaria

Arun C. Inamadar, Aparna Palit 89

VIEW POINT

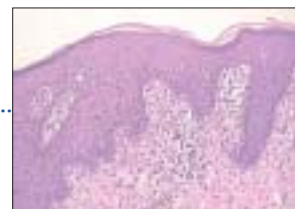Cosmetic dermatology versus cosmetology: A misnomer in need of urgent correction

Shyam B. Verma, Zoe D. Draelos 92

REVIEW ARTICLE

Psoriasiform dermatoses

Virendra N. Sehgal, Sunil Dogra, Govind Srivastava, Ashok K. Aggarwal 94



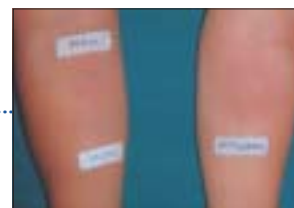ORIGINAL ARTICLES

A study of allergen-specific IgE antibodies in Indian patients of atopic dermatitis

V. K. Somani 100

Chronic idiopathic urticaria: Comparison of clinical features with positive autologous serum skin test

George Mamatha, C. Balachandran, Prabhu Smitha 105



Autologous serum therapy in chronic urticaria: Old wine in a new bottle

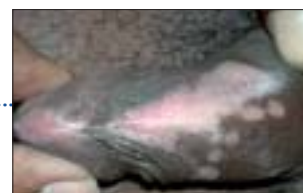A. K. Bajaj, Abir Saraswat, Amitabh Upadhyay, Rajetha Damisetty, Sandipan Dhar 109

Use of patch testing for identifying allergen causing chronic urticaria

Ashimav Deb Sharma 114

Vitiligoid lichen sclerosus: A reappraisal

Venkat Ratnam Attali, Sasi Kiran Attali 118



BRIEF REPORTS

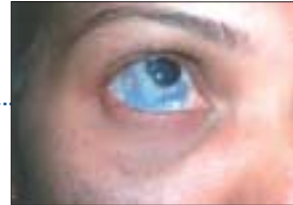Activated charcoal and baking soda to reduce odor associated with extensive blistering disorders

Arun Chakravarthi, C. R. Srinivas, Anil C. Mathew 122



Nevus of Ota: A series of 15 cases

Shanmuga Sekar, Maria Kuruvila, Harsha S. Pai 125



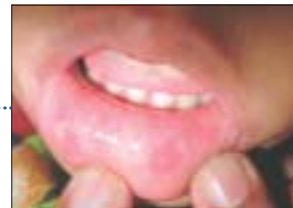Premature ovarian failure due to cyclophosphamide: A report of four cases in dermatology practice

Vikrant A. Saoji 128

CASE REPORTS

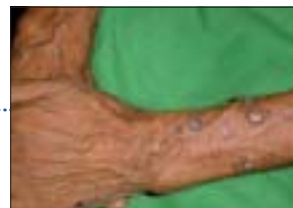Hand, foot and mouth disease in Nagpur

Vikrant A. Saoji 133



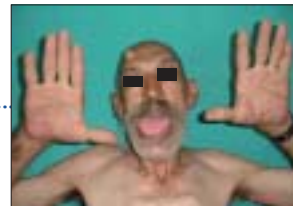Non-familial multiple keratoacanthomas in a 70 year-old long-term non-progressor HIV-seropositive man

Hemanta Kumar Kar, Sunil T. Sabhnani, R. K. Gautam, P. K. Sharma, Kalpana Solanki, Meenakshi Bhardwaj 136



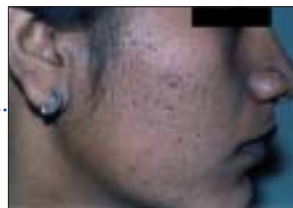Late onset isotretinoin resistant acne conglobata in a patient with acromegaly

Kapil Jain, V. K. Jain, Kamal Aggarwal, Anu Bansal 139



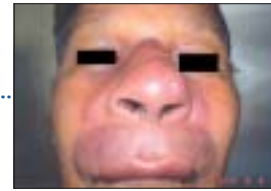Familial dyskeratotic comedones

M. Sendhil Kumaran, Divya Appachu, Elizabeth Jayaseelan 142



Nasal NK/T cell lymphoma presenting as a lethal midline granuloma

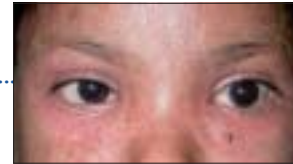Vandana Mehta, C. Balachandran, Sudha Bhat, V. Geetha, Donald Fernandes



145

Childhood sclerodermatomyositis with generalized morphea

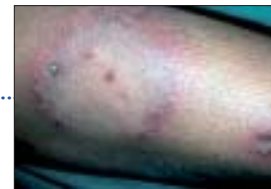Girishkumar R. Ambade, Rachita S. Dhurat, Nitin Lade, Hemangi R. Jerajani.....



148

Subcutaneous panniculitis-like T-cell cutaneous lymphoma

Avninder Singh, Joginder Kumar, Sujala Kapur, V. Ramesh.....



151

LETTERS TO EDITOR

Using a submersible pump to clean large areas of the body with antiseptics

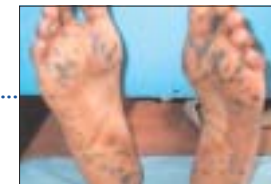C. R. Srinivas



154

Peutz-Jeghers syndrome with prominent palmoplantar pigmentation

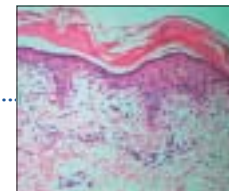
K. N. Shivaswamy, A. L. Shyamprasad, T. K. Sumathi, C. Ranganathan



154

Stratum corneum findings as clues to histological diagnosis of pityriasis lichenoides chronica

Rajiv Joshi



156

Author's reply

S. Pradeep Nair

157

Omalizumab in severe chronic urticaria

K. V. Godse.....

157

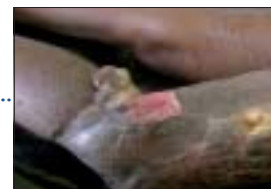Hypothesis: The potential utility of topical eflornithine against cutaneous leishmaniasis

M. R. Namazi

158

Nodular melanoma in a skin graft site scar

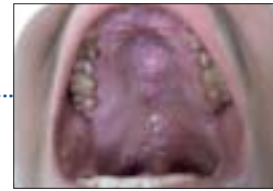A. Gnaneshwar Rao, Kamal K. Jhamnani, Chandana Konda



159

Palatal involvement in lepromatous leprosy

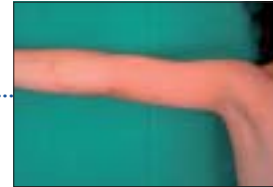A. Gnaneshwar Rao, Chandana Konda, Kamal Jhamnani.....



161

Unilateral nevoid telangiectasia with no estrogen and progesterone receptors in a pediatric patient

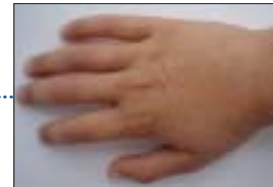F. Sule Afsar, Ragip Ortac, Gulden Diniz.....



163

Eruptive lichen planus in a child with celiac disease

Dipankar De, Amrinder J. Kanwar.....



164

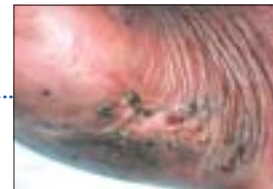Xerosis and pityriasis alba-like changes associated with zonisamide

Feroze Kaliyadan, Jayasree Manoj, S. Venkitakrishnan.....

165

Treatment of actinomycetoma with combination of rifampicin and co-trimoxazole

Rajiv Joshi.....



166

Author's reply

M. Ramam, Radhakrishna Bhat, Taru Garg, Vinod K. Sharma, R. Ray, M. K. Singh, U. Banerjee, C. Rajendran.....

168

Vitiligo, psoriasis and imiquimod: Fitting all into the same pathway

Bell Raj Eapen.....

169

Author's reply

Engin Şenel, Deniz Seçkin.....

169

Multiple dermatofibromas on face treated with carbon dioxide laser: The importance of laser parameters

Kabir Sardana, Vijay K. Garg.....

170

Author's reply

D. S. Krupa Shankar, A. Kushalappa, K. S. Uma, Anjay A. Pai.....

170

Alopecia areata progressing to totalis/universalis in non-insulin dependent diabetes mellitus (type II): Failure of dexamethasone-cyclophosphamide pulse therapy

Virendra N. Sehgal, Sambit N. Bhattacharya, Sonal Sharma, Govind Srivastava, Ashok K. Aggarwal.....



171

Subungual exostosis

Kamal Aggarwal, Sanjeev Gupta, Vijay Kumar Jain, Amit Mital, Sunita Gupta.....

173

Clinicohistopathological correlation of leprosy

Amrish N. Pandya, Hemali J. Tailor 174

RESIDENT'S PAGE

Dermatographism

Dipti Bhute, Bhavana Doshi, Sushil Pande, Sunanda Mahajan, Vidya Kharkar 177

FOCUS

Mycophenolate mofetil

Amar Surjushe, D. G. Saple 180

QUIZ

Multiple papules on the vulva

G. Raghu Rama Rao, R. Radha Rani, A. Amareswar, P. V. Krishnam
Raju, P. Raja Kumari, Y. Hari Kishan Kumar 185



E-IDVL

Net Study

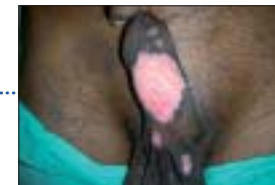Oral isotretinoin is as effective as a combination of oral isotretinoin and topical anti-acne agents in nodulocystic acne

Rajeev Dhir, Neetu P. Gehi, Reetu Agarwal, Yuvraj E. More 187

Net Case

Cutaneous diphtheria masquerading as a sexually transmitted disease

T. P. Vetrichevvel, Gajanan A. Pise, Kishan Kumar Agrawal,
Devinder Mohan Thappa 187



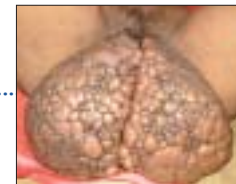Net Letters

Patch test in Behcet's disease

Ülker Gül, Müzeyyen Gönül, Seray Külcü Çakmak, Arzu Kılıç 187

Cerebriform elephantiasis of the vulva following tuberculous lymphadenitis

Surajit Nayak, Basanti Acharjya, Basanti Devi, Satyadarshi Pattnaik,
Manoj Kumar Patra 188



Net Quiz

Vesicles on the tongue

Saurabh Agarwal, Krishna Gopal, Binay Kumar 188



Nodular melanoma in a skin graft site scar

Sir,

Nodular melanoma is the second most common subtype of cutaneous melanomas with a frequency of 15-30%.^[1] Most frequently it presents in midlife with a median age at presentation of 53 years, it is more common in males than in females. Recognition of nodular melanomas can be problematic as they lack many of the conventional clinical features.

A 47 year-old man was referred to the Dermatology Department with complaints of a nonhealing ulcer over the right thigh and popliteal fossa prevalent since the last two years and also, nodules over the right lower limb extending up to the ankles observed for the last eight months. The patient was apparently asymptomatic two years before when he met with an accident leading to a nonhealing ulcer over the right thigh. There was no history of any burn injury. The ulcer was treated with skin grafting from the left thigh. The graft site healed well at that time. Gradually over the span of a few months, the patient developed small swellings over the scar of the grafted site. This was followed by ulceration and rapid growth of a fungating mass extending up to the popliteal fossa. This was associated with a serosanguineous discharge. Over the next year, the patient started developing skin-colored nodules over the right lower limb below the growth extending up to the dorsum of the foot. The growth was painless and asymptomatic to start with but

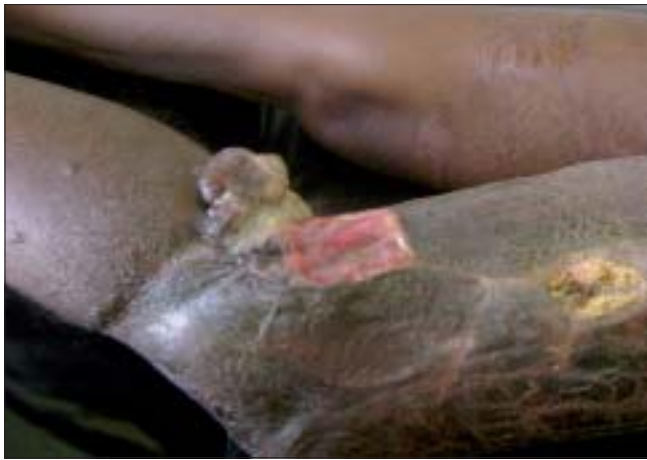

Figure 1: Back of right knee showing ulcerative growth

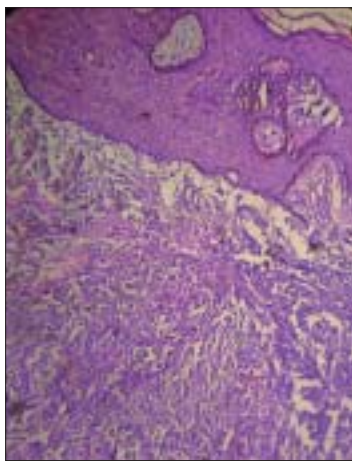


Figure 2: Diffuse dense infiltration by neoplastic cells (H and E, x100)

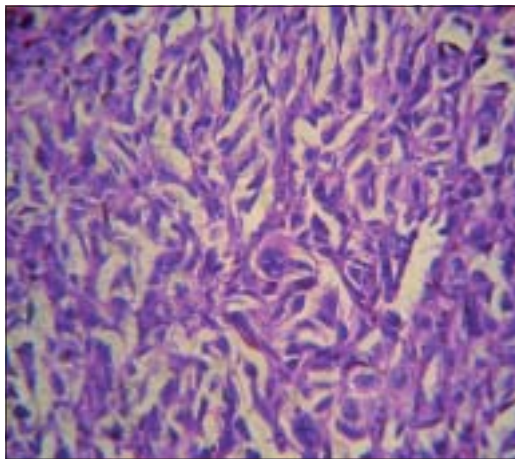


Figure 3: Pleomorphic cells with prominent eosinophilic nucleoli (H and E, x400)

as it grew, it caused pain and limitation of mobility due to pressure effects. The patient was otherwise well with no previous significant medical history. He was addicted to smoking and occasionally consumed alcohol. The general

examination was unremarkable except for edema over the right foot. Cutaneous examination revealed a fungating mass over the right popliteal fossa with interspersed areas of necrosis and a healed ulcer over the lateral aspect of the thigh [Figure 1]. Skin-colored to hyperpigmented nodules distributed over the entire right leg were firm to bony hard in consistency. Regional inguinal lymphadenopathy was present which was bony hard in consistency. With these features, a clinical diagnosis of Marjolin's ulcer was made. Differential diagnoses that were considered included pigmented basal cell carcinoma, eccrine poroma, blue nevus and pyogenic granuloma. Skin biopsy was taken from the edge of the fungating mass and also from the nodule. Histopathological examination revealed extensive areas of necrosis, hemorrhage and tumor tissue with pleomorphic cells and pleomorphic nuclei with prominent eosinophilic nucleoli. Both intra- and extracellular melanin pigment was seen [Figures 2-3]. The specimen revealed mitotic figures and also tumor giant cells. HMB-45 studies were positive. Based on these histopathological findings, a diagnosis of nodular melanoma was made.

Malignant melanoma arising from burn scars are rare with only 27 cases being reported so far.^[2] Malignant melanomas arising in skin grafts are even more rare with only two case reports.^[3] Hall *et al.* reported a case who developed melanoma within a skin graft donor site and an invasive melanoma within the recipient graft site.^[4] Carcinoma developing in burn scars is overwhelmingly of the squamous cell type. In fact, almost 2% of all squamous cell carcinomas develop in old burn scars.^[5] According to recent literature, most of the melanomas have been reported in burn scars with an incidence of about 6% of all burn scar neoplasms. While reviewing 412 burn scar neoplasms, Kowal-Vern *et al.* reported a mean latency interval of 31 years.^[6] The case under study had a latency interval of two years, which is short. Multiple malignant melanomas may develop in different burn scar areas. Hwang *et al.* described a case who developed malignant melanomas at two different sites of burn scars.^[7] Spring *et al.* have reported a case where malignant melanoma developed at the site of excision of a squamous cell carcinoma.^[8] Gamatsi *et al.* have reported a case of malignant melanoma which developed in a burn injury treated with a skin graft. While analyzing the cause of malignant melanoma in grafted skin, the authors opined that the malignant melanoma might have been transferred to the recipient site along with the skin graft.^[9] In view of varied clinical presentation of nodular melanoma, a high index of suspicion is needed in all cases of injuries and burns treated with skin grafts. Such cases need to be followed up periodically so that an early diagnosis can be made and

treated promptly. We have presented this uncommon case to emphasize the importance of follow-up in cases of injury and burns treated with skin grafts.

**A. Gnaneshwar Rao, Kamal K. Jhamnani,
Chandana Konda**

Department of Dermatology, Gandhi Medical College and Hospital,
Musheerabad, Hyderabad, India

Address for correspondence: Dr. A. Gnaneshwar Rao,
F-12, B8, HIG 2, Bagh Lingampally, Hyderabad - 500 044, India.
E-mail: dr_a_g_rao@yahoo.co.in

REFERENCES

1. Raymond L, Barnhill, Mihm MC Jr, Fitzpatrick TB, Sober AJ. Neoplasms: Malignant melanoma. *In:* Fitzpatrick TB, Eisen AZ, Wolff K, Freedberg IM, Austen FK, editors. *Dermatology in general medicine*. 4th ed. Mc Graw-Hill, Inc; 1993. p. 1078-115.
2. Bero, Suzannah M, Busam, Klaus J, Brady, Mary S. Cutaneous melanoma arising in a burn scar: Two recent cases and review of the literature. *Melanoma Res* 2006;16:71-6.
3. McEwan LE, Buchanan MR. Invasive melanoma in the donor and recipient site of Hutchisons freckle transplanted in split skin graft. *Aust NZ J Surg* 1986;56:81-4.
4. Hall, Jennifer G, Herman, Christopher, Cook Jonathan L, Tyler. Melanoma arising in a skin graft. *Ann Plast Surg* 2005;54:92-6.
5. Goldberg NS, Robinson JK, Peterson C. Gigantic malignant melanoma in a thermal burn scar. *J Am Acad Dermatol* 1985;12:949-52.
6. Kowal-vern A, Criswell BK, Sumner L. Burn scar neoplasms: A literature review and statistical analysis. *Burns* 2005; 31:403-13.
7. Hwang K, Han JY, Lee SI. Multiple malignant melanomas at different burn scar areas: A case report. *Dermatol Surg* 2004;30:562-5.
8. Spring PM, Myers JN, EL-Naggar AK, Langstein HN. Malignant melanoma arising within burn scar case report and review of literature. *Ann Otol Rhino Laryngol* 2001;110: 369-76.
9. Gamatsi LA, McCulloch TA, Bailie, Srinivasan JR. Malignant melanoma in a skin graft: Burn scar neoplasm or transferred melanoma? *Br J Plast Surg* 2000;53:342-52.