

Symmetrical peripheral gangrene secondary to septic shock induced by *Streptococcus dysgalactiae* subspecies *equisimilis* infection

Dear Editor,

A 72-year-old man presented to the emergency department with a 5-day history of a slight fever and haematochezia. The patient had a past medical history of acquired haemophilia A and hepatocellular carcinoma. On physical examination, he was febrile and in shock (temperature 38.5 degrees, heart rate 110 bpm, systolic blood pressure 50 mmHg). Gastrointestinal endoscopy and a contrast-CT of the abdomen and pelvis were performed but they failed to identify the source of the bleeding or infection. During the endoscopy, he developed aspiration pneumonia and was intubated and admitted to the medical intensive care unit (ICU). He was treated for sepsis empirically with piperacillin–tazobactam. Initial blood examination showed a white blood cell count of $2.4 \times 10^3/\mu\text{L}$, red blood cell count of $351 \times 10^4/\mu\text{L}$, platelet count of $4.7 \times 10^4/\mu\text{L}$, CRP of 15.81 mg/dL, lactate of 5.72 mmol/L, PT INR of 2.4 and fibrinogen of 154 mg/dL. He was given fluid resuscitation, intravenous norepinephrine and vasopressin and a blood transfusion. Continuous venovenous haemodialysis was necessary by the eighth day of admission due to acute renal failure. Blood cultures and a urine culture both grew *Streptococcus dysgalactiae* subspecies *equisimilis* (SDSE). It was noticed that his left shoulder was swollen within the first few days of admission and a shoulder joint aspirate fluid culture also grew SDSE. Piperacillin–tazobactam was substituted with penicillin G and clindamycin. On the sixth day of admission, he developed skin necrosis on the tips of all the fingers and toes [Figures 1a–1d]. Serum protein C activity was 41% (normal range, 64–146%) and protein S activity was 71% (normal range, 67–164%). A biopsy was attempted from the digits; however, a satisfactory sample could not be obtained due to the degree of necrosis. His general condition gradually improved with the treatment and he had his fingers and toes amputated 2 months after admission [Figures 2a–2d and 2e–2h].

Given the clinical presentation over the extremities accompanied by a history of septic shock and evidence of acute clotting disturbance, a diagnosis of symmetrical peripheral gangrene (SPG) was made.

SPG is a life-threatening condition characterised by a triad of shock, disseminated intravascular coagulation (DIC) and anticoagulant depletion.¹ It has been speculated that a reduction in protein C is involved in the aetiopathogenesis.¹ SPG is associated with a high mortality and it has been reported that more than half of the surviving patients required

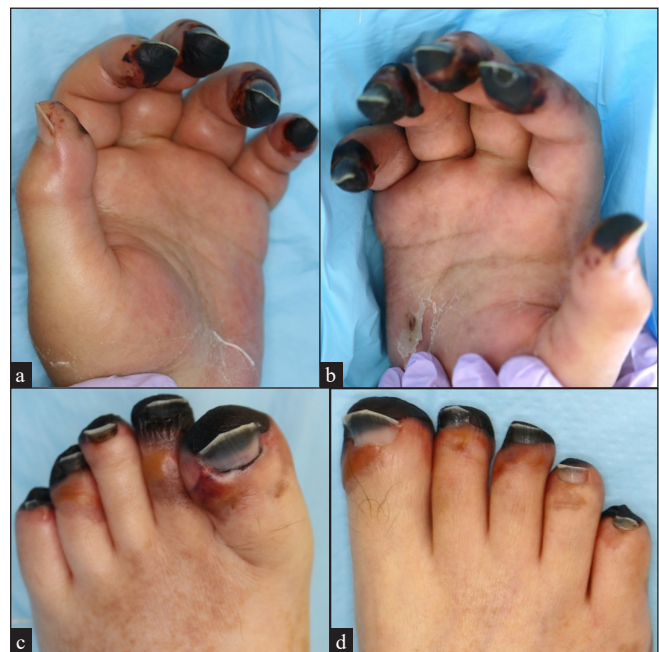

Figure 1a–d: Seventy two-year-old man presenting with peripheral symmetrical gangrene involving all fingers and toes.

How to cite this article: Kondo A, Terashima-Murase C, Hidaka Y, Fukaura R, Kanematsu T, Matsushita T, *et al.* Symmetrical peripheral gangrene secondary to septic shock induced by *Streptococcus dysgalactiae* subspecies *equisimilis* infection. Indian J Dermatol Venereol Leprol. doi: 10.25259/IJDVL_576_2023

Received: June, 2023 **Accepted:** February, 2024 **Epub Ahead of Print:** May, 2024

DOI: 10.25259/IJDVL_576_2023

This is an open-access article distributed under the terms of the Creative Commons Attribution-Non Commercial-Share Alike 4.0 License, which allows others to remix, tweak, and build upon the work non-commercially, as long as the author is credited and the new creations are licensed under the identical terms.

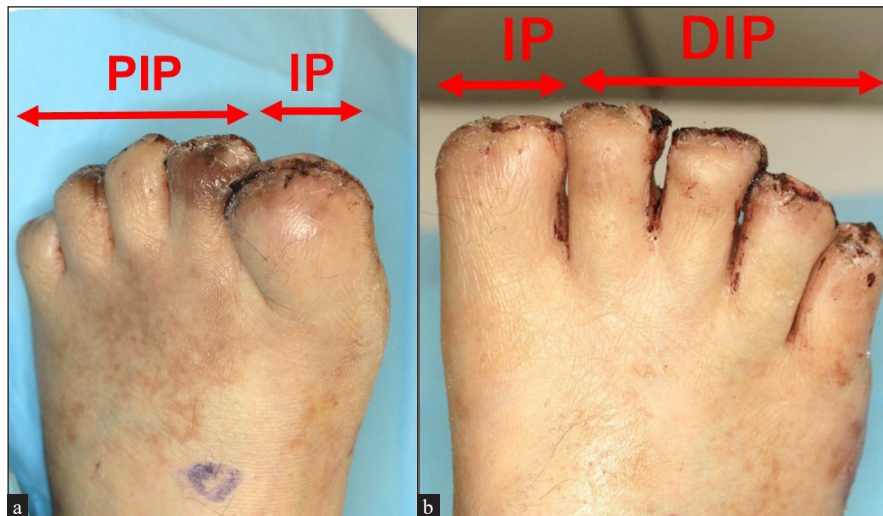


Figure 2a-b: Photographs of both feet following amputation, two weeks after the surgery. The great toe was amputated at the interphalangeal joint and the rest of the toes were amputated at the proximal or distal interphalangeal joints. IP: Interphalangeal joint; DIP: Distal interphalangeal joint.

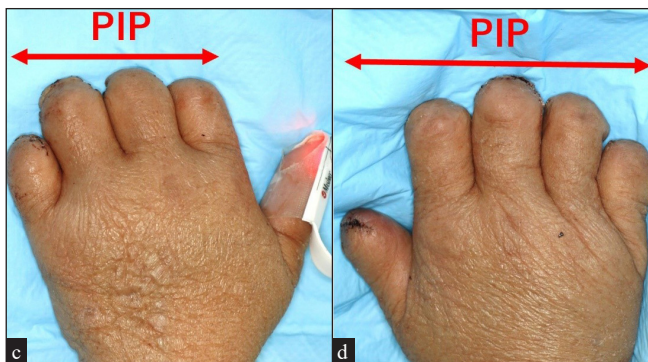


Figure 2c-d: Photographs of both hands following amputation, two weeks after the surgery. The fingers were amputated at the proximal interphalangeal joints. PIP: Proximal interphalangeal joint.

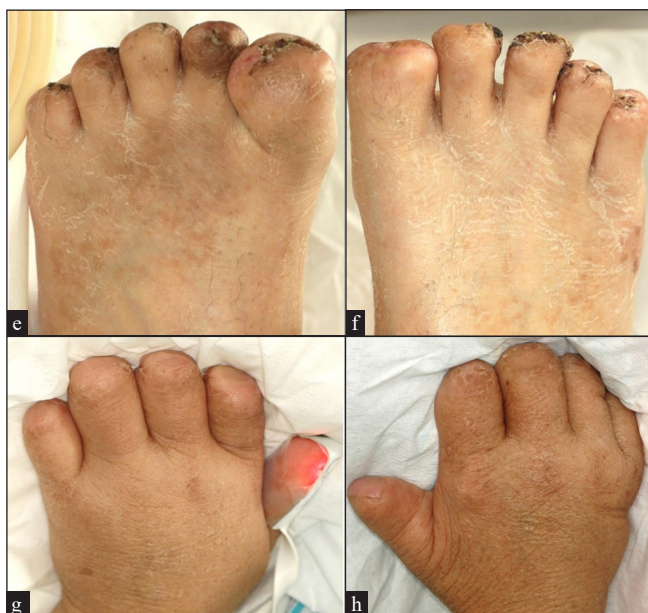

Figure 2e-h: Photographs of the extremities following amputation, seven weeks after the amputation surgery.

amputations of the limbs.^{2,3} In the present case, fortunately, the necrotic area was localised and amputation at the level of interphalangeal joints was adequate.

Many causes for SPG have been identified. Non-infectious causes include acute or chronic liver disease and iatrogenic causes including vasopressor use and colloidal transfusions.^{1,2} Various infective agents have been reported to be associated with SPG, including common agents such as *Pneumococci*, and *E. coli* and rare agents such as *Serratia marcescens* and SARS-CoV-2.³⁻⁶ The exact incidence of these causative factors cannot be determined due to the rarity of SPG, but it has been suggested that pneumococcal sepsis is the most common infectious cause of SPG with one study reporting its association with 28.5% of cases.⁴ In the same study, *E. coli* was found to be associated with 14.3% of cases.⁴ Our patient had SDSE infection which has not been reported to be associated with SPG previously. SDSE is a group C or G β -hemolytic streptococci that resides in the human nasopharynx, skin and perineum. Several clinical case series have reported SDSE infections to be more common among elder adults and in individuals with underlying chronic illnesses. SDSE has been implicated in a wide variety of human infections and the incidence of invasive disease due to SDSE may be increasing.⁷ Because of these characteristics, we envisage SDSE infections to become a significant health burden in the near future, given the ageing population in developed countries. The present case highlights the importance of rapid identification of SDSE, as it has the potential to cause extremely serious complications with high mortality like SPG.

Declaration of patient consent

The authors certify that they have obtained all appropriate patient consent.

Financial support and sponsorship

Nil.

Conflicts of interest

Dr Matsushita declares COI from Chugai, NOVO Nordisk, Takeda, Bayer, Sanofi, CSL, JB, KMB, Fujimoto, Sysmex, JSTH and JSTMCT. Dr Kanematsu declares COI from Sanofi, Bayer, Chugai, NOVO Nordisk and JB.

Use of artificial intelligence (AI)-assisted technology for manuscript preparation

The authors confirm that there was no use of artificial intelligence (AI)-assisted technology for assisting in the writing or editing of the manuscript and no images were manipulated using AI.

***Ayako Kondo, Chaki Terashima-Murase,
Yuri Hidaka, Ryo Fukaura, Takeshi Kanematsu,
Tadashi Matsushita, Masahi Akiyama***

Department of Dermatology, Nagoya University Graduate School of
Medicine, Showa-ku, Nagoya, Aichi-ken, Japan.

Corresponding author:

Prof. Masahi Akiyama,
Department of Dermatology, Nagoya University Graduate School
of Medicine, Showa-ku, Nagoya, Aichi-ken, Japan.
makiyama@med.nagoya-u.ac.jp

References

1. Warkentin TE, Ning S. Symmetrical peripheral gangrene in critical illness. *Transfus Apher Sci* 2021;60:103094.
2. Kwon JW, Hong MK, Park BY. Risk factors of vasopressor-induced symmetrical peripheral gangrene. *Ann Plast Surg* 2018;80:622–627.
3. Shimbo K, Yokota K, Miyamoto J, Okuhara Y, Ochi M. Symmetrical peripheral gangrene caused by septic shock. *Case Reports Plast Surg Hand Surg* 2015;28:53–56.
4. Ghosh SK, Bandyopadhyay D, Ghosh A. Symmetrical peripheral gangrene: A prospective study of 14 consecutive cases in a tertiary-care hospital in eastern India. *J Eur Acad Dermatol Venereol* 2010;24:214–218.
5. Okochi S, Murase C, Akiyama M. Symmetrical peripheral gangrene in a patient with septic shock due to *Serratia marcescens*. *J Dermatol* 2022;49:e181–e182.
6. Sil A, Chakraborty U, Chandra A, Biswas SK. COVID-19 associated symmetrical peripheral gangrene: A case series. *Diabetes Metab Syndr* 2022;16:102356.
7. Lother S, Demczuk W, Martin I, Mulvey M, Dufault B, Lagacé-Wiens P, *et al.* Clonal clusters and virulence factors of group C and G streptococcus causing severe infections, Manitoba, Canada, 2012–2014. *Emerg Infect Dis* 2017;23:1079–1088.