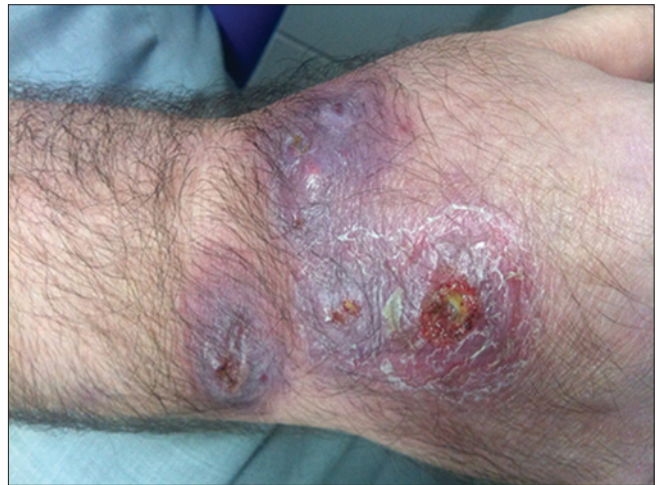

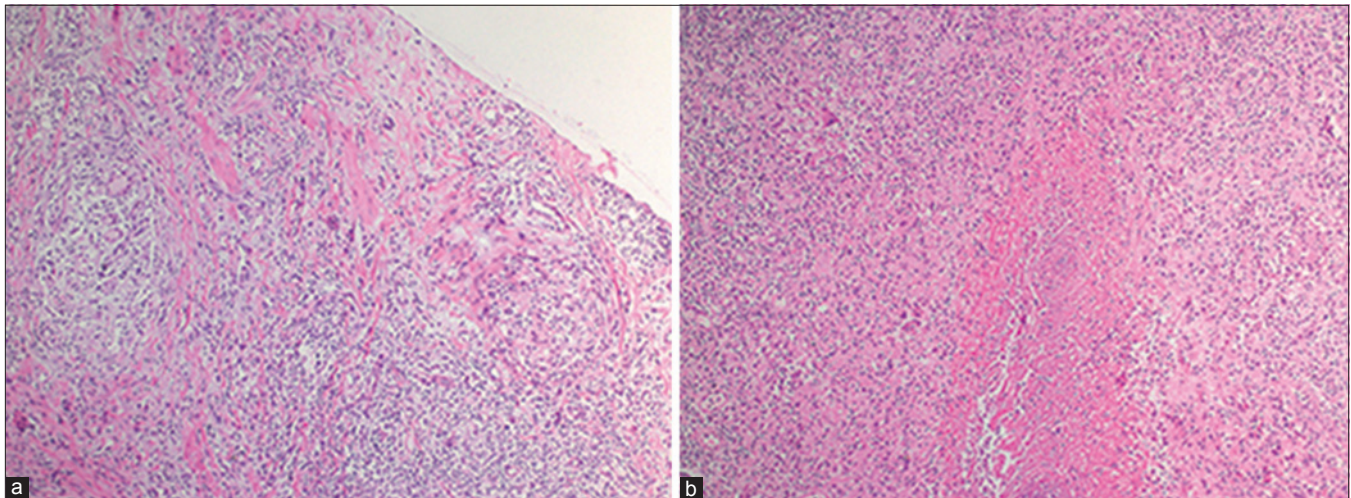
## Chronic subcutaneous nodules, plaques and ulcers of the hand

A 54-year-old man presented with multiple draining sinuses on the right hand for 2 years. Dermatological examination revealed erythematous nodules and pustules leading to draining abscesses localized on the dorsal aspect of the right hand [Figure 1]. The infection had not responded to several courses of antibiotics. There was no history of trauma or foreign body. A punch biopsy was performed for histopathological, bacteriological, mycobacterial, parasitological and mycological examinations. Routine bacterial, fungal and parasitological cultures were negative. Histopathological examination revealed granulomas along with an infiltrate of lymphocytes. Areas of caseous necrosis surrounded by histiocytes and multinucleated giant cells were observed [Figure 2].

### WHAT IS YOUR DIAGNOSIS?



**Figure 1:** Erythematous nodules and pustules leading to draining abscesses localized on the dorsal aspect of the right hand



**Figure 2:** (a) Granulomas with lymphocytic infiltrates in the soft tissue (H and E,  $\times 100$ ). (b) Caseous necrosis areas surrounded by histiocytes and multinucleated giant cells (H and E,  $\times 100$ )

Access this article online	
Quick Response Code:	Website: www.ijdvl.com
	DOI: 10.4103/0378-6323.187092

This is an open access article distributed under the terms of the Creative Commons Attribution-NonCommercial-ShareAlike 3.0 License, which allows others to remix, tweak, and build upon the work non-commercially, as long as the author is credited and the new creations are licensed under the identical terms.

**For reprints contact:** reprints@medknow.com

**How to cite this article:** Ermertcan AT, Özkütük N, Temiz P, Çavuşoğlu C, Sürücüoğlu S. Chronic subcutaneous nodules, plaques and ulcers of the hand. *Indian J Dermatol Venereol Leprol* 2017;83:133-5.

**Received:** August, 2015. **Accepted:** February, 2016.

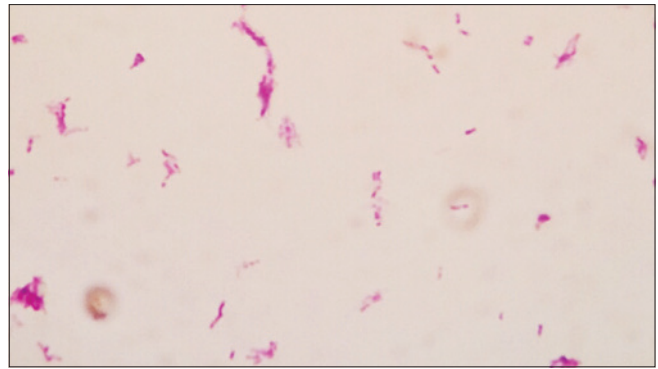
**ANSWER****Fish tank granuloma of the hand caused by *Mycobacterium marinum***

Following detailed histopathological and mycobacterial studies, we diagnosed *Mycobacterium marinum* infection. No acid-fast bacilli were found on Ziehl–Neelsen staining of skin biopsy specimens. Specimens were cultured on two sets of BACTEC MGIT (Becton Dickinson, Sparks, MD, USA) and Lowenstein-Jensen media at 30°C and 37°C for mycobacteria. Growth did not occur at 37°C, but MGIT incubated at 30°C grew acid-fast bacilli [Figure 3]. The GenoType Mycobacterium CM and AS assays (HainLifescience GmbH, Nehren, Germany) were jointly employed for the identification of the isolate grown in culture. The results of identification were indicative of *M. marinum* [Figure 4]. The sequence analysis of the Hsp65 and 16S rRNA gene were performed for confirmation of diagnosis of *M. marinum* and the result of sequencing matched (100%) with *M. marinum*.

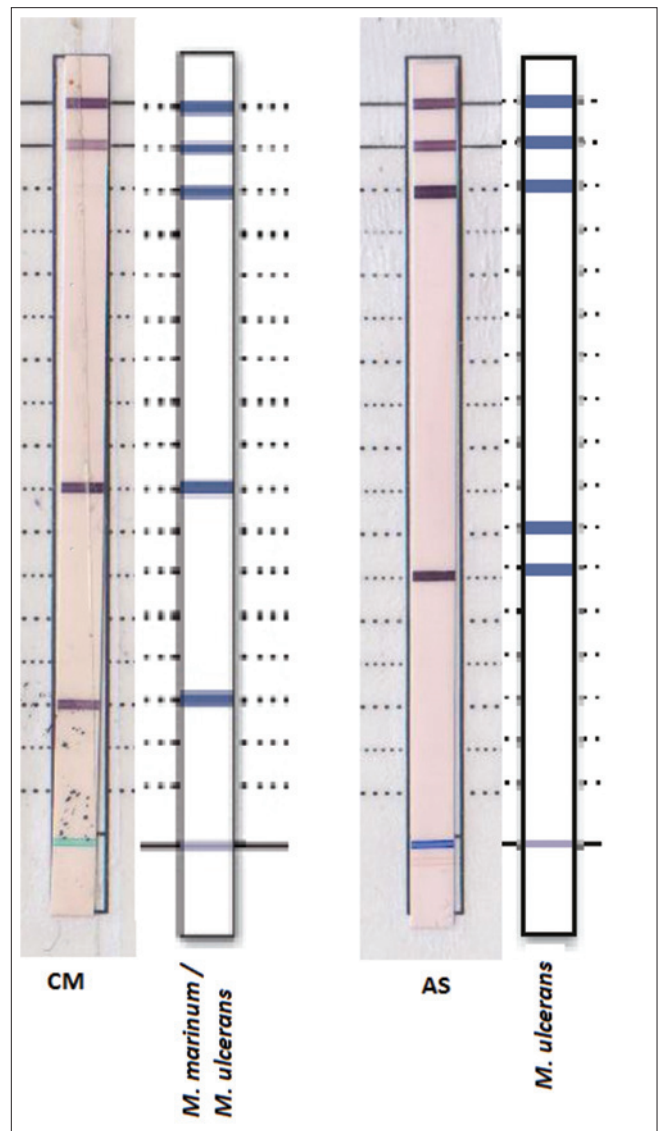
Further probing revealed that the patient had had contact with an aquarium 3 weeks before the development of lesions. We started treatment with oral doxycycline 100 mg/day since he was healthy, immunocompetent and had a well-localized lesion. After 2 months, his lesions had improved [Figure 5]. No recurrence was observed on follow up.

*M. marinum* is an environmental, non-tuberculous mycobacteria that causes disease in fresh and salt water fish and rarely, in humans. They are mainly aquarium-related or the result of fish or shellfish injuries in swimming pools and other freshwater sources. This has led to infection with *M. marinum* being named “fish tank granuloma”.<sup>[1]</sup> The disease begins as a violaceous papule or nodule and can also present as a psoriasiform or verrucous plaque, usually on the hands, feet, elbows or knees. Lesions develop at the site of trauma about 2 or 3 weeks after inoculation. These may be solitary but are often multiple and occasionally, sporotrichoid spread occurs. The lesions may ulcerate or frequently heal spontaneously within 1–2 years with residual scarring. Sometimes, penetration to underlying structures may occur.<sup>[2]</sup>

Diagnosis of *M. marinum* infection is often delayed because of the lack of clinical suspicion and the need for special diagnostic procedures. A rapid diagnosis by molecular diagnostic methods or mycobacterial

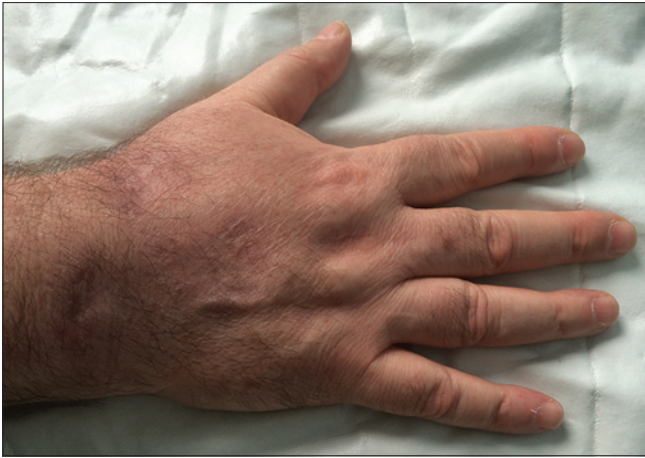

**Figure 3: Ziehl–Neelsen stain from liquid culture**



**Figure 4: Results of GenoType Mycobacterium CM and AS tests (Hain Lifescience, GmbH, Nehren, Germany)**

cultures usually leads to the correct diagnosis while histopathology seems to be supportive.<sup>[3]</sup> Since *M. marinum* is often resistant, both *in vitro* and *in*



**Figure 5: Significant improvement after doxycycline treatment for 2 months**

*vivo*, to several antibiotics, there is no established therapy of choice for these infections. Furthermore, no therapeutic studies based on large groups of patients have been published so far.<sup>[4]</sup> In superficial skin infections, clarithromycin, minocycline, doxycycline and trimethoprim-sulfamethoxazole are used as monotherapy. Combined therapy with two or more drugs might be required due to drug resistance. In severe infections, a combination of rifampicin and ethambutol has been recommended. Treatment should be given for at least 6 weeks and for up to 12 months, depending on the clinical evolution of the lesion. Debridement of the lesion is generally not recommended and is only indicated in cases that are refractory to antibiotic therapy. Cryotherapy, laser and photodynamic therapy have been reported as effective treatment choices but there are few studies evaluating the efficacy of these methods.<sup>[5]</sup>

Recently, opportunistic *M. marinum* skin infections have been reported in patients receiving anti-tumor necrosis factor agents.<sup>[6,7]</sup> As these agents become increasingly used for a variety of conditions, physicians should be alert about non-tuberculous mycobacterial infections in addition to tuberculosis.

In conclusion, clinicians evaluating patients with chronic subcutaneous nodules, plaques and ulcerations

of the hand refractory to antibiotics or antifungal agents should maintain a high index of suspicion for *M. marinum*. Clinical suspicion and a detailed history are important factors but the diagnosis needs to be confirmed by histopathological examination and mycobacteriological methods.

#### Financial support and sponsorship

Nil.

#### Conflicts of interest

There are no conflicts of interest.

**Aylin Türel Ermertcan, Nuri Özkütük<sup>1</sup>,  
Peyker Temiz<sup>2</sup>, Cengiz Çavuşoğlu<sup>3</sup>,  
Süheyla Sürücüoğlu<sup>1</sup>**

Departments of Dermatology, <sup>1</sup>Microbiology and <sup>2</sup>Pathology, Faculty of Medicine, Celal Bayar University, Manisa, <sup>3</sup>Department of Microbiology, Faculty of Medicine, Ege University, Izmir, Turkey

**Address for correspondence:** Prof. Aylin Türel Ermertcan, Department of Dermatology, Faculty of Medicine, Celal Bayar University, 45010 Manisa, Turkey.  
E-mail: drayliturel@hotmail.com

#### REFERENCES

1. Dolenc-Voljc M, Zolnir-Dovc M. Delayed diagnosis of *Mycobacterium marinum* infection: A case report and review of the literature. *Acta Dermatovenereol Alp Pannonica Adriat* 2010;19:35-9.
2. Lee WJ, Kang SM, Sung H, Won CH, Chang SE, Lee MW, et al. Non-tuberculous mycobacterial infections of the skin: A retrospective study of 29 cases. *J Dermatol* 2010;37:965-72.
3. Balagué N, Uçkay I, Vostrel P, Hinrikson H, Van Aaken I, Beaulieu JY. Non-tuberculous mycobacterial infections of the hand. *Chir Main* 2015;34:18-23.
4. Veraldi S, Cuka E, Nazzaro G. Treatment of sporotrichoid fish tank granuloma with pulsed clarithromycin. *Dermatology* 2014;229:83-7.
5. Sette CS, Wachholz PA, Masuda PY, da Costa Figueira RB, de Oliveira Mattar FR, Ura DG. *Mycobacterium marinum* infection: A case report. *J Venom Anim Toxins Incl Trop Dis* 2015;21:7.
6. Kump PK, Högenauer C, Wenzl HH, Petritsch W. A case of opportunistic skin infection with *Mycobacterium marinum* during adalimumab treatment in a patient with Crohn's disease. *J Crohns Colitis* 2013;7:e15-8.
7. Guyot A, Begon E, Abramowitz L, Landry J, Marinho E, Descamps V, et al. A case of acute and necrotizing cutaneous *Mycobacterium marinum* infection in a patient treated with infliximab for Crohn's disease. *Ann Dermatol Venereol* 2009;136:806-10.