

excluded, this is unlikely to happen in porokeratosis. This report highlights tacrolimus as an effective treatment option.

**Declaration of patient consent:** The authors certify that they have obtained all appropriate patient consent.

**Financial support and sponsorship:** Nil.

**Conflicts of interest:** There are no conflicts of interest.

**Use of artificial intelligence (AI)-assisted technology for manuscript preparation:** The authors confirm that there was no use of artificial intelligence (AI)-assisted technology for assisting in the writing or editing of the manuscript and no images were manipulated using AI.

**Shubham Kumar, Suman Patra, Aasma Nalwa**

Department of Dermatology, AIIMS, Jodhpur, Rajasthan, India.

**Corresponding author:**

Dr. Suman Patra,

Department of Dermatology, AIIMS, Jodhpur, Rajasthan, India.  
patrohere@gmail.com

## References

1. Weidner T, Illing T, Miguel D, Elsner P. Treatment of porokeratosis: A systematic review. *Am J Clin Dermatol* 2017;18:435–49.
2. Dedhia AR, Someshwar SJ, Jerajani HR. Facial solar porokeratosis. *Indian J Dermatol Venereol Leprol* 2016;82:337–9.
3. Parks AC, Conner KJ, Armstrong CA. Long-term clearance of linear porokeratosis with tacrolimus, 0.1%, ointment. *JAMA Dermatol* 2014; 150:194–6.
4. Lee Y, Choi EH. Exclusive facial porokeratosis: histopathologically showing follicular cornoi lamellae. *J Dermatol* 2011;38:1072–5.
5. Miranda SM, de Miranda JN, de Souza Filho JB. Facial porokeratosis characterized by destructive lesions. *Int J Dermatol* 2004;43:913–4.
6. Gutierrez EL, Galarza C, Ramos W, Tello M, De Paz PC, Bobbio L, et al. Facial porokeratosis: A series of six patients. *Aust J Dermatol* 2010;51:191–4.
7. Büchau AS, Schaubert J, Hultsch T, Stuetz A, Gallo RL. Pimecrolimus enhances TLR2/6-induced expression of antimicrobial peptides in keratinocytes. *J Invest Dermatol* 2008;128:2646–54.

# A case of palmoplantar pustulosis with atopic dermatitis: Baricitinib is a safe and effective treatment

Dear Editor,

A 20-year-old man presented with generalised erythema with pruritus for the last five years. He also had recurrent pustules and erythema on the soles for two years. Previous therapies with topical corticosteroids, antihistamines, and traditional Chinese medicine were ineffective. The patient had a history of allergic rhinitis. There was no family history of psoriasis, and systemic symptoms were unremarkable. Physical examination revealed scattered edematous erythematous papules on the face, dull erythematous patches containing clustered papules with localised lichenification on the trunk and limbs, and multiple pustules on large erythematous-squamous patches on the soles [Figures 1a, 1b]. He had no joint pain or fever. Laboratory tests showed an elevated eosinophil count ( $0.8 \times 10^9/L$ ) and IgE level (99 kU/L). Histology from the back showed hyperkeratosis, parakeratosis, focal mild interspinous oedema, few eosinophils and lymphocytes surrounding superficial dermal blood vessels and hair follicles, with infiltration of neutrophils and eosinophils in the infundibulum [Figure 1c]. Histology from the right foot showed hyperkeratosis, mild acanthosis, intraepidermal pustules with numerous neutrophils, perivascular eosinophils, and lymphocyte infiltration in the dermis below the pustules

[Figure 1d]. The patient was diagnosed with palmoplantar pustulosis (PPP) and atopic dermatitis (AD). He was treated with oral baricitinib 4 mg/d, and the lesions resolved four weeks later. After another three months, the dose was tapered to 2 mg/d. During the following two months, he discontinued baricitinib for one week and experienced a relapse. Then, the dose was increased back to 2 mg/d and continued for four weeks, but there was no improvement [Figure 2]. When it was further increased to 4 mg/d, the rash resolved within one week [Figures 3a, 3b]. The rash did not recur during the following two months. Then, baricitinib was tapered to 2 mg/d and 2 mg every other day for the next two months. No new skin lesions emerged, and all laboratory findings were within the normal limits.

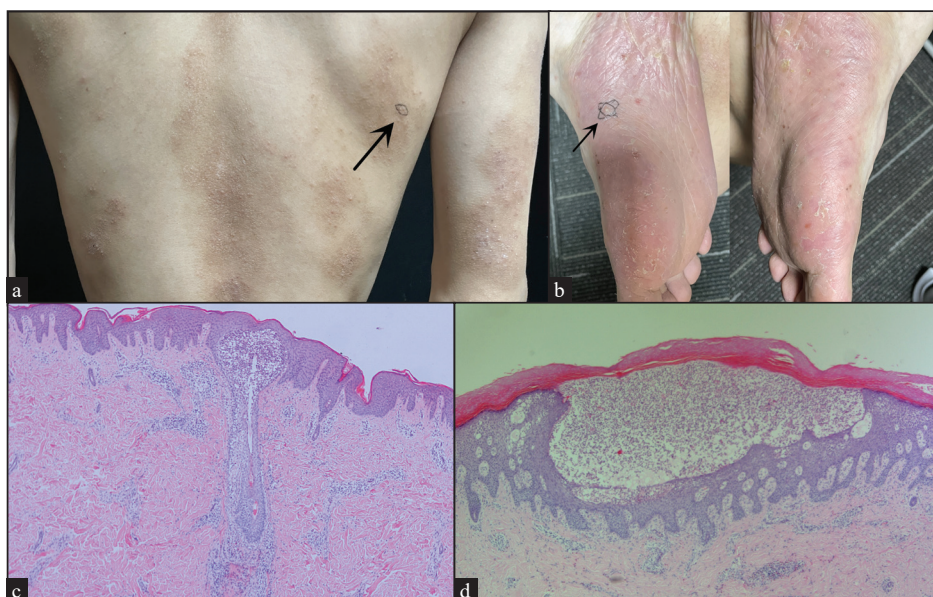
Palmoplantar pustulosis (PPP) is a chronic pustular dermatitis facilitated by T helper 1 (Th 1) cytokine production. AD is a persistent inflammatory skin disease; its acute phase is mainly mediated by Th2, and the Th2-Th1 switch promotes disease chronicity.<sup>1</sup> PPP and AD were once considered two opposite poles of the Th cell-mediated inflammation. The Th1/Th2 imbalance maybe the main immunological mechanism underlying PPP and AD.<sup>2</sup>

**How to cite this article:** Li X, Liu G, Chen S, Liu Y. A case of palmoplantar pustulosis with atopic dermatitis: Baricitinib is a safe and effective treatment. *Indian J Dermatol Venereol Leprol*. 2024;90:668-70. doi: 10.25259/IJDVL\_884\_2023

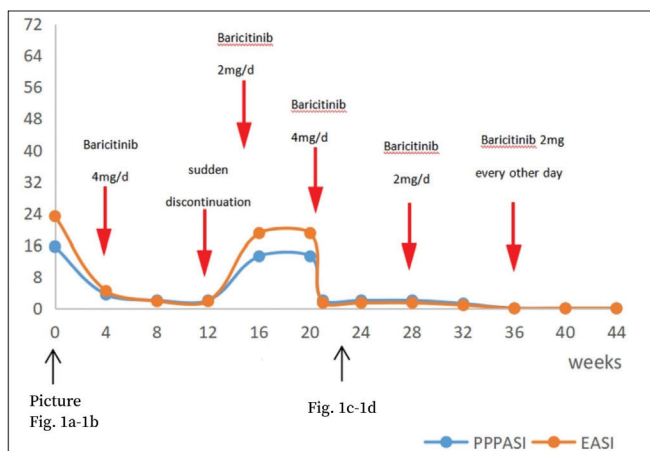
**Received:** August, 2023 **Accepted:** November, 2023 **Epub Ahead of Print:** April, 2024 **Published:** August, 2024

**DOI:** 10.25259/IJDVL\_884\_2023 **PMID:** 38841959

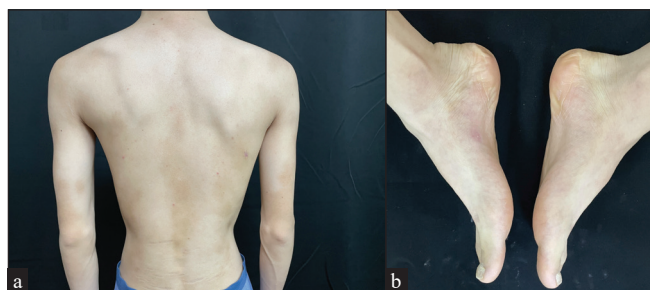
This is an open-access article distributed under the terms of the Creative Commons Attribution-Non Commercial-Share Alike 4.0 License, which allows others to remix, tweak, and build upon the work non-commercially, as long as the author is credited and the new creations are licensed under the identical terms.



**Figure 1:** (a) Dark-red patches containing clustered papules and localised lichenification on the back, marked as the site for biopsy (black arrow). (b) Multiple pustules on large erythematous-squamous patches on the soles, marked as the site for biopsy (black arrow). (c) Hyperkeratosis, parakeratosis, focal mild interspinous edema and inflammatory cells migration, few eosinophils and lymphocytes surrounding superficial dermal blood vessels and hair follicles, with infiltration of neutrophils and eosinophils in the infundibulum. (Haematoxylin & Eosin, 40x). (d) Hyperkeratosis, mild acanthosis, intraepidermal pustules with numerous neutrophils, perivascular eosinophils, and lymphocyte infiltration in the dermis below the pustules. (Haematoxylin & Eosin, 100x)



**Figure 2:** Eczema Area and Severity Index (EASI) for truncal rash, and Palmoplantar Pustulosis Area and Severity Index (PPPASI) for palmoplantar lesions decreased significantly post baricitinib and increased again after sudden discontinuation. EASI and PPPASI decreased when baricitinib was continued after relapse, and both remained unchanged when the dosage was gradually reduced after a marked improvement in skin lesions.



**Figure 3:** (a) Resolution of the truncal lesions. (b) Resolution of plantar lesions.

The patient’s diagnosis of AD was clear. However, plantar lesions must be distinguished from palmoplantar pustular psoriasis (PPPP). Yamamoto considered PPP to be a distinct entity from PPPP.<sup>3</sup> PPPP presents as well-circumscribed keratotic erythematous plaques with few pustules, not confined to the palms and soles. The dorsal surfaces of the hands and feet may also be involved, and patients usually develop plaque psoriasis elsewhere. Our patient was characterised by multiple sterile pustules over an erythematous and oedematous background on the soles, with no psoriasis-like lesions elsewhere on the body and no family history of psoriasis. Therefore, a diagnosis of PPP was made.

Traditional treatments have undesirable side effects, and biologics targeting specific cytokines are used to treat only one disease. Baricitinib, an oral Janus kinase (JAK) inhibitor, effectively targets JAK1 and JAK2, inhibiting downstream cytokine production and Th-cell differentiation by impeding the JAK-STAT signalling pathway. The course of our patient hints at a rapid response and long term efficacy of baricitinib in treating PPP and AD, but its dose must be reduced gradually. This is consistent with the findings from phase II<sup>4</sup>, phase III<sup>5</sup> trials and a long-term double-blind extension study<sup>6</sup> of baricitinib in the treatment of AD. Currently, there have been no reports of the use of baricitinib in the treatment of PPP. However, Koumaki *et al.*<sup>7</sup> have previously reported palmoplantar pustulosis eruption caused by baricitinib. Our study is distinct from the former and contributes to further exploration of the pathways involved in the effect of baricitinib on PPP. In conclusion, baricitinib could be a novel alternative for patients suffering from PPP with AD.

**Declaration of patient consent:** The authors certify that they have obtained all appropriate patient consent.

**Financial support and sponsorship:** Nil.

**Conflicts of interest:** There are no conflicts of interest.

**Use of artificial intelligence (AI)-assisted technology for manuscript preparation:** The authors confirm that there was no use of artificial intelligence (AI)-assisted technology for assisting in the writing or editing of the manuscript, and no images were manipulated using AI.

**Xiaoxian Li, Guoyan Liu, Shengli Chen, Yongxia Liu**

Department of Dermatology and Venereology, Shandong Provincial Hospital for Skin Diseases & Shandong Provincial Institute of Dermatology and Venereology, Shandong First Medical University & Shandong Academy of Medical Sciences. Huaiyin District, Jinan, Shandong, China.

**Corresponding author:**

Prof. Guoyan Liu,

Department of Dermatology and Venereology, Shandong Provincial Hospital for Skin Diseases & Shandong Provincial Institute of Dermatology and Venereology, Shandong First Medical University & Shandong Academy of Medical Sciences. Huaiyin District, Jinan, Shandong, China.  
wfliuguoyan@126.com

## References

1. Nutten S. Atopic dermatitis: Global epidemiology and risk factors. *Ann Nutr Metab* 2015;1:8–16.
2. Tsai YC, Tsai TF. Overlapping features of psoriasis and atopic dermatitis: From genetics to immunopathogenesis to phenotypes. *Int J Mol Sci* 2022;23:5518.
3. Yamamoto T. Similarity and difference between palmoplantar pustulosis and pustular psoriasis. *J Dermatol* 2021;48:750–60.
4. Guttman-Yassky E, Silverberg JI, Nemoto O, Forman SB, Wilke A, Prescilla R, *et al.* Baricitinib in adult patients with moderate-to-severe atopic dermatitis: A phase 2 parallel, double-blinded, randomized placebo-controlled multiple-dose study. *J Am Acad Dermatol* 2019;80:913–921.e9.
5. Simpson EL, Lacour JP, Spelman L, Galimberti R, Eichenfield LF, Bissonnette R, *et al.* Baricitinib in patients with moderate-to-severe atopic dermatitis and inadequate response to topical corticosteroids: Results from two randomized monotherapy phase III trials. *Br J Dermatol* 2020;183:242–55.
6. Silverberg JI, Simpson EL, Wollenberg A, Bissonnette R, Kabashima K, DeLozier AM, *et al.* Long-term efficacy of baricitinib in adults with moderate to severe atopic dermatitis who were treatment responders or partial responders: An extension study of 2 Randomized Clinical Trials. *JAMA Dermatol* 2021;157:691–9.
7. Koumaki D, Koumaki V, Lagoudaki E, Bertias G. Palmoplantar pustulosis-like eruption induced by baricitinib for treatment of rheumatoid arthritis. *Eur J Case Rep Intern Med* 2019;7:001383.