

Indian Journal of Dermatology, Venereology & Leprology

Journal indexed with SCI-E, PubMed, and EMBASE

Vol 74 | Issue 2 | Mar-Apr 2008

C O N T E N T S

EDITORIAL

Management of autoimmune urticaria

Arun C. Inamadar, Aparna Palit 89

VIEW POINT

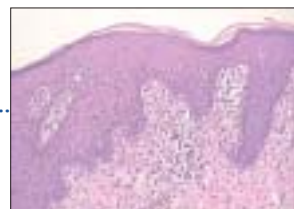Cosmetic dermatology versus cosmetology: A misnomer in need of urgent correction

Shyam B. Verma, Zoe D. Draelos 92

REVIEW ARTICLE

Psoriasiform dermatoses

Virendra N. Sehgal, Sunil Dogra, Govind Srivastava, Ashok K. Aggarwal 94



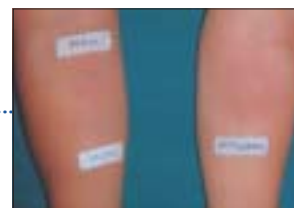ORIGINAL ARTICLES

A study of allergen-specific IgE antibodies in Indian patients of atopic dermatitis

V. K. Somani 100

Chronic idiopathic urticaria: Comparison of clinical features with positive autologous serum skin test

George Mamatha, C. Balachandran, Prabhu Smitha 105



Autologous serum therapy in chronic urticaria: Old wine in a new bottle

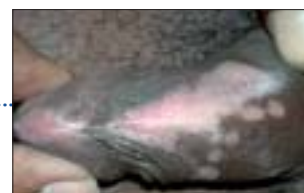A. K. Bajaj, Abir Saraswat, Amitabh Upadhyay, Rajetha Damisetty, Sandipan Dhar 109

Use of patch testing for identifying allergen causing chronic urticaria

Ashimav Deb Sharma 114

Vitiligoid lichen sclerosus: A reappraisal

Venkat Ratnam Attali, Sasi Kiran Attali 118



BRIEF REPORTS

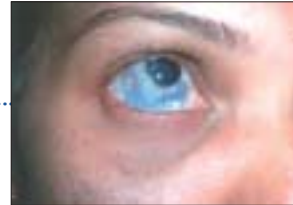Activated charcoal and baking soda to reduce odor associated with extensive blistering disorders

Arun Chakravarthi, C. R. Srinivas, Anil C. Mathew 122



Nevus of Ota: A series of 15 cases

Shanmuga Sekar, Maria Kuruvila, Harsha S. Pai 125



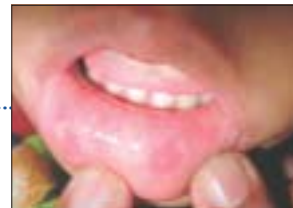Premature ovarian failure due to cyclophosphamide: A report of four cases in dermatology practice

Vikrant A. Saoji 128

CASE REPORTS

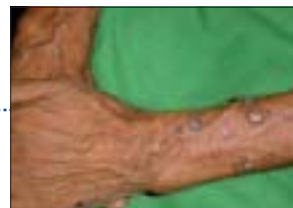Hand, foot and mouth disease in Nagpur

Vikrant A. Saoji 133



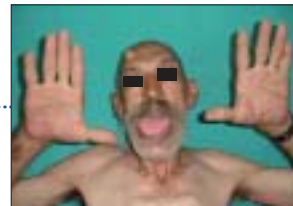Non-familial multiple keratoacanthomas in a 70 year-old long-term non-progressor HIV-seropositive man

Hemanta Kumar Kar, Sunil T. Sabhnani, R. K. Gautam, P. K. Sharma, Kalpana Solanki, Meenakshi Bhardwaj 136



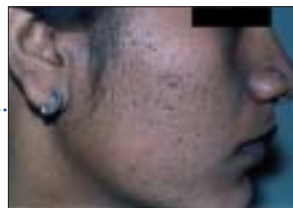Late onset isotretinoin resistant acne conglobata in a patient with acromegaly

Kapil Jain, V. K. Jain, Kamal Aggarwal, Anu Bansal 139



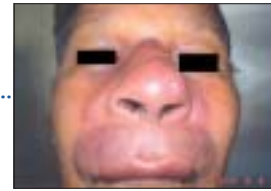Familial dyskeratotic comedones

M. Sendhil Kumaran, Divya Appachu, Elizabeth Jayaseelan 142



Nasal NK/T cell lymphoma presenting as a lethal midline granuloma

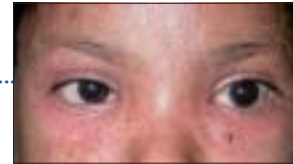Vandana Mehta, C. Balachandran, Sudha Bhat, V. Geetha, Donald Fernandes



145

Childhood sclerodermatomyositis with generalized morphea

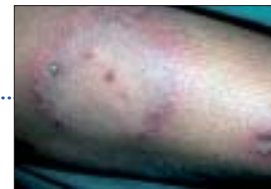Girishkumar R. Ambade, Rachita S. Dhurat, Nitin Lade, Hemangi R. Jerajani.....



148

Subcutaneous panniculitis-like T-cell cutaneous lymphoma

Avninder Singh, Joginder Kumar, Sujala Kapur, V. Ramesh.....



151

LETTERS TO EDITOR

Using a submersible pump to clean large areas of the body with antiseptics

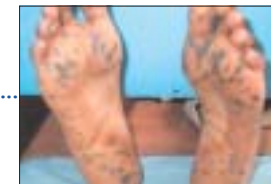C. R. Srinivas



154

Peutz-Jeghers syndrome with prominent palmoplantar pigmentation

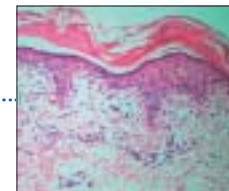
K. N. Shivaswamy, A. L. Shyamprasad, T. K. Sumathi, C. Ranganathan



154

Stratum corneum findings as clues to histological diagnosis of pityriasis lichenoides chronica

Rajiv Joshi



156

Author's reply

S. Pradeep Nair

157

Omalizumab in severe chronic urticaria

K. V. Godse.....

157

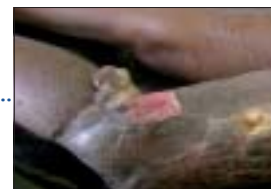Hypothesis: The potential utility of topical eflornithine against cutaneous leishmaniasis

M. R. Namazi

158

Nodular melanoma in a skin graft site scar

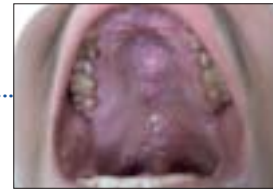A. Gnaneshwar Rao, Kamal K. Jhamnani, Chandana Konda



159

Palatal involvement in lepromatous leprosy

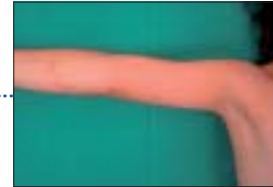A. Gnaneshwar Rao, Chandana Konda, Kamal Jhamnani.....



161

Unilateral nevoid telangiectasia with no estrogen and progesterone receptors in a pediatric patient

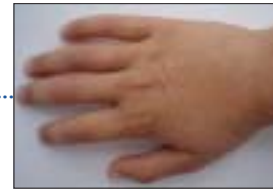F. Sule Afsar, Ragip Ortac, Gulden Diniz.....



163

Eruptive lichen planus in a child with celiac disease

Dipankar De, Amrinder J. Kanwar.....



164

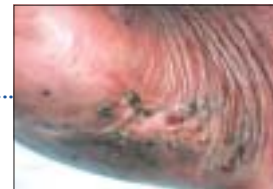Xerosis and pityriasis alba-like changes associated with zonisamide

Feroze Kaliyadan, Jayasree Manoj, S. Venkitakrishnan.....

165

Treatment of actinomycetoma with combination of rifampicin and co-trimoxazole

Rajiv Joshi.....



166

Author's reply

M. Ramam, Radhakrishna Bhat, Taru Garg, Vinod K. Sharma, R. Ray, M. K. Singh, U. Banerjee, C. Rajendran.....

168

Vitiligo, psoriasis and imiquimod: Fitting all into the same pathway

Bell Raj Eapen.....

169

Author's reply

Engin Şenel, Deniz Seçkin.....

169

Multiple dermatofibromas on face treated with carbon dioxide laser: The importance of laser parameters

Kabir Sardana, Vijay K. Garg.....

170

Author's reply

D. S. Krupa Shankar, A. Kushalappa, K. S. Uma, Anjay A. Pai.....

170

Alopecia areata progressing to totalis/universalis in non-insulin dependent diabetes mellitus (type II): Failure of dexamethasone-cyclophosphamide pulse therapy

Virendra N. Sehgal, Sambit N. Bhattacharya, Sonal Sharma, Govind Srivastava, Ashok K. Aggarwal.....



171

Subungual exostosis

Kamal Aggarwal, Sanjeev Gupta, Vijay Kumar Jain, Amit Mital, Sunita Gupta.....

173

Clinicohistopathological correlation of leprosy

Amrish N. Pandya, Hemali J. Tailor 174

RESIDENT'S PAGE

Dermatographism

Dipti Bhute, Bhavana Doshi, Sushil Pande, Sunanda Mahajan, Vidya Kharkar 177

FOCUS

Mycophenolate mofetil

Amar Surjushe, D. G. Saple 180

QUIZ

Multiple papules on the vulva

G. Raghu Rama Rao, R. Radha Rani, A. Amareswar, P. V. Krishnam
Raju, P. Raja Kumari, Y. Hari Kishan Kumar 185



E-IDVL

Net Study

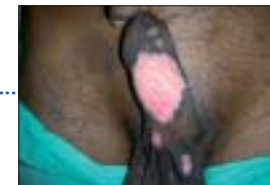Oral isotretinoin is as effective as a combination of oral isotretinoin and topical anti-acne agents in nodulocystic acne

Rajeev Dhir, Neetu P. Gehi, Reetu Agarwal, Yuvraj E. More 187

Net Case

Cutaneous diphtheria masquerading as a sexually transmitted disease

T. P. Vetrichevvel, Gajanan A. Pise, Kishan Kumar Agrawal,
Devinder Mohan Thappa 187



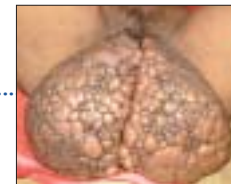Net Letters

Patch test in Behcet's disease

Ülker Gül, Müzeyyen Gönül, Seray Külcü Çakmak, Arzu Kılıç 187

Cerebriform elephantiasis of the vulva following tuberculous lymphadenitis

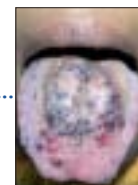Surajit Nayak, Basanti Acharjya, Basanti Devi, Satyadarshi Pattnaik,
Manoj Kumar Patra 188



Net Quiz

Vesicles on the tongue

Saurabh Agarwal, Krishna Gopal, Binay Kumar 188



Xerosis and pityriasis alba-like changes associated with zonisamide

Sir,

We would like to report a case of a 5-year-old child who developed extensive xerosis and pityriasis alba-like changes 2 months after she was started on zonisamide for West's syndrome. Zonisamide is known to induce hypohidrosis, which we assume to be the underlying reason for the sudden development of xerosis in this case.

The patient presented to us with a history of generalized dryness and asymptomatic hypopigmented lesions on her face and trunk, which had started developing over the previous one month. She was under treatment from a neurologist for West's syndrome for which she had been started on zonisamide 3 months previously. She was not on any other medication at the time of presentation. There was no history of any dry skin or any other significant skin disease in the past. Other than the seizure disorder, the patient was in good health. There was no personal or family history of atopy. On questioning, the mother mentioned an apparent decrease in sweating over the previous 1-2 months.

On examination, there was generalized dryness of the skin, which was more pronounced over the extremities. Hypopigmented macules of variable definition with minimal scaling were seen over the face [Figure 1] and trunk. Some lesions showed mild erythema. Nails and hair were normal. Potassium hydroxide smears from the hypopigmented lesions were negative, and Wood's lamp examination did not show any accentuation. A clinical diagnosis of xerosis and pityriasis alba-like changes was made. The patient was managed with emollients and vitamin supplements. Zonisamide was stopped and the patient was started on



Figure 1: Pityriasis alba like lesions on face

alternative anti-epileptic treatment, following which the dryness and the skin lesions improved.

Zonisamide is a relatively newer anti-epileptic drug that acts by the inhibition of carbonic anhydrase.^[1] Both zonisamide and topiramate (another anti-epileptic that is also a carbonic anhydrase inhibitor) have been documented to cause hypohidrosis.^[2-5] Zonisamide has also been implicated in the causation of heat stroke in children secondary to oligohidrosis.^[6] However, hypohidrosis is considered to be completely reversible after cessation of the drug.^[6,7] The exact mechanism of oligohidrosis due to these drugs remains conjectural, although it has been postulated that carbonic anhydrase blockage at the level of the sweat gland may be a major factor.^[7] In our case, we assume that hypohidrosis induced by zonisamide contributed to the sudden development of xerosis and pityriasis alba-like changes. Pityriasis alba itself is known to be precipitated by dryness of the skin.^[8] This report highlights the point that in patients on zonisamide or topiramate presenting with sudden onset of dryness of the skin, the possibility of drug-induced hypohidrosis should be considered.

**Feroze Kaliyadan, Jayasree Manoj,
S. Venkitakrishnan**

Department of Dermatology, Amrita Institute of Medical Sciences,
Kochi, India

Address for correspondence: Dr. Feroze Kaliyadan, Department of
Dermatology, Amrita Institute of Medical Sciences, Kochi - 682 026,
Kerala, India. E-mail: ferozkal@hotmail.com

REFERENCES

1. Leppik IE. Zonisamide: Chemistry, mechanism of action and pharmacokinetics. *Seizure* 2004;13:5-9.
2. Okumura A, Ishihara N, Kato T, Hayakawa F, Kuno K,

Watanabe K. Predictive value of acetylcholine stimulation testing for oligohidrosis caused by zonisamide. *Pediatr Neurol* 2000;23:59-61.

3. Knudsen JF, Thambi LR, Kapcala LP, Racoosin JA. Oligohidrosis and fever in pediatric patients treated with zonisamide. *Pediatr Neurol* 2003;28:184-9.
4. Low PA, James S, Peschel T, Leong R, Rothstein A. Zonisamide and associated oligohidrosis and hyperthermia. *Epilepsy Res* 2004;62:27-34.
5. de Carolis P, Magnifico F, Pierangeli G, Rinaldi R, Galeotti M, Cevoli S, *et al.* Transient hypohidrosis induced by topiramate. *Epilepsia* 2003;44:974-6.
6. Shimizu T, Yamashita Y, Sato M, Togo A, Wada N, Matsuishi T, *et al.* Heat stroke-like episode in a child caused by zonisamide. *Brain Dev* 1997;19:366-8.
7. Cerminara C, Seri S, Bombardieri R, Pinci M, Curatolo P. Hypohidrosis during topiramate treatment: A rare and reversible side effect. *Pediatr Neurol* 2006;34:392-4.
8. Vinod S, Singh G, Dash K, Grover S. Clinico epidemiological study of pityriasis alba. *Indian J Dermatol Venereol Leprol* 2002;68:338-40.