

Multiple glomeruloid hemangiomas without POEMS syndrome

Sir,

Glomeruloid hemangioma is considered to be a specific cutaneous marker of POEMS (polyneuropathy, organomegaly, endocrinopathy, M-band, skin changes) syndrome. We report a case of multiple glomeruloid hemangiomas in a young man who had no features of POEMS syndrome. A brief review of literature of similar cases is also presented.

A 24-year-old man presented to us with a 5-year history of multiple, asymptomatic, erythematous papules on his neck. The lesions began as a small number of papules on the left side of the neck, gradually increased in size and number and progressed to involve the other side as well. There was no history of any spontaneous resolution, fluctuation in size or bleeding from the lesions. He had no systemic complaints. On examination, there were multiple soft, non-tender, partially compressible, erythematous

papules ranging in size from 0.5 to 1.5 cm, clustered on the left side of the neck extending up to the submandibular region with fewer lesions on the right side. Two similar papules were also present on the right upper eyelid [Figure 1]. There was no loco-regional lymphadenopathy. Skin biopsy from a neck papule showed several closely aggregated capillaries lined by plump endothelial cells intertwined with each other in a plexiform architecture. Variable sized, homogenous periodic acid–Schiff (PAS)-positive, diastase-resistant globules were seen in the cytoplasm of endothelial cells. The endothelial cells stained positively for CD34. The histological features were diagnostic of glomeruloid hemangioma [Figure 2]. Results of complete blood count, serum biochemistry, fasting blood sugar and thyroid profile were within normal limits. There was no Bence-Jones proteinuria and the serum and protein electrophoresis did not show any M-band. No osteosclerotic lesions were noted on skeletal survey. A computerized tomography scan of chest and abdomen was normal. Nerve conduction studies were also normal.

Glomeruloid hemangioma is a rare benign cutaneous vascular neoplasm first described by Chan

et al.^[1] These may present as dermal erythematous to red-purple papules and nodules, subcutaneous bluish compressible nodules, wine-red sessile or pedunculated papules or lesions with cerebriform morphology.^[2] The pathogenesis of glomeruloid hemangiomas is still a matter of speculation. Theories include deposition of immunoglobulins within endothelial cells, raised estrogen levels, role of human herpesvirus-8 and increased release of cytokines with angiogenic action such as interleukin-6, interleukin-1 β , tumor necrosis factor- α and vascular endothelial growth factor.^[3] Unlike their clinical presentation that is varied and non-descript, the histopathological appearance that resembles renal glomeruli is quite characteristic. The periodic acid-Schiff-positive, diastase-resistant eosinophilic globules in the cytoplasm of endothelial cells were initially thought to represent circulating immunoglobulins.^[1] However, Lee *et al.* found that the interior of these eosinophilic globules did not

stain positive for either kappa or lambda chains and hemoglobin A.^[4] Electron microscopic examination suggested that these structures represent secondary lysosomes (thanatosomes) expanded by phagocytosed proteinaceous material.

A variety of cutaneous vascular tumors are described in the setting of POEMS syndrome: glomeruloid hemangiomas, microvenular hemangiomas, cherry angiomas and multinucleated cell angiohistiocytomas. However, only glomeruloid hemangiomas are considered specific, occurring in 26–44% cases.^[1] In 2005, Vélez *et al.* reported the first case of solitary glomeruloid hemangioma without POEMS syndrome on the chin of an 86-year-old man.^[5] Since then, only a handful of cases of glomeruloid hemangioma without this characteristic association have been described. On reviewing the literature, we could find only 11 other

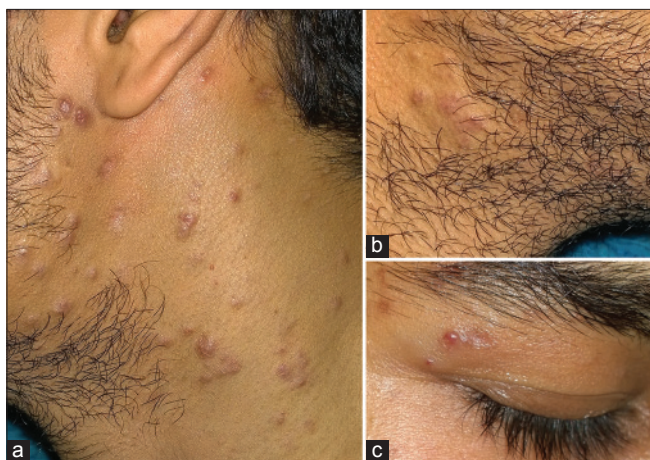

Figure 1: (a) Multiple erythematous papules on the left side of neck extending to the mandible (b) few similar papules grouped on the right submandibular region (c) two papules on the lateral aspect of right upper eyelid

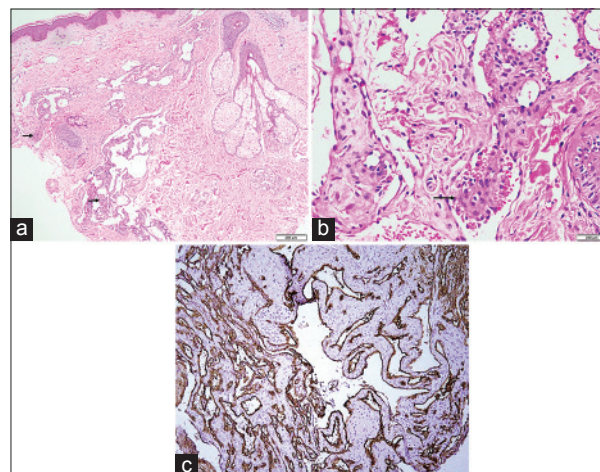


Figure 2: (a) Dilated capillaries in the dermis with aggregates of capillaries in ectatic vascular spaces (black arrow) (H and E, $\times 40$). (b) The capillary tufts resemble renal glomeruli (black arrow) (H and E, $\times 200$). (c) Immunohistochemistry with CD34 highlights the endothelial lining of capillaries (H and E, $\times 200$)

Table 1: Previously published cases of glomeruloid hemangiomas without POEMS syndrome

| Age/gender | Duration | Clinical manifestations | Follow-up | Reference |
|----------------|------------|---|-------------------|------------------------------------|
| 86 year/male | 4 year | Single red papule on chin | 4 years | Velez <i>et al.</i> 2005 |
| 46 year/female | 6 months | Multiple red-bluish papules on trunk | 6 months | Pina-Oviedo <i>et al.</i> 2006 |
| 29 year/male | N/A | N/A | N/A | Forman <i>et al.</i> 2007 |
| 53 year/female | N/A | N/A | N/A | Forman <i>et al.</i> 2007 |
| 33 year/female | N/A | N/A | N/A | Forman <i>et al.</i> 2007 |
| 50 year/male | N/A | Single red-tan cystic nodule on left cheek | 5 years | Lee <i>et al.</i> 2008 |
| 78 year/female | 20 years | Single violaceous cystic nodule on right cheek | 16 months | Lee <i>et al.</i> 2008 |
| 78 year/male | 2 years | Single red nodule on the scalp | 10 months | Gonzalez-Guerra <i>et al.</i> 2009 |
| 47 year/female | Many years | Multiple red papules on neck, chest and upper extremities | N/A | Jacobson-Dunlop <i>et al.</i> 2012 |
| 18 year/male | 6 months | Multiple skin colored papules on the chin | 1 year | Gupta <i>et al.</i> 2013 |
| 22 year/male | 10 years | Multiple skin colored papules and nodules on neck | Lost to follow-up | Gupta <i>et al.</i> 2013 |
| 24 year/male | 5 years | Multiple erythematous papules on neck | 2 years | Present case |

N/A: Not available

cases of cutaneous glomeruloid hemangiomas without an underlying POEMS syndrome.^[4-10] Six of the eight patients, whose clinical information is available, had single-multiple lesions confined to the head and neck area while only two cases had multiple papules on the trunk [Table 1]. Thus, it appears that the head and neck region, although considered an unusual site for glomeruloid hemangiomas, is more commonly affected in the absence of POEMS syndrome. This is in contrast to what is seen in POEMS syndrome where trunk and proximal extremities are predominantly affected.^[3]

Since glomeruloid hemangiomas have been present in our patient in the absence of any other feature for 7 years (5 years before presentation and a 2 year follow up period), he is probably unlikely to develop POEMS syndrome. However, glomeruloid hemangiomas may rarely precede other manifestations by a long period, so we plan to keep our patient under follow-up.^[1]

Financial support and sponsorship

Nil.

Conflicts of interest

There are no conflicts of interest.

Vishal Gupta, Ajay Rai, Asit Ranjan Mridha¹, Vinod Kumar Sharma

Departments of Dermatology and Venereology and ¹Pathology, All India Institute of Medical Sciences, New Delhi, India

Address for correspondence: Dr. Vinod Kumar Sharma, Department of Dermatology and Venereology, Teaching Block, All India Institute of Medical Sciences, Ansari Nagar, New Delhi - 110 029, India. E-mail: aiimsvks@yahoo.com

REFERENCES

1. Chan JK, Fletcher CD, Hicklin GA, Rosai J. Glomeruloid hemangioma. A distinctive cutaneous lesion of multicentric Castleman's disease associated with POEMS syndrome. *Am J Surg Pathol* 1990;14:1036-46.

2. Chan PT, Lee KC, Chong LY, Lo KK, Cheung YF. Glomeruloid haemangioma with cerebriform morphology in a patient with POEMS syndrome. *Clin Exp Dermatol* 2006;31:775-7.
3. Gherardi RK, Bélec L, Soubrier M, Malapert D, Zuber M, Viard JP, *et al.* Overproduction of proinflammatory cytokines imbalanced by their antagonists in POEMS syndrome. *Blood* 1996;87:1458-65.
4. Lee H, Meier FA, Ma CK, Ormsby AH, Lee MW. Eosinophilic globules in 3 cases of glomeruloid hemangioma of the head and neck: A characteristic offering more evidence for thanatosomes with or without POEMS. *Am J Dermatopathol* 2008;30:539-44.
5. Vélez D, Delgado-Jiménez Y, Fraga J. Solitary glomeruloid haemangioma without POEMS syndrome. *J Cutan Pathol* 2005;32:449-52.
6. Piña-Oviedo S, López-Patiño S, Ortiz-Hidalgo C. Glomeruloid hemangiomas localized to the skin of the trunk with no clinical features of POEMS syndrome. *Int J Dermatol* 2006;45:1449-50.
7. Forman SB, Tyler WB, Ferringer TC, Elston DM. Glomeruloid hemangiomas without POEMS syndrome: Series of three cases. *J Cutan Pathol* 2007;34:956-7.
8. González-Guerra E, Haro MR, Fariña MC, Martín L, Manzarbeitia L, Requena L. Glomeruloid haemangioma is not always associated with POEMS syndrome. *Clin Exp Dermatol* 2009;34:800-3.
9. Jacobson-Dunlop E, Liu H, Simpson EL, White CR Jr., White KP. Glomeruloid hemangiomas in the absence of POEMS syndrome. *J Cutan Pathol* 2012;39:402-3.
10. Gupta J, Kandhari R, Ramesh V, Singh A. Glomeruloid hemangioma in normal individuals. *Indian J Dermatol* 2013;58:160.

This is an open access article distributed under the terms of the Creative Commons Attribution-NonCommercial-ShareAlike 3.0 License, which allows others to remix, tweak, and build upon the work non-commercially, as long as the author is credited and the new creations are licensed under the identical terms.

| Access this article online | |
|--|---|
| Quick Response Code: | Website: www.ijdv.com |
|  | DOI: 10.4103/0378-6323.181461 |
| | |

How to cite this article: Gupta V, Rai A, Mridha AR, Sharma VK. Multiple glomeruloid hemangiomas without POEMS syndrome. *Indian J Dermatol Venereol Leprol* 2016;82:442-4.

Received: May, 2015. **Accepted:** December, 2015.