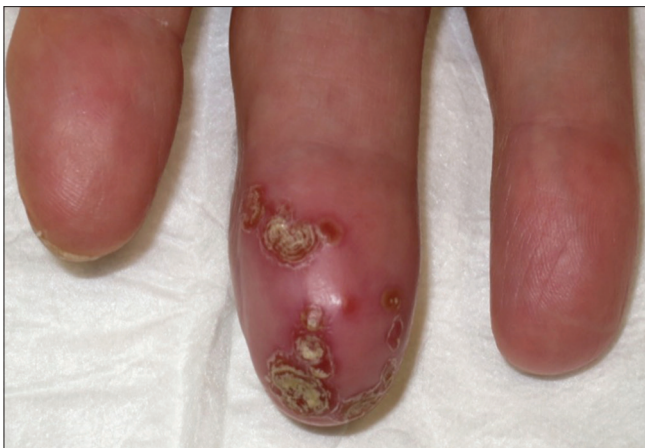

## Distal infection of the middle finger caused by *Mycobacterium abscessus*

Sir,

An otherwise healthy woman in her 60 s without any past medical history or previous trauma presented to our dermatology department with a painful swelling of her right middle finger since last 4 months. She had been previously treated with oral amoxicillin-clavulanic acid, levofloxacin, rifampin and fluconazole without any appreciable response. She had also undergone two surgical debridements, including a nail extraction at the traumatology unit, due to severe tumefaction of the finger, but lesions persisted.

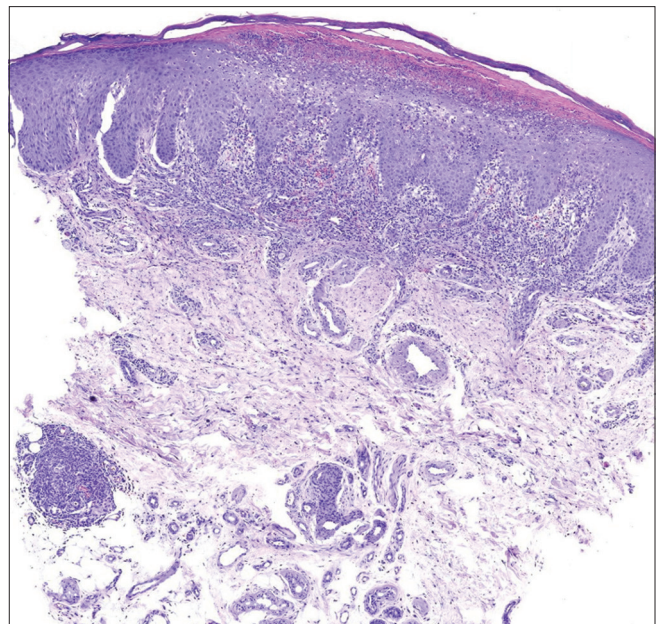
On physical examination, the distal part of her right middle finger was erythematous and swollen, with annular crusts in a confluent pattern [Figure 1]. Lesions were tender on palpation. Hair, nails and mucosae were spared. Rest of



**Figure 1:** Erythema and swelling of the right middle finger with annular crusts in a confluent pattern

her general and systemic examination was within normal limits.

Two punch biopsies were performed. Histological examination revealed mild epidermal hyperplasia with a subcorneal pustule and a non-necrotizing granuloma in the dermo-hypodermic junction. Rest of the dermis showed a mild lymphoid infiltrate [Figure 2a and b]. The cultures in Sabouraud agar, Löwenstein–Jensen and blood agar media were non-yielding. The Tzanck test and the



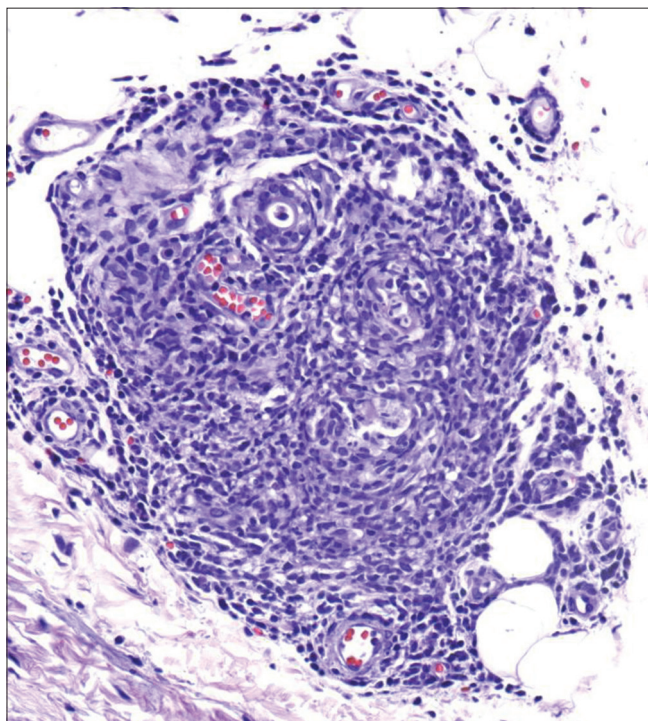
**Figure 2a:** Mild epidermal hyperplasia with a subcorneal pustule, mild lymphoid infiltrate in dermis and a granuloma in the dermo-hipodermic junction (H and E, ×40)

polymerase chain reaction for herpes simplex virus were also negative. In-house polymerase chain reaction amplification of mycobacterial 16S rRNA gene directly from solid tissue sample and subsequent gene sequencing using Sanger method in our Microbiology Unit confirmed the presence of *Mycobacterium abscessus* subsp. *abscessus*.

Due to the lack of an antibiogram, we administered empiric treatment with clarithromycin 500 mg b.i.d. and ciprofloxacin 500 mg b.i.d. Amikacin was not initiated as the patient was reluctant to receive intravenous therapy. The finger showed rapid clinical improvement in the following weeks. However, only partial clinical response was observed after 4 months which prompted the addition of minocycline 100 mg b.i.d. to the current drugs. The patient completed a 6-month course of these three antibiotics with complete resolution of the lesions [Figure 3].

*Mycobacterium abscessus* is an atypical fast-growing mycobacteria, capable of producing progressive pulmonary disease and soft tissue infections in humans. This organism is ubiquitous in the environment and has been found in municipal and well water, soil and dust. An increased incidence of cutaneous nontuberculous mycobacterial infections has been documented recently.<sup>1</sup> In addition, several outbreaks of *M.abscessus* skin and soft tissue infections have also been recently reported, associated with medical procedures, cosmetic surgery, acupuncture and tattoos.<sup>2,3</sup>

Cutaneous infection by *M. abscessus* is characterized by nodules, recurrent abscesses and nonhealing ulcers. Multiple



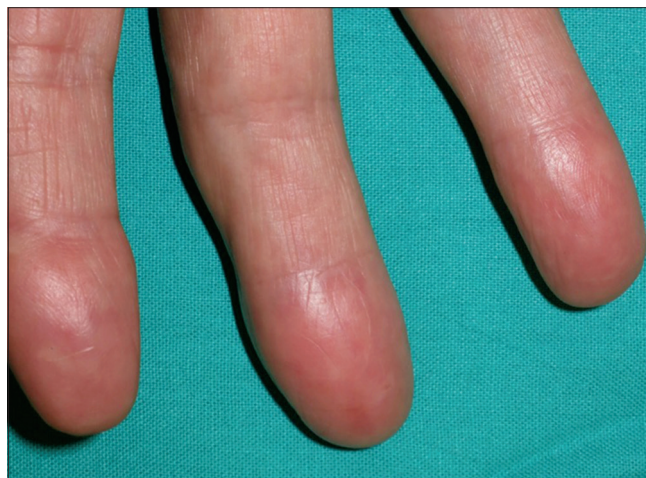**Figure 2b:** Nonnecrotizing granuloma in the dermo-hipodermic junction (H and E,  $\times 200$ )

lesions may be observed.<sup>4</sup> The common differentials include bacterial and fungal infections, granulomatous processes and tumoral diseases, thus a high index of suspicion is necessary for diagnosis. The diagnosis may be confirmed by a positive culture of *M.abscessus* from drainage material, surgical debridement or skin biopsy. However, the isolation of *M.abscessus* is notoriously difficult and slow, so more rapid diagnostic methods, such as polymerase chain reaction, are being used. Differences in gene-sequence coding for 16S ribosomal RNA help differentiate among the different atypical mycobacteria subspecies.<sup>4,5</sup>

In one of the largest series reported, histopathology revealed nodular, granulomatous or diffuse inflammation with mixed granulomas in 80% of the cases and abscesses with a mild granulomatous reaction in 15% of the biopsies. However, bacilli could be detected only in 27% of the specimens.<sup>2</sup>

*M.abscessus* is intrinsically resistant to several of the currently available antibiotics, including the classical antituberculous drugs,<sup>4,5</sup> thus this condition is extremely difficult to treat. Intrinsic resistance is attributed to multiple factors like low permeability of the cell envelope, drug efflux pumps (ABC-type multidrug transporters), genetic polymorphism of antibiotic target genes and enzymes in the cytoplasm that neutralize antibiotics, such as aminoglycosides.<sup>5</sup> Also, inducible resistance for macrolides encoded by the *erm* gene has been reported and may explain the lack of efficacy of clarithromycin-based therapy in certain patients.

Successful treatment involves debridement, curettage of all infected tissue, excision of foreign bodies, as well as antimicrobial therapy for several months.<sup>4</sup> No controlled clinical trials of treatment for *M. abscessus* have been performed. If susceptibility testing shows sensitivity after prolonged incubation (14 days), this may predict a favorable outcome with a combination therapy of clarithromycin and amikacin, possibly supplemented with cefoxitin or a fluorquinolone.<sup>5</sup>



**Figure 3:** Complete clinical resolution after 6 months with triple antibiotic therapy

In conclusion, increased incidence of cutaneous nontuberculous mycobacterial infections has been reported in the past years. The diagnosis and treatment of skin and soft tissue infections caused by *M. abscessus* is a challenge for clinicians. Molecular biology techniques such as polymerase chain reaction offer high sensitivity and rapid results and represent an interesting alternative to the microbiological culture. A high suspicion index and awareness is necessary for diagnosis, especially in atypical clinical presentation, such as our case.

#### Declaration of patient consent

The authors certify that they have obtained all appropriate patient consent forms. In the form, the patient has given her consent for her images and other clinical information to be reported in the journal. The patient understands that name and initial will not be published and due efforts will be made to conceal identity, but anonymity cannot be guaranteed.

#### Financial support and sponsorship

Nil.

#### Conflicts of interest

There are no conflicts of interest.

**Daniel Morgado-Carrasco,  
Constanza Riquelme-Mc Loughlin,  
Xavier Fustà-Novell, Adriana García<sup>1</sup>,  
Pilar Iranzo-Fernández**

Department of Dermatology, Dermatology Unit, Hospital Clínic de Barcelona, Universitat de Barcelona, <sup>1</sup>Department of Pathology, Hospital Clínic de Barcelona, Universitat de Barcelona, Barcelona, Spain

**Correspondence:** Dr. Pilar Iranzo-Fernández,  
Dermatology Unit, Hospital Clínic de Barcelona, C/Villarroel,  
170, Zip Code 08036, Barcelona, Spain.  
E-mail: piranzo@clinic.cat

#### References

1. Wentworth AB, Drage LA, Wengenack NL, Wilson JW, Lohse CM. Increased incidence of cutaneous nontuberculous mycobacterial infection, 1980 to 2009: A population-based study. *Mayo Clin Proc* 2013;88:38-45.
2. Rodríguez G, Ortegón M, Camargo D, Orozco LC. Iatrogenic *Mycobacterium abscessus* infection: Histopathology of 71 patients. *Br J Dermatol* 1997;137:214-8.
3. Newman MI, Camberos AE, Ascherman J. *Mycobacteria abscessus* outbreak in US patients linked to offshore surgicenter. *Ann Plast Surg* 2005;55:107-10.
4. Uslan DZ, Kowalski TJ, Wengenack NL, Virk A, Wilson JW. Skin and soft tissue infections due to rapidly growing mycobacteria: Comparison of clinical features, treatment, and susceptibility. *Arch Dermatol* 2006;142:1287-92.
5. Nessar R, Cambau E, Reytrat JM, Murray A, Gicquel B. *Mycobacterium abscessus*: A new antibiotic nightmare. *J Antimicrob Chemother* 2012;67:810-8.

This is an open access journal, and articles are distributed under the terms of the Creative Commons Attribution-NonCommercial-ShareAlike 4.0 License, which allows others to remix, tweak, and build upon the work non-commercially, as long as appropriate credit is given and the new creations are licensed under the identical terms.

Access this article online	
<b>Quick Response Code:</b>	<b>Website:</b> www.ijdvl.com
	<b>DOI:</b> 10.4103/ijdvl.IJDVL_929_17

**How to cite this article:** Morgado-Carrasco D, Loughlin CR, Fustà-Novell X, García A, Iranzo-Fernández P. Distal infection of the middle finger caused by *Mycobacterium abscessus*. *Indian J Dermatol Venereol Leprol* 2018;84:626-8.

**Received:** February, 2018. **Accepted:** May, 2018.

© 2018 Indian Journal of Dermatology, Venereology and Leprology | Published by Wolters Kluwer - Medknow