

Successful treatment of xanthelasma palpebrarum grade III with copper vapour laser radiation (578 nm)

Dear Editor,

Xanthelasma palpebrarum appears as yellowish plaques on eyelids. The prevalence of xanthelasma palpebrarum varies from 0.3% in men to 1.1% in women.¹ Xanthelasma is reported to have a tendency to enlarge and may cause aesthetic problems, eyelid dysfunction and evident cosmetic problems. Xanthelasma palpebrarum never resolves spontaneously. The severity of xanthelasma palpebrarum corresponds to grade I if the lesions are present only on the upper eyelids, grade II if the lesions extend to the medial canthal area, grade III if the lesions are present on medial side of both upper and lower eyelids and grade IV if there is diffuse involvement on medial and lateral aspects of upper and lower eyelids.² Surgical management for xanthelasma palpebrarum when required, besides excision and blepharoplasty, has to include additional skin or the orbicularis muscle flap. In a diffusely involved area, more intensive chemical, cryothermal, ablative lasers (CO₂, Er:YAG) or cautery interventions are needed to eliminate xanthelasma completely, but they were recommended only for the early stages of xanthelasma palpebrarum. Because of the small thickness of the eyelid dermis, it is very important to select an appropriate method of treatment for xanthelasma, as cautery or excision of xanthelasma palpebrarum can cause recurrence and scar formation.³

Laser radiation at 578 nm proves to be the most appropriate for the treatment of xanthelasma palpebrarum.⁴ Pathogenetic

treatment of the xanthelasma palpebrarum must prevent the transfer of low-density lipoproteins (LDL) via the permeable vascular wall and blocking the blood flow in microvessels, phagocytosis of LDL-overloaded foam cells and remodelling the vascular bed in the recovered upper dermis.⁴

The copper vapour laser radiation at a wavelength of 578 nm implements photothermal blockage of the blood flow in highly permeable microvessels inside the involved upper dermis around xanthelasma palpebrarum.⁵ The effective laser radiation penetration depth does not exceed the thickness of the eyelid dermis due to the high absorption of radiation by oxyhaemoglobin and haemoglobin.

A 72-year-old lady presented with yellowish plaques on the medial aspects of both upper and lower eyelids of more than 12 years duration [Figure 1a]. A clinical diagnosis of xanthelasma palpebrarum grade III was made.

The lesions were successfully treated with a copper vapour laser (Yakhroma-Med, P.N. Lebedev Physical Institute of RAS) at a 578 nm wavelength, an average power of 0.8 W, an exposure time of 0.2 s and a 1 mm light spot diameter.

The laser management of xanthelasma palpebrarum was performed with stainless steel corneal eye shield after a topical ophthalmic local anaesthetic application for 20 minutes.

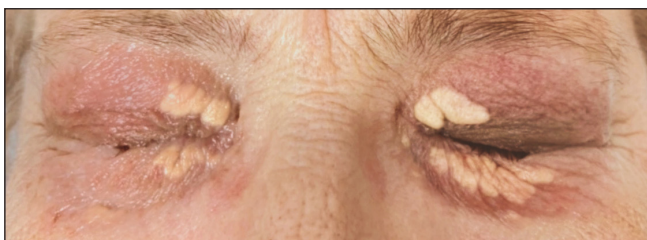


Figure 1a: A 72-year-old lady with bilateral grade III xanthelasma palpebrarum

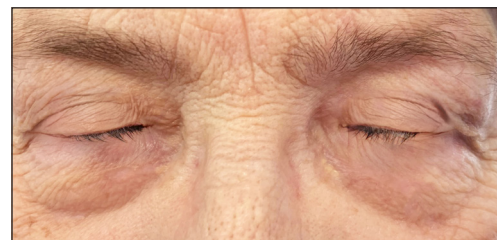

Figure 1b: Clearance of bilateral grade III xanthelasma palpebrarum, two months after the copper vapour laser treatment

How to cite this article: Ponomarev IV, Topchiy SB, Shakina LD. Successful treatment of xanthelasma palpebrarum grade III with copper vapour laser radiation (578 nm). *Indian J Dermatol Venereol Leprol* doi: 10.25259/IJDVL_339_2023

Received: March, 2023 **Accepted:** June, 2023 **Epub Ahead of Print:** July, 2023

DOI: 10.25259/IJDVL_339_2023

This is an open-access article distributed under the terms of the Creative Commons Attribution-Non Commercial-Share Alike 4.0 License, which allows others to remix, tweak, and build upon the work non-commercially, as long as the author is credited and the new creations are licensed under the identical terms.

The lesion was treated with laser pulses using a multiple stacking pass technique until the entire treated area acquired a greyish tint. The removal of xanthelasma palpebrarum was carried out during a single session.

After the procedure, the irradiated skin was treated with a 0.05% chlorhexidine gluconate solution, followed by the application of an epithelizing cream with bepanthene twice a day. The patient was advised to avoid sun exposure and use topical sun protection cream with a sun protection factor of at least 30.

The irradiated skin healed with crusting and exfoliation over two weeks. During a 24-month follow-up period, no side effects or recurrence occurred.

The copper vapour laser is minimally invasive, safe and effective treatment of xanthelasma palpebrarum with a good cosmetic outcome [Figure 1b]. It can be a good alternative approach to the surgical excision or the ablative laser mode. More studies are required to determine the optimal settings for the copper vapour laser treatment of eyelid lesions in patients with different skin phototypes.

Acknowledgement

Authors are grateful to Dr Marina Solovieva, Medical Center MisMed, Nizhny Novgorod, Russian Federation for clinical supporting this study.

Declaration of patient consent

The authors certify that they have obtained all appropriate patient consent.

Financial support and sponsorship

Nil.

Conflicts of interest

There are no conflicts of interest.

**Igor V. Ponomarev, Sergey B. Topchiy,
Lyudmila D. Shakina¹**

LPI Troitsk science park, P.N. Lebedev Physical Institute,
¹Department of Social Paediatrics, National Medical Research Centre of
Children's Health, Moscow, Russian Federation.

Corresponding author:

Dr. Igor V. Ponomarev,
LPI Troitsk science park,
P.N. Lebedev Physical Institute, Moscow, Russian Federation.
luklalukla@ya.ru

References

1. Jonsson A, Sigfiisson N. Significance of xanthelasma palpebrarum in the normal population. *Lancet* 1976;76:372.
2. Lee HY, Jin US, Minn KW, Park YO. Outcomes of surgical management of xanthelasma palpebrarum. *Arch Plast Surg* 2013;40:380–6.
3. Chopra K, Calva D, Sosin M, Tadisina KK, Banda A, De La Cruz C, *et al.* A comprehensive examination of topographic thickness of skin in the human face. *Aesthet Surg J* 2015;35:1007–13.
4. Laftah Z, Al-Niaimi F. Xanthelasma: An update on treatment modalities. *J Cutan Aesthet Surg* 2018;11:1–6.
5. Ivanov IT, Chakaarov I, Chakaarova P. Thermal sensitivity and haemolysis of erythrocytes with membranopathy. *J Therm Biol* 2019;81:98–102.