

Verrucous lesion on dorsum of the foot

A 55 year-old man presented in our clinic with a warty mass on the dorsum of his foot, which had been growing for the past 5-6 years. It was treated as a wart with many household remedies without any success. The patient had a discolored spot in that area since childhood and the present lesion started there until it grew to the present size. He complained of bleeding from the lesion off and on.

On examination there was a 3 x 2 cm dark verrucous lesion on the dorsum of the left foot [Figure 1]. Upon palpation, the lesion was hard to feel, but was freely movable in all directions. There was a slight swelling in the perilesional

area, which was soft to palpation.

The patient had no history of trauma, fever or weight loss. He had no systemic signs or symptoms. There were no palpable lymph nodes in the affected area or in the inguinal region. His hemogram, liver and kidney functions, blood sugar, chest X-ray and ultrasonography of the abdomen were normal. An excisional biopsy was done with a 4 mm free margin. The findings are shown in Figure 2.

WHAT IS THE DIAGNOSIS?

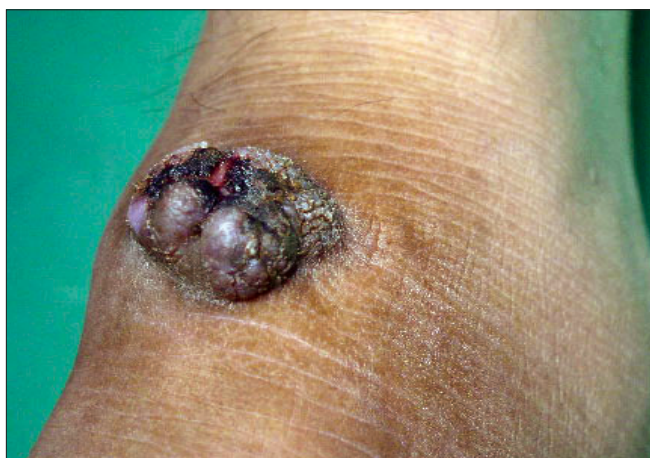

Figure 1: Verrucous nodule over ankle joint

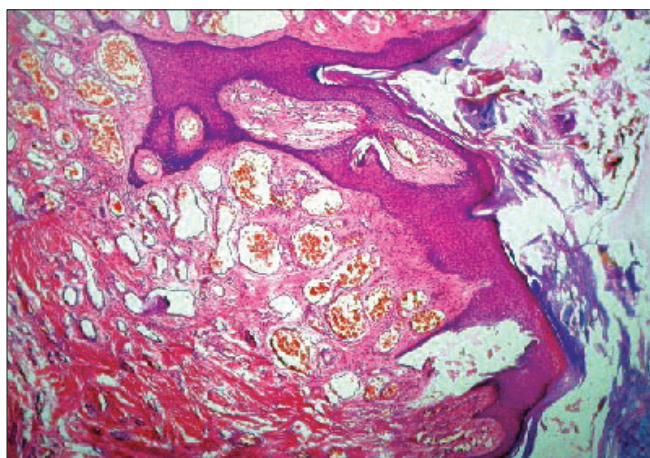


Figure 2: Skin biopsy (H and E, x200)

Diagnosis: Verrucous hemangioma

DISCUSSION

There was marked verrucous hyperplasia of the epidermis. A vascular tumor involving the papillary and reticular dermis and subcutaneous tissue was seen. The overall size of the dilated papillary dermal capillaries beneath an acanthotic epidermis and their distribution were characteristic of a hemangioma [Figure 2]. Diagnosis of a verrucous hemangioma was made.

Verrucous hemangioma is a rare but a well-documented entity. It is a variety of angiomatous nevus with secondary hyperkeratosis.^[1] The leg is the usual site of predilection^[1-3] where single or multiple lesions are found. In some cases, satellite lesions are also seen around the primary lesion. It is first seen at birth but can also start in adulthood. It can start as lesions resembling port wine stains which may later become soft bluish-red vascular swellings that tend to grow in size and become verrucous.^[2] They are known to bleed repeatedly and get infected.^[1-3]

Unlike other angiomatous nevi, they do not involute spontaneously. Clinically they may resemble angiokeratoma, lymphangioma circumscriptum, verrucous epidermal nevus, verrucous cancer or even malignant melanoma.^[1-3] It may not be easy to diagnose verrucous hemangioma purely on clinical grounds.^[2,3] Histopathology of verrucous hemangioma shows a verrucous hyperplasia of epidermis. The underlying dermis and subcutaneous tissue has foci of capillary and cavernous hemangiomas. The term "cavernous hemangiomas" is no longer used. They can be differentiated from angiokeratomas, which are ectasias of superficial vessels. Verrucous hemangiomas contain true areas of hemangioma and involve deeper structures.^[4]

Superficial ablative procedures like electrocautery, cryosurgery and laser application almost invariably lead to recurrence of the lesion.^[5-7] Adequate excision in terms of area and depth is desirable to ensure no recurrence. A combined approach using surgery and laser have been reported with good results.^[5] Verrucous hemangioma should be considered in the differential diagnosis of verrucous lesions on the lower extremities.

Shyam B. Verma

Consultant Dermatologist, Baroda, India

Address for correspondence: Dr. Shyam B. Verma, Nirvana Skin Clinic, Makarpura Main Road, Baroda - 390 002, India.
E-mail: vermaderma@rediffmail.com

REFERENCES

1. Odom RB, James WD, Berger TG. Dermal and subcutaneous tumors. *In:* Odom RB, James WD, Berger TG, editors. *Andrew's Diseases of the skin: Clinical Dermatology*. 9th ed. WB Saunders Company: Philadelphia; 2000. p. 733-99.
2. Atherton DJ, Moss C. Naevi and other Developmental Defects. *In:* Burns T, Breathnach S, Cox N, Griffiths C, editors. *Rook/Wilkinson/ Ebling Textbook of dermatology*. 7th ed. Blackwell Science: Oxford; 2004. p. 15-60
3. Rupani AB, Madiwale CV, Vaideeswar P. Images in pathology: Verrucous haemangioma. *J Postgrad Med* 2000;46:132-3.
4. Strutton G. Vascular tumors. *In:* Weedon D, editor. *Skin Pathology*. 2nd ed. Churchill Livingstone: Edinburgh; 1997. p. 829.
5. Yang CH, Ohara K. Successful surgical treatment of verrucous hemangioma: A combined approach. *Dermatol Surg* 2002;28:913-9.
6. Wang G, Li C, Gao T. Verrucous hemangioma. *Int J Dermatol* 2004;43:745-6.
7. Caldach L, Ortega C, Navarro V, Martinez E, Molina I, Jorda E. Verrucous hemangioma: Report of two cases and review of the literature. *Pediatr Dermatol* 2000;17:213-7.