

# Localized unilateral basaloid follicular hamartoma along Blaschko's lines on face

Sarina Jain, Uday Khopkar, Jagdish Sakhiya<sup>1</sup>

Department of Dermatology, Seth GS Medical College and KEM Hospital, Mumbai, Maharashtra,  
<sup>1</sup>Consultant Dermatologist, Sakhiya Skin Clinic, Surat, Gujarat, India

## Abstract

Basaloid follicular hamartoma (BFH) is a rare hamartoma of hair follicle. Clinical presentations may vary but are united by the same histopathological features in the form of folliculocentric basaloid or squamoid cell proliferation in the superficial dermis, which represents malformed and distorted hair follicles. It is important to recognize this entity as its simulant is basal cell carcinoma, a low-grade malignancy. Here, we report a case of localized unilateral BFH in a Blaschkoid distribution on the face of a 14-year-old female.

**Key words:** Basal cell carcinoma, basaloid follicular hamartoma, Blaschko's lines

## Correspondence:

Dr. Sarina Jain,  
 Department of Dermatology,  
 Main Hospital Building,  
 Ward 17-18, Ground  
 Floor, KEM Hospital,  
 Parel, Mumbai - 400 012,  
 Maharashtra, India.  
 E-mail: sarinajaingoyal@  
 gmail.com

## Introduction

Basaloid follicular hamartoma (BFH) is a rare hamartoma with hair follicle elements and characteristic histopathological features that may simulate basal cell carcinoma (BCC). It may present as solitary or multiple papules or plaques in a generalized or localized distribution. Here, we report a case of localized unilateral BFH along the lines of Blaschko on the face of a 14-year-old female.

## Case Report

A 14-year-old female presented with an asymptomatic lesion on the left side of her face since early childhood. The lesion began as two small papules on the left cheek at the age of 2 years spontaneously without any prior trauma and gradually progressed over 12 years to reach the present size. There was no history of similar lesions in the family. The patient was otherwise healthy, with no relevant medical history.

On examination, multiple skin-colored, flat-topped papules, coalescing to form an oval plaque of size 6 cm × 4 cm, along with few milia were seen on the left side of the cheek. The lesion extended from the mid of left cheek to the medial aspect

of the left upper eyelid following the lines of Blaschko. The right side of her face was completely spared [Figure 1a and b]. No other body parts were involved. Our clinical differential diagnoses were nevus sebaceous, collagen nevus, multiple trichoepitheliomas along Blaschko's lines, and unilateral nevoid BCC syndrome. Skin biopsy showed a well-demarcated epithelial proliferation in the upper dermis composed of squamoid and basaloid cells that formed branching cords and strands, most of which were seen connected with the overlying epithelium. Each tumor island was associated with a malformed vellus follicle located beneath it. A few dilated cystic infundibula and foci of sebaceous differentiation were seen inside these proliferations [Figure 2a and b]. Majority cells were squamoid cells along with a few scattered basaloid cells at the periphery of proliferations. Peripheral palisading, mitotic figures, necrotic tumor cells, and cytological atypia were absent [Figure 2c]. Surrounding stroma was scant, mildly fibrocellular, and contained scant mucin. There was virtually no inflammatory cell infiltrate. Clefts were seen to be present mainly within the stroma, with minimal clefting at the borders between the tumor islands and the surrounding

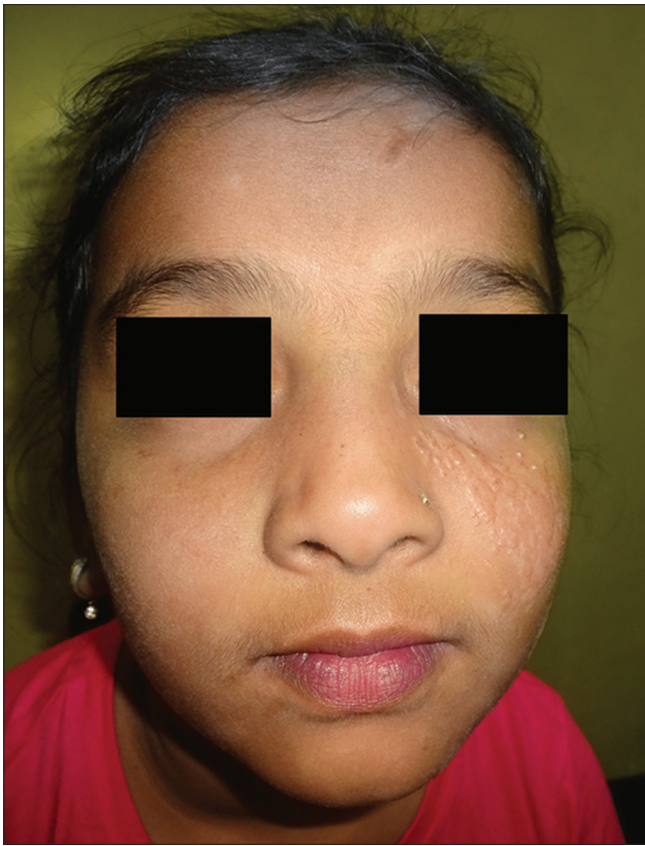This is an open access journal, and articles are distributed under the terms of the Creative Commons Attribution-NonCommercial-ShareAlike 4.0 License, which allows others to remix, tweak, and build upon the work non-commercially, as long as appropriate credit is given and the new creations are licensed under the identical terms.

**For reprints contact:** reprints@medknow.com

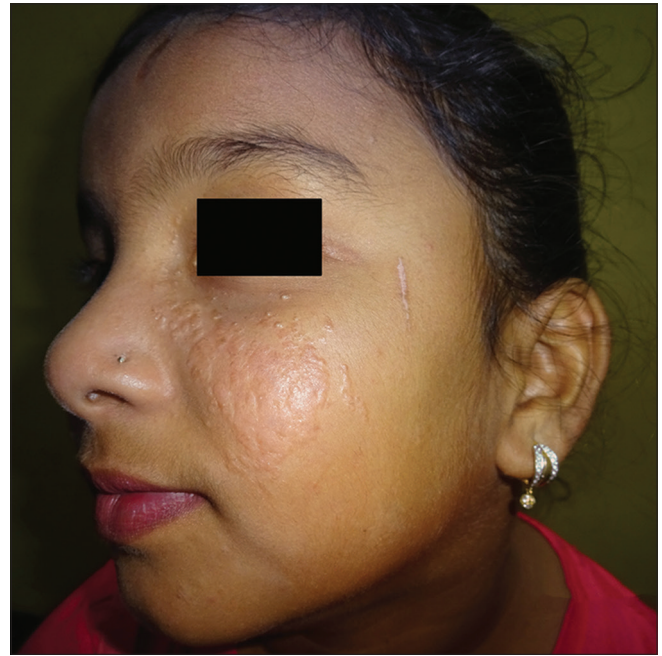**How to cite this article:** Jain S, Khopkar U, Sakhiya J. Localized unilateral basaloid follicular hamartoma along Blaschko's lines on face. Indian J Dermatol Venereol Leprol 2019;85:60-4.

**Received:** July, 2017. **Accepted:** September, 2017.

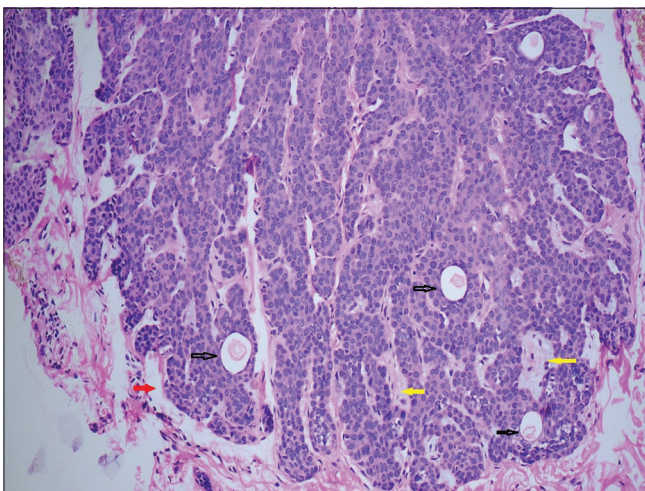
Access this article online	
Quick Response Code:	Website: www.ijdv1.com
	DOI: 10.4103/ijdv1.IJDVL_466_17



**Figure 1a:** Skin-colored plaque and papules on the left side of the face along the Blaschko's lines



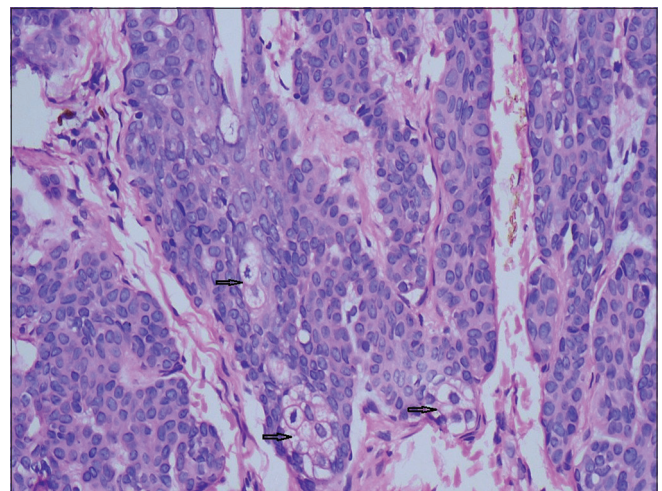
**Figure 1b:** Unilateral flat-topped papules and plaque (6 cm x 4 cm) along the lines of Blaschko, with a few milia



**Figure 2a:** A few dilated cystic infundibula (black arrows) stoma containing scant mucin (yellow arrows) and clefts, mainly within the stroma (red arrow) (H and E, x100)

stroma [Figure 2a]. The overlying epidermis was atrophic but intact.

Upon immunohistochemical staining, tumor cells expressed AE1/AE3 (keratin). Ki-67 index was only 10% [Figure 3a]. A few peripheral tumor cells bordering the stroma stained weakly for Bcl-2 [Figure 3b]. The



**Figure 2b:** Foci of sebaceous differentiation (black arrows) (H and E, x200)

stroma showed strong CD34 positivity and weak CD10 positivity [Figure 3c and d].

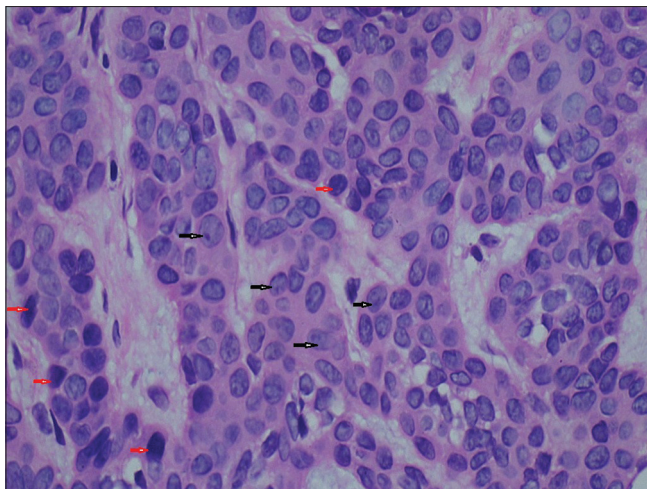
Based on the clinical, histopathological, and immunohistochemical findings, we diagnosed our patient as a case of localized unilateral BFH present along the Blaschko's lines on the face. We counseled her regarding the benign nature of the disease and advised her for periodic follow-up.



**Table 1: Comparison of histopathological and immunohistochemical characteristics of basaloid follicular hamartoma and basal cell carcinoma**

Particulars	BFH	BCC
<b>Histopathology</b>		
Extent	Superficial dermis	May involve deeper tissues
Symmetry	Usually symmetrical	Asymmetrical
Overlying epidermis	May be atrophic, but intact	Frequently ulcerated
Margin	Well circumscribed with a rounded outline	Poorly circumscribed with irregular margin
Pattern	Anastomosing and radial pattern of neoplastic cells (strands and cords)	Variable, depending upon the subtype
Tumor cells	Well differentiated basaloid and squamoid cells	Basaloid cells with hyperchromatic nucleus
Palisading	A variable feature (uncommon)	A constant feature
Pyknotic tumor cells	Minimal/absent	Numerous, often necrosis en masse
Mitotic figures	Rare/absent	Frequent
Cellular atypia	Absent	Present, of variable degree
Clefts	Mainly within the stroma, minimal at stromal-tumor interface	Common, at stromal-tumor interface only
Infundibular cyst	A constant feature	Absent, except in infundibulocystic BCC
Inflammatory infiltrate	Minimal	Usually present, composed of lymphocytes with or without plasma cells
Interfollicular dermis	Spared	Involved
Stroma	Scant, can be fibrillar, fibrocytic or mucinous	Considerable, mucinous with abundant fibroblasts
<b>Immunohistochemistry</b>		
Tumor cells		
Ki-67 index	Low	High
Bcl-2	Restricted to a few cells at periphery of tumor islands	Diffusely positive
PCNA	Less prominent	More prominent
PTCH mRNA	Overexpressed only in cells having direct contact with the dermis	Overexpressed diffusely
CD10	Negative	Positive
Stroma		
CD34	Positive	Negative
CD10	Stains stroma and matrical cells	Stains stroma and tumor cells

BCC: Basal cell carcinoma, BFH: Basaloid follicular hamartoma



**Figure 2c:** Majority of squamoid cells (black arrows) with a few basaloid cells (red arrows), without any evidence of cellular atypia, mitosis, necrosis, and palisading (H and E, ×400)

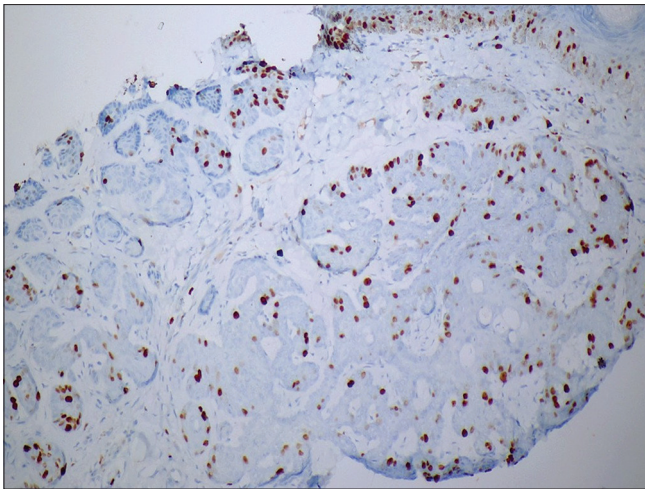
## Discussion

BFH is a rare cutaneous hamartoma showing follicular elements first described by Brown *et al.* in 1969. The term “basaloid follicular hamartoma” was coined by

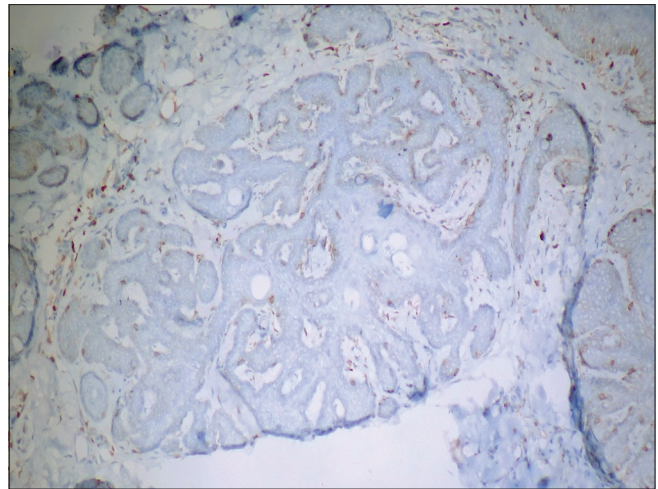
Mehregan and Baker in 1985 who described localized and solitary types of lesions without associated systemic involvement.<sup>1</sup>

Five clinical variants of BFH include solitary or multiple papules; a localized plaque with alopecia; a localized linear or unilateral papule or plaque; a generalized variant dominantly inherited familial type without associated disorders; and generalized papules associated with alopecia and myasthenia gravis.<sup>2</sup> Individual lesions are small, skin-colored to brown papules, nodules or plaques, with or without associated milia and/or comedones, commonly present over the face, scalp, and occasionally, the trunk.<sup>1</sup>

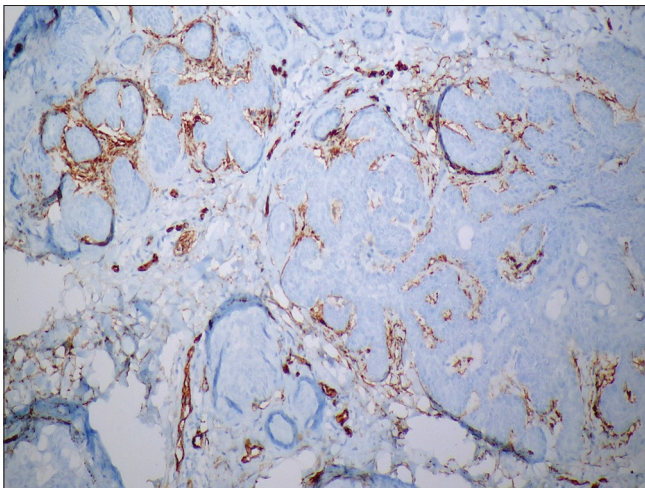
The localized linear or unilateral type may present at birth or may appear later in childhood or second decade of life. It commonly follows lines of Blaschko. Early lesions may show hypopigmented, smooth or striae-like areas, with or without comedones. Later, small skin-colored, pale or brown-colored papules and plaques may develop.<sup>3</sup> This type has been described with different names such as “linear unilateral basal cell nevus with comedones,” “linear unilateral basal cell nevus,” “linear unilateral basaloid



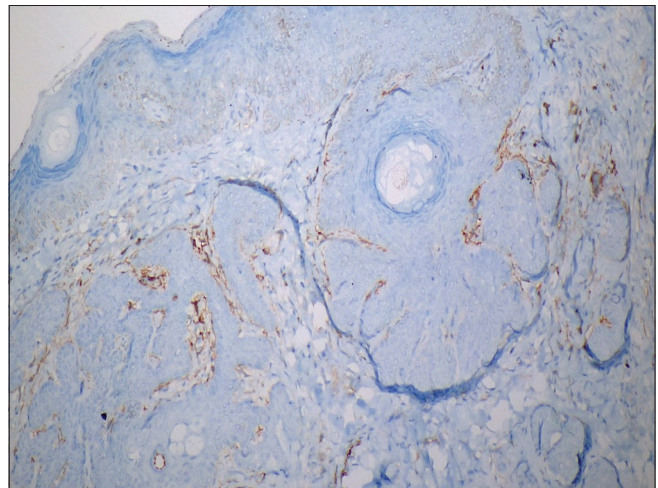
**Figure 3a:** Very few tumor cells showed nuclear positivity for Ki-67 ( $\times 100$ )



**Figure 3b:** A few peripheral tumor cells stained weakly for Bcl-2 ( $\times 100$ )



**Figure 3c:** CD34 stained peritumoral stroma and blood vessels ( $\times 100$ )



**Figure 3d:** Peritumoral stroma weakly positive for CD10 ( $\times 100$ )

follicular hamartoma,” and “basal-cell and linear unilateral adnexal hamartoma.”<sup>24</sup>

Histopathological differential diagnosis of BFH includes BCC and trichoepithelioma. The key histopathological and immunohistochemical differences between BFH and BCC are summarized in Table 1.<sup>1,2</sup> Trichoepithelioma is a benign neoplasm of germinative follicular cells. It is differentiated from BFH by the presence of follicular differentiation in the form of germs and papillae; abundant and highly fibrocytic stroma; palisading; and predominance of basaloid cells.<sup>2</sup>

Infundibulocystic BCC (ICBCC) is a rare variant of BCC that was described by Walsch and Ackerman in 1990 that is histopathologically similar to BFH.<sup>2</sup> In contrast to the BFH, ICBCC is a low-grade malignancy composed of neoplastic cell proliferation that involve and destroy pre-existing follicles as well as the interfollicular dermis.<sup>1</sup> Though it is usually confined to the upper dermis, it may sometimes

involve deeper tissues. It can also be differentiated from BFH by the presence of palisading, mitotic figures, necrotic neoplastic cells arranged as solitary units or in clusters and possible continuity with the nodular BCC.

The premalignant potential of BFH is currently uncertain, although BCC arising within BFH has been documented. Out of the 100 cases of BFH reported till date, 10 cases showing transition to BCC have been documented.<sup>1-10</sup> Out of these 10 cases, 8 cases were of localized linear or unilateral variant of BFH.<sup>3-10</sup> Rapid change in size or appearance of lesions of BFH may indicate development of BCC.

BFH *per se* is a benign condition which needs to be distinguished from BCC to avoid any aggressive surgical treatment. It remains stable for years and thus immediate surgical treatment is not required, and it can be periodically monitored to detect any malignant transformation. Treatment of BFH is opted by patients for cosmetic reasons. Treatment options include surgical excision, cryosurgery,

laser surgery, and photodynamic therapy for diffuse or extensive lesions.<sup>1</sup>

Here, we report a case of localized unilateral BFH along the Blaschko's lines on the face of a young female child. Though BFH is a benign condition in itself, since instances of development of BCC in BFH are known, our patient requires long-term follow-up.

#### **Declaration of patient consent**

The authors certify that they have obtained all appropriate patient consent forms. In the form, the patient has given her consent for her images and other clinical information to be reported in the journal. The patient understand that name and initials will not be published and due efforts will be made to conceal identity, but anonymity cannot be guaranteed.

#### **Financial support and sponsorship**

Nil.

#### **Conflicts of interest**

There are no conflicts of interest.

#### **References**

1. Gumaste P, Ortiz AE, Patel A, Baron J, Harris R, Barr R, *et al.* Generalized basaloid follicular hamartoma syndrome: A case report and review of the literature. *Am J Dermatopathol* 2015;37:e37-40.
2. Saxena A, Shapiro M, Kasper DA, Fitzpatrick JE, Mellette JR Jr. Basaloid follicular hamartoma: A cautionary tale and review of the literature. *Dermatol Surg* 2007;33:1130-5.
3. Jiménez-Acosta FJ, Redondo E, Baez O, Hernandez B. Linear unilateral basaloid follicular hamartoma. *J Am Acad Dermatol* 1992;27:316-9.
4. Yébenes M, Toll A, Vélez M, Barranco C, Alonso-López NA, Gonzalez-Sarmiento R, *et al.* Linear unilateral hamartomatous basal cell naevus with glandular and follicular differentiation. *Clin Exp Dermatol* 2008;33:429-32.
5. Yoshida Y, Urabe K, Mashino T, Duan H, Kiryu H, Masuda T, *et al.* Basal cell carcinomas in association with basaloid follicular hamartoma. *Dermatology* 2003;207:57-60.
6. Nelson BR, Johnson TM, Waldinger T, Gillard M, Lowe L. Basaloid follicular hamartoma: A histologic diagnosis with diverse clinical presentations. *Arch Dermatol* 1993;129:915-7.
7. Carney RG. Linear unilateral basal-cell nevus with comedones; report of a case. *AMA Arch Derm Syphilol* 1952;65:471-6.
8. Bleiberg J, Brodtkin RH. Linear unilateral basal cell nevus with comedones. *Arch Dermatol* 1969;100:187-90.
9. Anderson TE, Best PV. Linear basal-cell naevus. *Br J Dermatol* 1962;74:20-3.
10. Choi SW, Ryu YS, Kim HO, Kim CW. A case of basaloid follicular hamartoma combined with basal cell epithelioma. *Korean J Dermatol* 1998;36:148-51.