

Alexandrite (755 nm) laser hair removal therapy reduces recurrence rate of pilonidal sinus after surgery

Sir,

Pilonidal sinus is characterized by chronic abscess and sinus formation in the natal cleft region. Excessive hair growth has a pivotal pathogenetic role due to the penetration of broken terminal hairs into the subcutaneous tissue with subsequent inflammatory granuloma development and potential secondary infection. Primary treatment of pilonidal sinus is generally a surgical procedure which is often followed by a recurrence with relapse rates as high as up to 30%.¹ Hence, patients may benefit from permanent laser hair removal. The 755nm Alexandrite laser is one of the most effective hair removal lasers available.² We performed a retrospective study to determine the recurrence rate of pilonidal sinus, safety issues and patient satisfaction of Alexandrite laser hair removal therapy post-surgery.

Questionnaires were sent by postal mail to 153 consecutive patients treated between 2007 and 2016 with Alexandrite laser. The questionnaire contained queries on four domains: patient characteristics/demographic data, pilonidal sinus recurrences, safety issues and patient satisfaction. Patients reported on 5 or 10-point Likert scales; efficacy scale for hair removal: 1 = not effective to 10 = extremely effective; pain scale: 1–10; 0 = no pain, 10 = unbearable pain; hair extent scale: 0 = no hair, 1 = mild, 2 = moderate, 3 = severe, 4 = excessive. All patients had surgical pilonidal sinus treatment and were referred for laser hair removal after the surgical wound had completely healed. Treatments were standardized (same laser therapists, same laser, standard settings) with a 755nm wavelength Alexandrite laser (GentleMax, Candela); spot-size 15–18mm, pulse

duration 3–10ms, energy 18–26 J/cm², dynamic cooling device settings 30/20. The treatment interval was 6–8 weeks. Safety and recurrences were assessed by reviewing patients' medical records. All patient characteristics are included in Table 1.

Table 1: Patient characteristics, number of treatments and outcomes

Number of patients (<i>n</i>)	42
Gender, <i>n</i> (%)	
Men	35 (83.3)
Women	7 (16.7)
Age, mean±SD	31.9±14.8
Family history of pilonidal cysts, <i>n</i> (%)	9 (21.4)
BMI <25, <i>n</i> (%)	10 (23.8)
Smoking, <i>n</i> (%)	10 (23.8)
Number of patients with 1 surgical procedure, <i>n</i> (%)	21 (50)
Type of surgery, <i>n</i> (%)	
Primary closure	5 (11.9)
Open wound healing	37 (88.1)
Number of laser treatments, mean ± SD	4.8 (1.2)
Follow-up period (months), mean ± SD	20.4 (10.4)
Pilosity in the gluteal area*, mean (range)	0–4
Before laser treatment	2.66
After laser treatment	0.87
Number of recurrences after laser treatment, <i>n</i> (%)	3 (7.1)
Number of recurrences who require additional surgery, <i>n</i> (%)	1 (2.4)
Pain scale [#] , mean (range)	5.3 (1–10)

*0=no hair, 1=mild, 2=moderate, 3=severe, 4=excessive; [#]Scale 1–10; 0=no pain, 10=unbearable pain. SD: standard deviation, BMI: body mass index

Table 2: Results of previously described laser hair removal treatments for post-surgery pilonidal sinus

Study	Number of patients	Laser	No treatments	Recurrence, n (%)	Follow-up
Lindholt-Jensen <i>et al.</i>	37	Nd: YAG 1064 nm laser	4.7	9 (24.3)	15.2 months
Oram <i>et al.</i>	60	Alexandrite 755 nm laser	2.7±0.1	8 (13.3)	4.8±0.3 years
Khan <i>et al.</i>	19	Alexandrite 755 nm laser	7.7±2.8	3 (15.8)	Not reported
Kelati <i>et al.</i>	41	Laser group: 8 Alexandrite 755 nm 4 Nd:YAG 1064 nm	4.2	Laser group: 1 (8.3)	Laser group: 18 (1-30) months
		Control group: 29 surgery alone			Control group: 15 (51.7)
Conroy <i>et al.</i>	14	Alexandrite 755 nm laser	3.9	0 (0)	12 months

Forty two questionnaires (27.5%) were eligible for analyses. All patients were Caucasian with Fitzpatrick skin type I–III. Half of the patients (50%) were treated only once for pilonidal sinus in the past, whereas the other 21 (50%) patients had a history of recurrent pilonidal sinus. In 37 (88%) patients, the surgical wound healed with secondary granulation. The mean number of necessary laser treatments to achieve full hair removal was 4.8 ± 1.2 (mean \pm SD)[Table 2]. Alexandrite laser treatment was highly effective in reducing hair growth in all patients[Figure 1a].The extent of hair growth reported on a 5-point Likert scale (mean \pm SD) was 2.7 ± 0.9 before Alexandrite laser treatment and 0.9 ± 0.8 after Alexandrite laser treatment. Recurrence of the pilonidal sinus was reported by three (7.1%) patients but only one (2.4%) patient required additional surgery. Mean pain score during treatment (\pm SD) was 5.3 ± 2.0 . Only two (4.8%) patients reported residual hyperpigmentation. No other side effects or complications were reported [Figure 1b]. All patients would recommend Alexandrite laser hair removal post-surgery [Figure 1c].

In literature, several laser hair removal studies have previously been conducted with variable results. Oram *et al.* reported a 13.3% recurrence rate of pilonidal sinus after a mean number of 2.7 Alexandrite laser treatments.³ Recurrence rate after excision and primary closure was high (38%) and excision and flap reconstruction provided the best results with a relapse rate of only 7.3%. Therefore, it is attractive to speculate that the choice of surgical technique influences pilonidal sinus recurrence rate. In another study, three pilonidal sinus recurrences were observed out of 19 patients (15.8%) treated with Alexandrite laser.² In a retrospective case-control study, comparing Alexandrite laser and Nd: YAG laser hair removal after pilonidal sinus surgery versus surgery alone, the recurrence rate was 8.3% for the “laser after surgery” group and 51.7% in the “surgery alone”group.⁴ further Mutus *et al.* showed zero recurrences in 32 patients treated with laser versus 21/268 (7.8%) relapses without laser hair removal.⁵ The results of our present study show relatively high efficacy in preventing pilonidal sinus relapse after surgery and the beneficial effects of laser therapy are in concordance with previous studies. A literature overview is presented in Table 1.

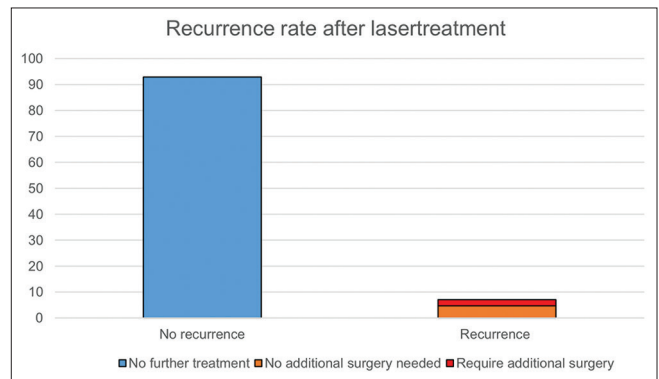


Figure 1a: Treatment efficacy

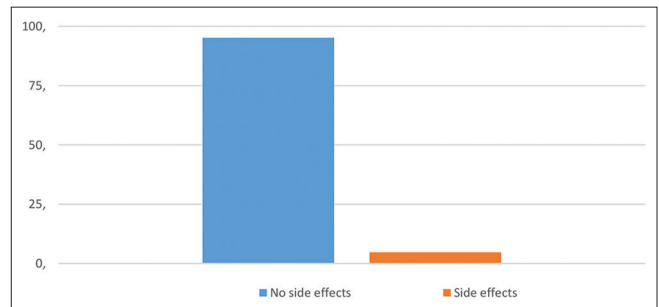


Figure 1b: Treatment safety

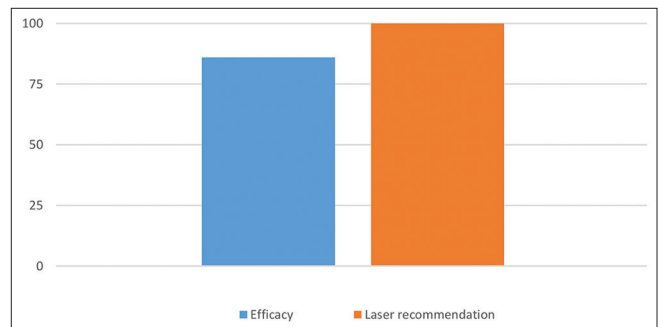


Figure 1c: Patient satisfaction

In general, Alexandrite lasers are not usually used in darker skin as they are shorter wavelengths and prone to adverse effects. In the present study, we only treated patients with Fitzpatrick’s skin type I–III. However, in our center, we

use the same laser for people with skin types IV and V with the following settings without any complications and with similar success rates: IV: spot-size 15, pulse duration 3ms, energy 20–24 J/cm², dynamic cooling device settings 40/20; V: spot-size 15, pulse duration 10ms, energy 12–18 J/cm², dynamic cooling device settings 40/20. We are not familiar with treating patients with Fitzpatrick skin type VI.

The strength of the present study includes a large number of patients who were consecutively referred by surgeons post-pilonidal sinus surgery, as well as standardization of the Alexandrite laser treatment procedure. Limitations of our study are the retrospective study design with its potential biases, for example, recall bias is possible as patients may not recall the pain scores after a longer period. Furthermore, the low number of respondents to the questionnaire (27.5%) and the variable follow-up period are issues to consider.

Notably, we observed a 100% score with respect to patient satisfaction: all patients would recommend Alexandrite laser hair removal to others. The excellent treatment tolerance/safety profile and limited pain/side effects make Alexandrite laser hair removal therapy ultimately suited as a secondary prevention measure after surgery for pilonidal sinus.

In conclusion, post-surgery 755 nm Alexandrite laser hair removal therapy is effective and highly satisfactory for pilonidal sinus patients in reducing recurrence rates, although prospective analysis is needed to confirm our results.

Declaration of patient consent

The authors certify that they have obtained all appropriate patient consent forms. In the form, the patients have given their consent for their images and other clinical information to be reported in the journal. The patients understand that their names and initials will not be published and due efforts will be made to conceal their identity, but anonymity cannot be guaranteed.

Financial support and sponsorship

Nil.

Conflicts of interest

There are no conflicts of interest.

**Harriet G. Luijks, Hedwig A. L.
Luiting-Welkenhuyzen, Ellen G. E. Greijmans,
H. Jorn Bovenschen**

Department of Dermatology, Máxima Medical Center Eindhoven,
Eindhoven, The Netherlands

Correspondence: Dr. H. Jorn Bovenschen,
Department of Dermatology, Máxima Medical Center Eindhoven,
De Run 4600, P. O. Box 7777, 5500 MB, Veldhoven,
Eindhoven, The Netherlands.
E-mail: j.bovenschen@mmc.nl

References

- Doll D, Krueger CM, Schrank S, Dettmann H, Petersen S, Duesel W. Timeline of recurrence after primary and secondary pilonidal sinus surgery. *Dis Colon Rectum* 2007;50:1928-34.
- Khan MA, Javed AA, Govindan KS, Rafiq S, Thomas K, Baker L, *et al.* Control of hair growth using long-pulsed alexandrite laser is an efficient and cost effective therapy for patients suffering from recurrent pilonidal disease. *Lasers Med Sci* 2016;31:857-62.
- Oram Y, Kahraman F, Karıncaoğlu Y, Koyuncu E. Evaluation of 60 patients with pilonidal sinus treated with laser epilation after surgery. *Dermatol Surg* 2010;36:88-91.
- Kelati A, Lagrange S, Le Duff F, Lacour JP, Benasaid R, Breaud J, *et al.* Laser hair removal after surgery vs. surgery alone for the treatment of pilonidal cysts: A retrospective case-control study. *J Eur Acad Dermatol Venereol* 2018;32:2031-3.
- Mutus HM, Aksu B, Uzun E, Gulcin N, Gercel G, Ozatman E, *et al.* Long-term analysis of surgical treatment outcomes in chronic pilonidal sinus disease. *J Pediatr Surg* 2018;53:293-4.

This is an open access journal, and articles are distributed under the terms of the Creative Commons Attribution-NonCommercial-ShareAlike 4.0 License, which allows others to remix, tweak, and build upon the work non-commercially, as long as appropriate credit is given and the new creations are licensed under the identical terms.

Access this article online	
Quick Response Code:	Website: www.ijdv.com
	DOI: 10.4103/ijdv.IJDVL_97_19

How to cite this article: Luijks HG, Luiting-Welkenhuyzen HA, Greijmans EG, Bovenschen HJ. Alexandrite (755 nm) laser hair removal therapy reduces recurrence rate of pilonidal sinus after surgery. *Indian J Dermatol Venereol Leprol* 2020;86:451-3.

Received: March, 2019. **Accepted:** January, 2020.

© 2020 Indian Journal of Dermatology, Venereology and Leprology | Published by Wolters Kluwer - Medknow