

Ensuring precise beard and eyebrow shaping with laser: Innovative use of tongue depressor

Problem

Hair growth in cosmetically undesirable locations has led individuals to use various hair removal methods. Temporary hair removal methods such as shaving, tweezing and threading may cause irritation and are not effective in the long term.^{1,2} With laser hair removal becoming a popular method to achieve permanent hair reduction, patients demand it for all areas including the beard, hair margins and eyebrows. Shaping the beard and eyebrows with lasers can be difficult and tricky. In the Middle East, the men take pride in clean-cut beard shapes. Therefore, laser hair reduction entails giving precise lines along the beard margins, which could be difficult to achieve. Running the laser close to the shaved margins runs a risk of uneven hair reduction giving an unpleasant look due to the mechanics involved in targeting the laser beam. Standard laser hand pieces have a round spot size emitting beams with a Gaussian profile resulting in higher focal fluence at the center which reduces toward the edge of the spot, which when run along a straight line results in an imprecise shape due to variable targeting.³ To achieve a sharp even line one needs to use a non-reflective barrier, allowing the lasers to target the intended areas, at the same time, protecting the hair at the margins.

Solution

Here, we present an easy, inexpensive way to allow precise shaping along the beard margins with the aid of wooden, disposable tongue depressors. The patient is instructed to come after shaving as per the desired beard shape. The tongue depressor is kept just adjacent to the beard line either flat or at an angle to protect the hair inside the margin [Figure 1].

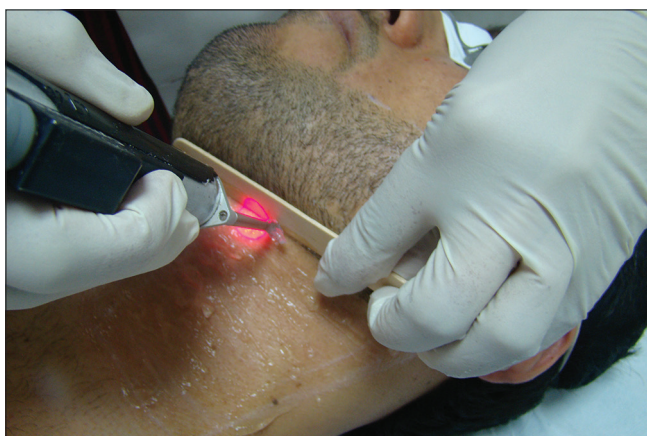

Figure 1: Correct alignment of the laser beam with the tongue depressor is necessary for optimal shaping

The laser beam should always be kept at a right angle to the spatula. Targeting with laser beam at an acute angle to the spatula, thereby allowing it to go beyond and below it, should be avoided. For effective targeting of hair at the margin using the maximum energy, the laser beam should run split over spatula and skin so that the center of the beam runs at the shaved border [Video 1]. For shaping the eyebrows, the patient should present 10–14 days post threading. Laser hair reduction for eyebrows should be done with proper eye protection and targeting, by pulling the skin up beyond the orbital margin and the laser beam being directed away from the eyeball [Figure 2].

We use long-pulsed Nd:YAG and Alexandrite laser with zimmer cooling (Cynosure Elite); with a 12 mm/15 mm hand piece for the beard and 7 mm/10 mm for the eyebrows. Using lasers with contact hand piece needs practice and further modifications. Hand piece should be placed after pre-cooling, with the tongue depressor held firmly down with the thumb and index finger of the non-dominant hand so that it does not move while moving the laser. This would limit the user to perform the procedure slowly while targeting a small area at a time.

Using a simple wooden tongue depressor is an easy, inexpensive and effective way of ensuring a permanent clean sharp look desired by many.

Declaration of patient consent

The authors certify that they have obtained all appropriate patient consent forms. In the form, the patient has given his

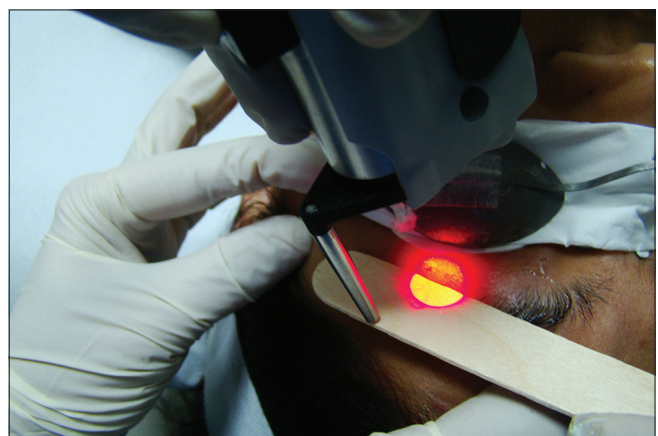


Figure 2: Using tongue depressor to give precise shaping of eyebrows

consent for his images and other clinical information to be reported in the journal. The patient understand that name and initials will not be published and due efforts will be made to conceal identity, but anonymity cannot be guaranteed.

Financial support and sponsorship

Nil.

Conflicts of interest

There are no conflicts of interest.

Seema Satyapal Singh, Minal Patwardhan Andrade

Minal Specialised Clinic Dermatology, Sharjah, UAE

Correspondence: Dr. Seema Satyapal Singh,
Minal Specialised Clinic Dermatology, 401 C Block, Crystal Plaza,
Buhaira Corniche, PO Box 24680, Sharjah, UAE.
E-mail: ssatyapal@yahoo.com

References

1. Marchell NL, Alster TS. Evaluation of temporary and permanent hair removal methods. *J Aesth Cosmet Dermatol Surg* 1999;1:3-12.
2. Olsen EA. Methods of hair removal. *J Am Acad Dermatol* 1999;40:143-55.
3. Lukac M, Grad L, Nemes K. Scanner Optimized Efficacy (SOE) Hair Removal with the VSP Nd: YAG Lasers. *J Laser and Health Acad* 2007;No.3/3.

This is an open access journal, and articles are distributed under the terms of the Creative Commons Attribution-NonCommercial-ShareAlike 4.0 License, which allows others to remix, tweak, and build upon the work non-commercially, as long as appropriate credit is given and the new creations are licensed under the identical terms.

Video available on: www.ijdv.com

Access this article online

Quick Response Code:



Website:

www.ijdv.com

DOI:

10.4103/ijdv.IJDVL_115_18

How to cite this article: Singh SS, Andrade MP. Ensuring precise beard and eyebrow shaping with laser: Innovative use of tongue depressor. *Indian J Dermatol Venereol Leprol* 2019;85:114-5.

Received: March, 2018. **Accepted:** July, 2018.

© 2018 Indian Journal of Dermatology, Venereology and Leprology | Published by Wolters Kluwer - Medknow