

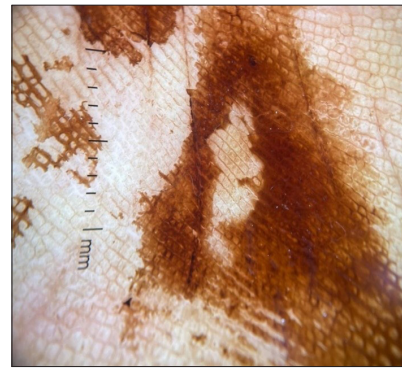
# Brownish palmar discolouration due to cashewnut dermatitis

A 45-year-old man reported a six-month history of asymptomatic brownish-black discolouration on both palms. He worked as a farmer and frequently handled raw cashewnuts and shell oil, which he sold manually. A skin examination revealed well-defined brown macules on his fingers and palms, while the rest of his skin appeared normal [Figure 1]. Based on his occupational history, along with clinical and dermoscopy findings [Figure 2], he was

diagnosed with cashewnut dermatitis. In the cashewnut, the space between the inner kernel and the double-layered outer shell contains a highly caustic brown, oily liquid rich in anacardic acid and cardol. Workers who handle cashewnut shells are exposed to the shell oil during the slicing process, which causes cauterisation, clinically presenting as brownish to black, thick layers of dead skin on the palmar and dorsal surfaces of their hands.



**Figure 1:** Brownish discoloration of the bilateral palms.



**Figure 2:** Brownish pigmentation of furrow and ridges on the palm. (Polarising dermoscopy, Dermlite dL4, 10x).

## Declaration of patient consent

The authors certify that they have obtained all appropriate patient consent.

## Financial support and sponsorship

Nil.

## Conflicts of interest

There are no conflicts of interest.

## Use of artificial intelligence (AI)-assisted technology for manuscript preparation

The authors confirm that there was no use of AI-assisted technology for assisting in the writing or editing of the manuscript and no images were manipulated using AI.

**Vijayasankar Palaniappan, Suganya Radhakrishnan, Kaliaperumal Karthikeyan**

Department of Dermatology, Venereology and Leprosy, Sri Manakula Vinayagar Medical College and Hospital, Madagadipet, Pondicherry, India.

## Corresponding author:

Dr. Vijayasankar Palaniappan,  
Department of Dermatology, Venereology and Leprosy, Sri Manakula Vinayagar Medical College and Hospital, Madagadipet, Pondicherry, India.  
vijayasankarpalaniappan@gmail.com

**How to cite this article:** Palaniappan V, Radhakrishnan S, Karthikeyan K. Brownish palmar discolouration due to cashewnut dermatitis. Indian J Dermatol Venereol Leprol. doi: 10.25259/IJDVL\_918\_2024

**Received:** June, 2024 **Accepted:** July, 2024 **Epub Ahead of Print:** July, 2024

**DOI:** 10.25259/IJDVL\_918\_2024

This is an open-access article distributed under the terms of the Creative Commons Attribution-Non Commercial-Share Alike 4.0 License, which allows others to remix, tweak, and build upon the work non-commercially, as long as the author is credited and the new creations are licensed under the identical terms.