

Post-traumatic ectopic nail

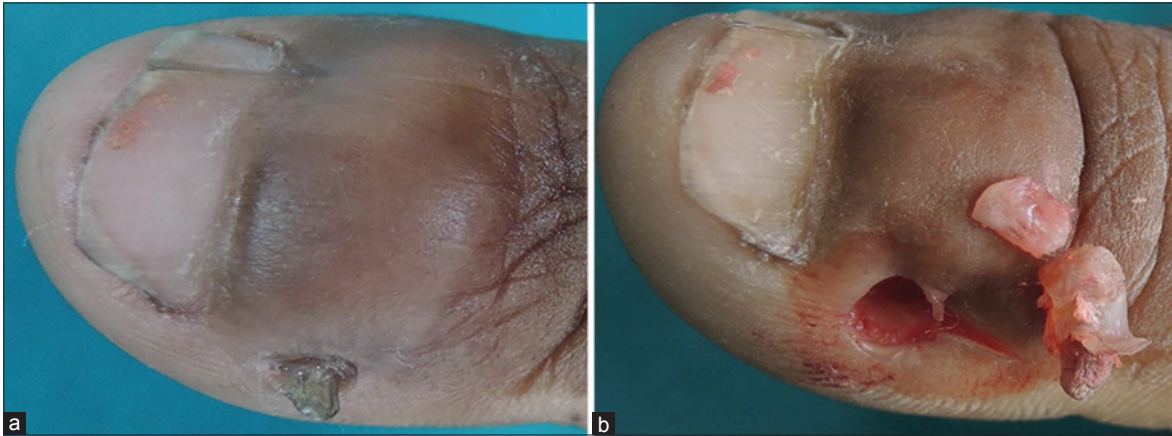


Figure 1: (a) Ectopic nail on left thumb with split nail deformity and scar, (b) excised ectopic nail with its matrix

A 38-year-old woman presented with a keratotic lesion on the left thumb for 1 year. Six months before the lesion was noted, she had sustained a cut on the medial-third of the distal nail of left thumb extending to the base of the distal phalanx. Examination revealed a 1 cm × 0.5 cm, keratotic, nail-like lesion [Figure 1a]. There was a longitudinal split on the medial third of the left thumb and the scar of the previous cut injury on the distal phalanx. The lesion was excised under distal digital block [Figure 1b]. Histopathological examination revealed nail plate and nail matrix confirming the diagnosis of ectopic nail.

Financial support and sponsorship

Nil.

Conflicts of interest

There are no conflicts of interest.

Binod Kumar Thakur, Shikha Verma, Ankit Jitani¹

Departments of Dermatology and STD and ¹Pathology, North Eastern Indira Gandhi Regional Institute of Health and Medical Sciences, Shillong, Meghalaya, India

Address for correspondence: Dr. Shikha Verma, Department of Dermatology and STD, North Eastern Indira Gandhi Regional Institute of Health and Medical Sciences, Shillong, Meghalaya, India. E-mail: shikha.b.thakur@gmail.com

Access this article online	
Quick Response Code:	Website: www.ijdvl.com
	DOI: 10.4103/0378-6323.171644

This is an open access article distributed under the terms of the Creative Commons Attribution-NonCommercial-ShareAlike 3.0 License, which allows others to remix, tweak, and build upon the work non-commercially, as long as the author is credited and the new creations are licensed under the identical terms.

For reprints contact: reprints@medknow.com

How to cite this article: Thakur BK, Verma S, Jitani A. Post-traumatic ectopic nail. Indian J Dermatol Venereol Leprol 2016;82:416.

Received: May, 2015. **Accepted:** July, 2015.