

# Dermoscopic features of telangiectasia macularis multiplex acquisita

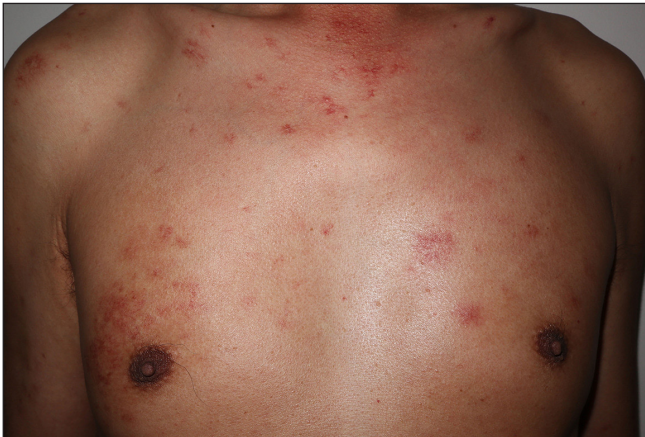Dear Editor,

Telangiectasia macularis multiplex acquisita (TMMA) is a rare condition that is characterised by numerous asymptomatic erythematous and/or brownish macules with telangiectasia, usually distributed on the upper arms and trunk.<sup>1</sup> Several underlying diseases have been reported associated with TMMA, especially chronic liver disease.<sup>2</sup> No previous reports could be found on using dermoscopy to evaluate TMMA.

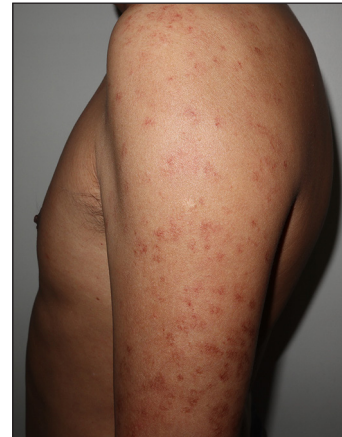A Chinese man aged 56 years presented with a series of asymptomatic, erythematous to brown skin eruptions on his upper arms and trunk which were appearing for the past 3 years. He had a history of hepatitis B for 10 years. Furthermore, a record of smoking and drinking for a duration exceeding 20 years was obtained. His dermatological examination revealed numerous well-demarcated erythematous to brownish macules with telangiectasia involving his back, bilateral upper limbs, and chest [Figures 1a and 1b]. Moreover,

several spider-like eruptions were also found. The examination by dermoscopy demonstrated an erythematous-brownish background with a striking angioid streak pattern (a central arteriole with superficial radiating small vessels attributed to spider-like eruptions) and linear-irregular branching vessels [Figures 2a and 2b]. A skin biopsy showed that the basal layer of the epidermis had obvious hyperpigmentation and lymphohistiocytic infiltration was sparse around the dilated vessels in the upper dermis [Figure 3a]. No mast cells were observed by Giemsa staining [Figure 3b]. The routine blood investigations, including liver and kidney function tests were unremarkable. Hepatitis B s-antigen, E antibody or Anti-e, and Anti-c were positive. These findings were consistent with the diagnosis of TMMA.

The aetiology of the TMMA is unknown. Vessel defects resulting from either a birth defect or ageing may play a role in pathogenesis. In addition, it has been inferred that abnormal oestrogen metabolism in liver disease especially as viral markers are positive may cause vascular changes.<sup>2</sup>



**Figure 1a:** Multiple well-demarcated erythematous to brownish macules with telangiectasia on the chest.



**Figure 1b:** Multiple well-demarcated erythematous to brownish macules with telangiectasia on bilateral upper limbs.

**How to cite this article:** Wang X. Dermoscopic features of telangiectasia macularis multiplex acquisita. *Indian J Dermatol Venereol Leprol.* 2025;91:S82-S84. doi: 10.25259/IJDVL\_762\_2023

**Received:** July, 2023 **Accepted:** October, 2023 **Epub Ahead of Print:** April, 2024 **Published:** April, 2025

**DOI:** 10.25259/IJDVL\_762\_2023 **PMID:** 38841960

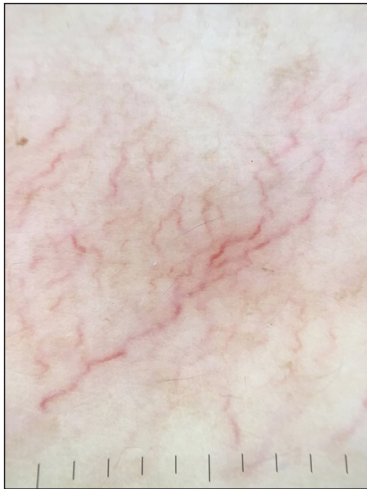
This is an open-access article distributed under the terms of the Creative Commons Attribution-Non Commercial-Share Alike 4.0 License, which allows others to remix, transform, and build upon the work non-commercially, as long as the author is credited and the new creations are licensed under the identical terms.

Some authors suggested the entity ‘acquired bilateral telangiectatic macules (ABTM)’ for people with numerous telangiectatic pigmented macules mostly on their upper arms which demonstrated similar clinical features and histopathological characteristics as TMMA.<sup>3</sup> Furthermore, a disease called acquired bilateral telangiectasia macularis eruptive perstans (TMEP) is a common disorder among middle-aged or older Asian men. Some proposals acquired bilateral TMEP and ABTM should be regarded as a continuum of disorder.<sup>4</sup> Hence, we think that the identical disease entity was addressed in all three instances owing to the remarkably similar clinical and pathological outcomes.

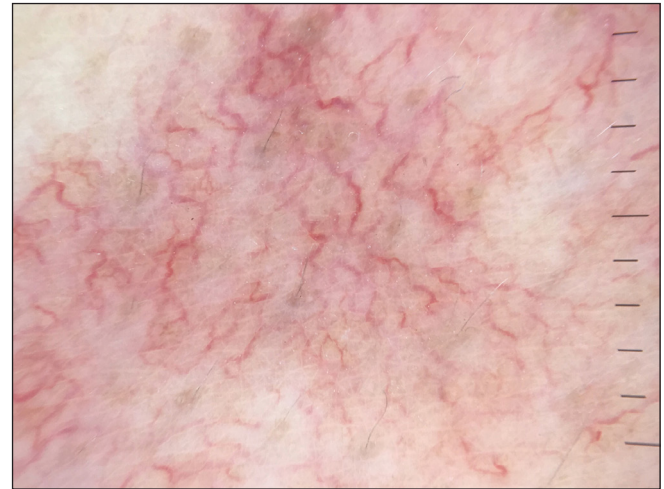The differential diagnosis should include some diseases with similar telangiectasia, such as TMEP and generalised essential telangiectasia (GET) [Table 1]. TMEP is often confused with TMMA due to its similar clinical presentation. The dermoscopy showed that TMEP has a typical reticular

vascular pattern of linear and branching vessels.<sup>5</sup> However, the vessels in TMMA are mostly linear and irregular with few showing branching. In addition, the histological features of TMEP indicate that there are infiltrations of mast cells, primarily situated around dilated capillaries in the upper dermis which are accentuated by Giemsa staining. The majority of GET cases are middle-aged females, characterised by telangiectasia on the lower legs, gradually progressing to the upper legs, abdomen, and arms. The presence of fine arborizing vascular dilations on dermoscopy helps to differentiate GET from TMMA.<sup>6</sup>

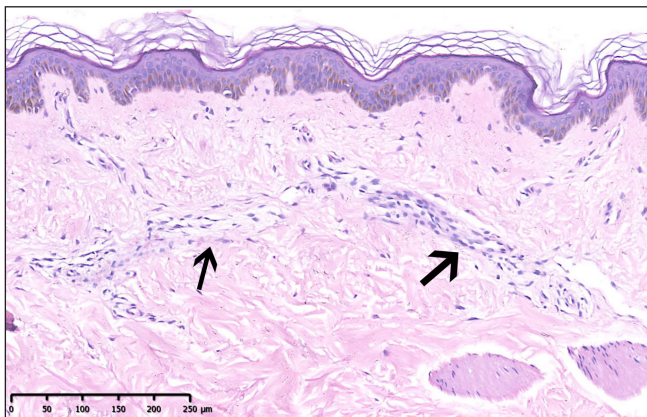
Due to its benign nature and asymptomatic course, patients usually do not require treatment. For aesthetics, a pulsed dye laser could be chosen, considering its effect on telangiectasia. In conclusion, TMMA is not uncommon and probably unreported among Asian men. Dermoscopic features can be used to make the clinical diagnosis more accurate and avoid unnecessary skin biopsies.



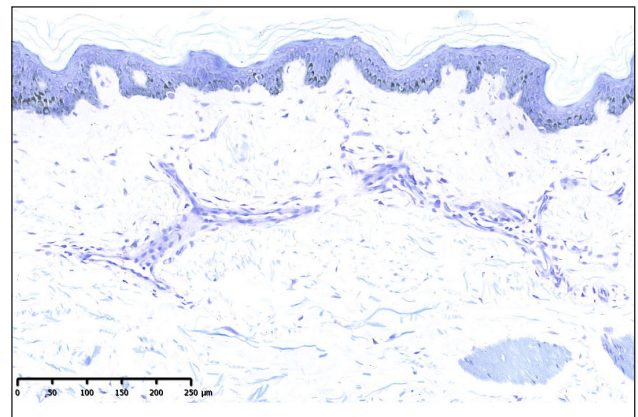
**Figure 2a:** Dermoscopy demonstrating erythematous-brownish background with prominent angiod streak pattern or linear-irregular branching vessels (polarising, original magnification x10).



**Figure 2b:** Dermoscopy demonstrating erythematous-brownish background with prominent angiod streak pattern or linear-irregular branching vessels (polarising, original magnification x10).



**Figure 3a:** Histopathology revealed marked hyperpigmentation in the basal layer of the epidermis, and mild lymphohistiocytic infiltration (black arrows) around the dilated vessels in the upper dermis (Haematoxylin & eosin, 100x).



**Figure 3b:** No mast cells were observed (Giemsa stain, 100x).

**Table 1: Distinctive features of TMMA, TMEP, and GET**

	<b>TMMA</b>	<b>TMEP</b>	<b>GET</b>
Age of onset	Adult	Adult	Adult
Site of predilection	Bilateral upper arms and trunk	Trunk and limbs	Lower legs
Association	Chronic liver diseases	-	-
Dermoscopic patterns	Predominantly linear-irregular, with few showing branching	Reticular vascular pattern of linear and branching vessels	Fine arborizing vascular dilation
Histopathology	Mild inflammation with or without telangiectasia in the upper dermis	Mast cells in the upper dermis and clustered around dilated capillaries	Dilated blood vessels in upper dermis

TMMA: Telangiectasia macularis multiplex acquisita, TMEP: Telangiectasia macularis eruptiva perstans, GET: Generalised essential telangiectasia

**Declaration of patient consent:** The author certify that they have obtained all appropriate patient consent.

**Financial support and sponsorship:** Nil.

**Conflicts of interest:** There are no conflicts of interest.

**Use of artificial intelligence (AI)-assisted technology for manuscript preparation:** The author confirm that there was no use of artificial intelligence (AI)-assisted technology for assisting in the writing or editing of the manuscript and no images were manipulated using AI.

**Xiaopo Wang<sup>1</sup>**

<sup>1</sup>Department of Pathology, Hospital for Skin Disease and Institute of Dermatology, Chinese Academy of Medical Sciences and Peking Union Medical College, Nanjing, China

**Corresponding author:**

Dr. Xiaopo Wang,

<sup>1</sup>Department of Pathology, Hospital for Skin Disease and Institute of Dermatology, Chinese Academy of Medical Sciences and Peking Union Medical College, Nanjing, China.

13770757675@163.com

## References

1. Chang CH, Lu PH, Kuo CJ, Yang CH. Telangiectasia macularis multiplex acquisita: A new entity in Chinese populations and an analysis of associated factors. *Int J Dermatol* 2013;52:426–31.
2. Wang G, Chen H, Yang Y, Wu K, Sun J. Telangiectasia macularis multiplex acquisita accompanied by hepatitis B infection. *Australas J Dermatol* 2017;58:e5–e7.
3. Park JH, Lee DJ, Lee YJ, Jang YH, Kang HY, Kim YC. Acquired bilateral telangiectatic macules: A distinct clinical entity. *JAMA Dermatol* 2014;150:974–7.
4. Moon HR, Kim YJ, Jung JM, Won CH, Lee MW, Choi JH, *et al.* Acquired bilateral telangiectasia macularis eruptiva perstans: A unique clinical feature of photodamaging rather than a subtype of cutaneous mastocytosis. *J Dermatol* 2017;44:1276–80.
5. Unterstell N, Lavorato FG, Nery NS, Mann D, Alves M de F, Barcaui C. Dermoscopic findings in telangiectasia macularis eruptiva perstans. *An Bras Dermatol* 2013;88:643–5.
6. Knopfel N, Martin-Santiago A, Saus C, Escudero-Gongora MM, Del Pozo LJ, Gomez C. Extensive acquired telangiectasias: Comparison of generalized essential telangiectasia and cutaneous collagenous vasculopathy. *Actas Dermosifiliogr* 2017;108:e21–e26.