

References

1. Owczarek-Drabińska JE, Radwan-Oczko M. A case of lingua villosa nigra (black hairy tongue) in a 3-month-old infant. *Am J Case Rep* 2020;21:e926362.
2. Gurvits GE, Tan A. Black hairy tongue syndrome. *World J Gastroenterol* 2014;20:10845–50.
3. Schlager E, St Claire C, Ashack K, Khachemoune A. Black hairy tongue: predisposing factors, diagnosis, and treatment. *Am J Clin Dermatol* 2017;18:563–9.
4. Pouloupoulos AK, Antoniadis DZ, Epivatianos A, Grivea IN, Syrogiannopoulos GA. Black hairy tongue in a 2-month-old infant. *J Paediatr Child Health* 2008;44:377–9.
5. Rosebush MS, Briody AN, Cordell KG. Black and Brown: Non-neoplastic pigmentation of the oral mucosa. *Head Neck Pathol* 2019;13:47–55.
6. Rice SM, Lal K. Hyperpigmented macules of the tongue in a 15-year-old girl. *Pediatr Dermatol* 2021;38:941–2.
7. Júnior MH, Souza PE, Soares RV, de Andrade BA, de Almeida OP, Horta MC. oral congenital melanocytic nevus: A rare case report and review of the literature. *Head Neck Pathol* 2015;9:481–7.
8. Körber A, Voshege N. Black hairy tongue in an infant. *CMAJ* 2012;184:68.

Subungual mass in a patient of xeroderma pigmentosum: Looking beyond malignant transformation

Dear Editor,

A 16-year-old girl, with a known case of xeroderma pigmentosum, presented with a slowly progressive firm, non-tender skin-coloured subungual plaque in the middle finger of her left hand for the past 4 years. The plaque appeared to arise from the underlying nail bed, causing the nail plate to lift with a concave dorsal curvature [Figure 1]. Subungual yellowish to dark brown hyperkeratotic debris was present in a few other fingernails. Onychoscopic evaluation of the subungual mass showed whitish-yellow structureless areas,

arranged in a whorled pattern with adherent whitish scaling [Figure 2]. KOH microscopy from the subungual debris did not show any hyphae. On the face, there were some hyperpigmented papulo-nodules and barely elevated plaques with fine overlying scaling and haemorrhagic crusting, in a background of hyper- and hypopigmented macules. These nodules had shown features of basal cell carcinoma on histological evaluation. She had a history of photosensitivity and a tendency of keloid formation. Her two younger sisters also had xeroderma pigmentosum. There was no history of consanguinity or similar complaints in other family

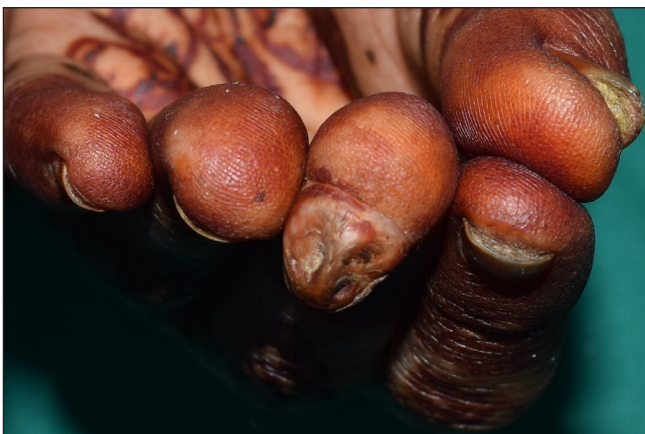

Figure 1: Skin-coloured, firm subungual plaque lifting the nail plate in the middle finger of the left hand.

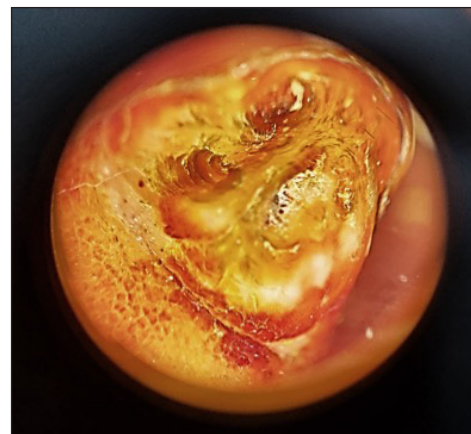


Figure 2: On onychoscopy, whitish yellow structureless areas, somewhat arranged in a whorled pattern with adherent whitish scaling were seen (Heine Delta 20T, magnification 10x).

How to cite this article: Ahuja R, Kumar D, Arava S, Bhari N. Subungual mass in a patient of xeroderma pigmentosum: Looking beyond malignant transformation. *Indian J Dermatol Venereol Leprol.* 2024;90:806-8. doi: 10.25259/IJDVL_944_2023

Received: September, 2023 **Accepted:** December, 2023 **Epub Ahead of Print:** April, 2024 **Published:** October, 2024

DOI: 10.25259/IJDVL_944_2023 **PMID:** 38841967

This is an open-access article distributed under the terms of the Creative Commons Attribution-Non Commercial-Share Alike 4.0 License, which allows others to remix, transform, and build upon the work non-commercially, as long as the author is credited and the new creations are licensed under the identical terms.

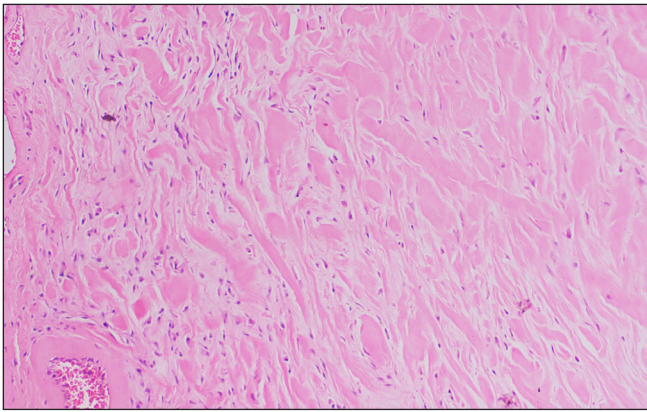


Figure 3a: Histopathology showed haphazardly arranged bundles of homogeneously eosinophilic thick collagen (Haematoxylin and Eosin, 100x).

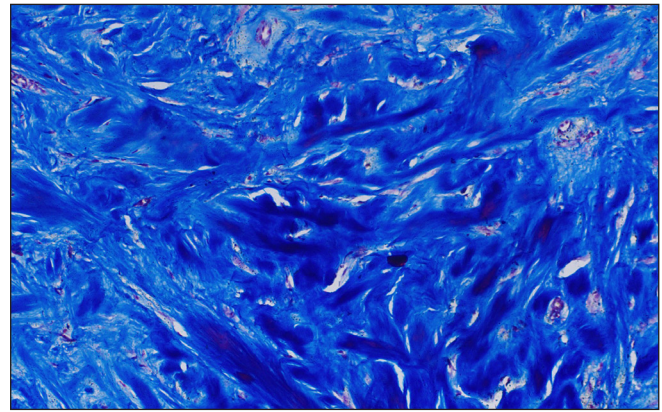


Figure 3b: The thick collagen bundles are more apparent on Masson's Trichrome (Masson's trichrome, 200x).

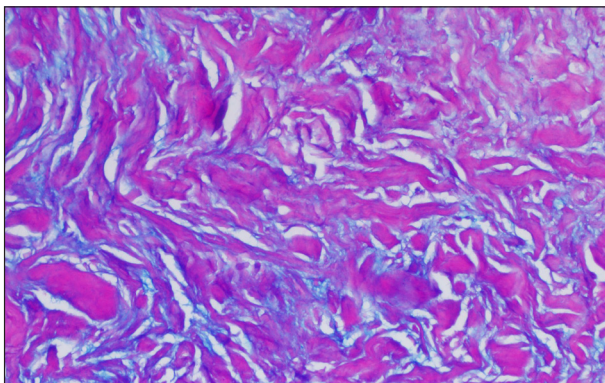


Figure 3c: Presence of mucin between the collagen bundles highlighted on Alcian Blue stain (Alcian Blue-Periodic acid-Schiff, 200x).

members. The patient did not recall any significant trauma before the appearance of the nail changes. A 4 mm punch biopsy was performed from the subungual mass considering subungual fibroma, fibrokeratoma and keratoacanthoma as clinical differentials.

Histopathological evaluation of the subungual mass showed a hyperkeratotic stratum corneum with fibroblastic proliferation in the dermis. There were haphazardly arranged bundles of homogeneously eosinophilic thick collagen, with the presence of mucin between the collagen bundles in a few areas, more apparent on alcian blue. The thick collagen bundles were more prominent on Masson's trichrome staining [Figure 3].

A final diagnosis of subungual keloid was made. The patient was advised photoprotection, oral isotretinoin and topical 5% imiquimod for the pre-malignant lesions on the face. Surgical excision has been planned for the larger histologically proven basal cell carcinoma. The patient was offered intralesional steroids for the subungual keloid, but was not keen on monthly injections as the lesion was largely asymptomatic.

Toe keloids are infrequently discussed in literature, classically occurring at the tip or lateral aspect of the digits on the dorsal aspect, following nail surgeries for ingrown toenails and recurrent paronychia.¹ This is unlike our case where the keloid

was subungual, possibly arising from the nail bed. Although there was no history of previous surgical intervention or a prior nail unit disease in our case, a possibility of unnoticed inadvertent trauma cannot be excluded.

The absence of punctate haemorrhagic spots on gross examination with no tiered parakeratosis or koilocytes on histology ruled out a subungual wart. Histologically, our case lacked dermal fibrosis with multiple ectatic vessels, characteristic of per-ungual fibromas.² The absence of a central keratinous crater and dyskeratotic eosinophilic cells made subungual keratoacanthoma highly unlikely.³ The tumour was broad-based, not firm and with no tapering, and so did not conform to the finger or hook-like shape of a subungual fibrokeratoma.⁴ Further, the collagen bundles were not oriented in the vertical axis of the tumour. Instead, the presence of disorganised thick hyalinized collagen (keloidal collagen) bundles in a mucinous ground substance⁵ suggested a diagnosis of subungual keloid.

The presence of keloidal tendency in our patient supports our diagnosis. Epigenetic influences on wound healing suggest that oxidative DNA damage in keloidal skin may contribute to its pathogenesis. Fibroblasts with Xeroderma Pigmentosum type C (XPC) mutations exhibit impaired base excision repair leading to increased oxidative DNA damage.⁶ Thus, keloidal tendency in these patients is likely a true association, rather than a chance occurrence. Further, the subungual hyperkeratosis in other nails in our patient has been reported in other related genodermatoses like Cockayne syndrome, which involves a mutation in similar genes affecting nucleotide excision repair.⁷ However mutational analyses for a specific complementation subtype of xeroderma pigmentosum could not be done in our case.

In conclusion, subungual keloids are rarely reported and possibly underdiagnosed as they mimic other subungual pathologies. A history of keloidal tendency and the presence of thick hyalinised haphazardly arranged collagen on histology were strong pointers towards this diagnosis. We should also

be aware that not all tumours occurring in a patient with xeroderma pigmentosum are necessarily pre-malignant.

Declaration of patient consent: The authors certify that they have obtained all appropriate patient consent.

Financial support and sponsorship: Nil.

Conflicts of interest: There are no conflicts of interest.

Use of artificial intelligence (AI)-assisted technology for manuscript preparation: The authors confirm that there was no use of artificial intelligence (AI)-assisted technology for assistance in writing or editing of the manuscript, and no images were manipulated using AI.

***Rhea Ahuja, Devesh Kumar,
Sudheer Arava¹, Neetu Bhari***

Department of Dermatology and Venereology, ¹Pathology,
AIIMS, New Delhi, India

Corresponding author:

Dr. Neetu Bhari,

Department of Dermatology and Venereology,
AIIMS, New Delhi, India.
drntbhari@gmail.com

References

1. Kaku C, Matsunaga N, Kuribayashi S, Ogawa R. Toe Keloids treated with core excision, postoperative radiotherapy, and steroid plaster. *Plast Reconstr Surg Glob Open* 2020;8:e3085.
2. Quist SR, Franke I, Sutter C, Bartram CR, Gollnick HP, Leverkus M. Periungual fibroma (Koenen tumors) as isolated sign of tuberous sclerosis complex with tuberous sclerosis complex 1 germline mutation. *J Am Acad Dermatol* 2010;62:159–61.
3. Miguel-Gomez L, Turrion-Merino L, Reguero-Calleja ME, Muñoz-Zato E. Subungual keratoacanthoma. *Indian J Dermatol* 2015;60:623–4.
4. Jahan N, Ashwini PK, Chethana SG, Betkerur J, Shastry V. Horn on the nail: Acquired unguis fibrokeratoma. *J Cutan Aesthet Surg* 2021;14:121–4.
5. Lee JY, Yang CC, Chao SC, Wong TW. Histopathological differential diagnosis of keloid and hypertrophic scar. *Am J Dermatopathol* 2004;26:379–84.
6. Fayyad N, Kobaisi F, Beal D, Mahfouf W, Ged C, Morice-Picard F, *et al.* Xeroderma pigmentosum C (XPC) mutations in primary fibroblasts impair base excision repair pathway and increase oxidative DNA damage. *Front Genet* 2020;11:561687.
7. Frouin E, Laugel V, Durand M, Dollfus H, Lipsker D. Dermatologic findings in 16 patients with Cockayne syndrome and cerebro-oculo-facial-skeletal syndrome. *JAMA Dermatol* 2013;149:1414–8.