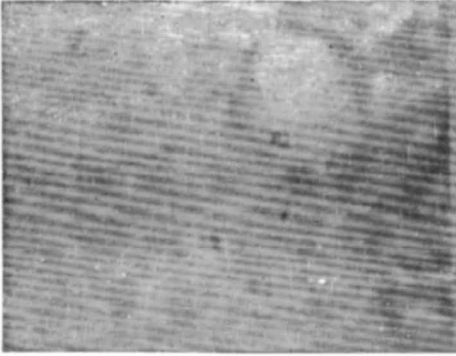
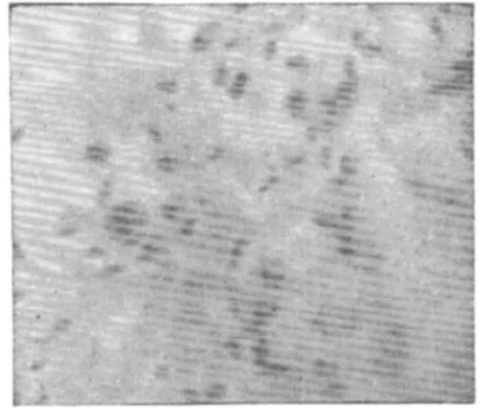


## SPOROTRICHOSIS IN MADRAS—(Contd.)



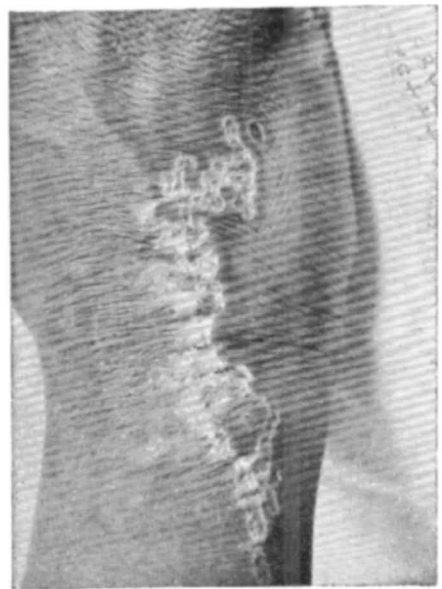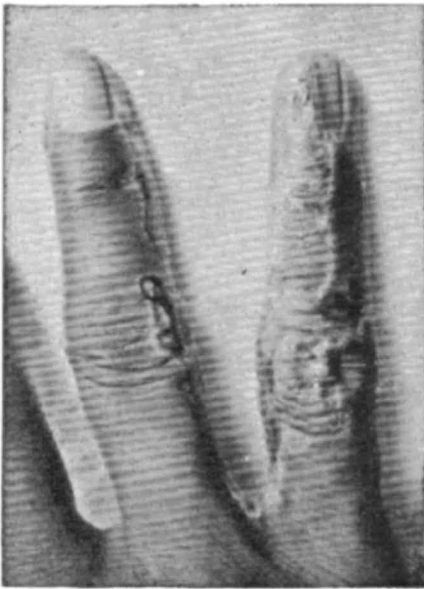
**Fig. 5** Smear of the peritoneal exudate showing oval or cigar shaped yeast cells. Gram's stain x 450.



**Fig. 6** Section of the mouse testis showing numerous oval bodies. Brown and Brenn's modification of Gram stain x 450.

---

### WHAT IS YOUR DIAGNOSIS ?

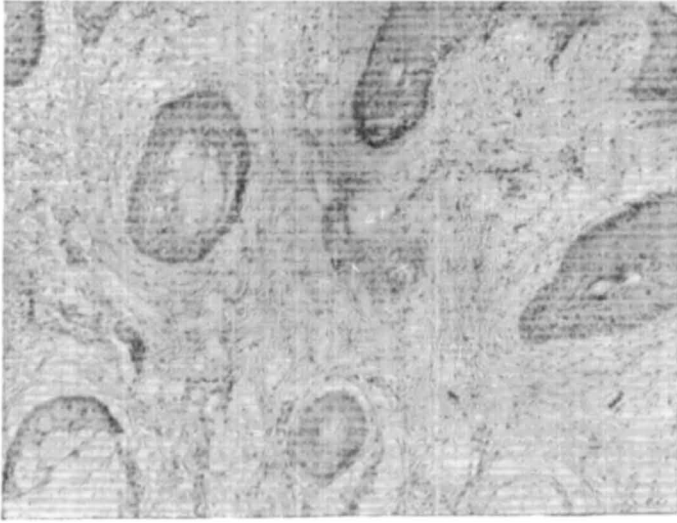


Twenty-three year old male patient presented with asymptomatic skin lesion of 14 years' duration. It started on the right arm as a small round raised lesion and gradually spread proximally on to the chest wall and distally down to the fingers. There were no constitutional symptoms. Family history was noncontributory.

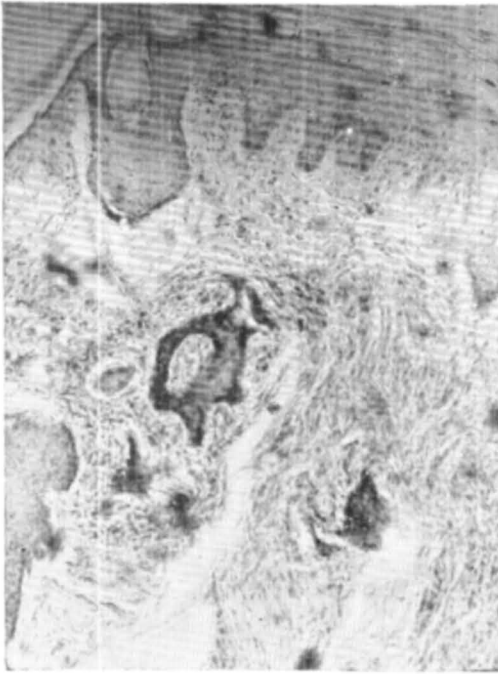
**Differential Diagnosis :** 1. Porokeratosis of Mibelli  
2. Lupus Vulgaris      3. Linear atrophic Lichen Planus

(Answer Page No. 147)

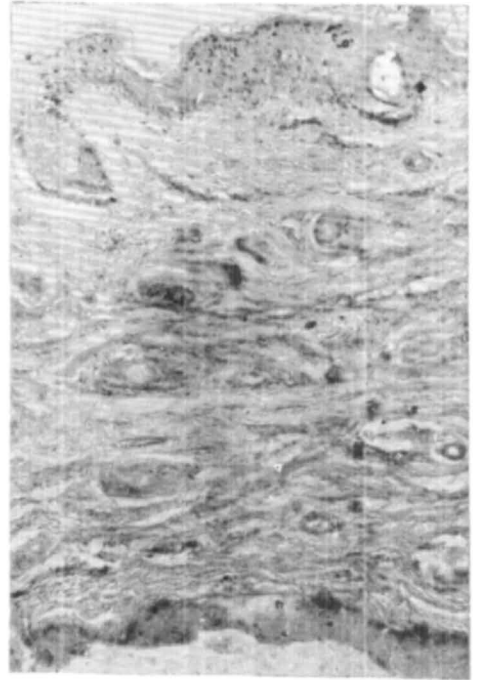
ADENOMA SEBACEUM — A HISTOPATHOLOGICAL REAPPRAISAL  
—F. Handa, et al



**Fig. 1** Photomicrograph (H.P.)



**Fig. 2** Photomicrograph (L.P.)



**Fig. 3** Photomicrograph (L.P.)