

Current understanding of frictional dermatoses: A review

Gulhima Arora, Sujay Khandpur¹, Anuva Bansal², Bhavishya Shetty², Sonia Aggarwal³, Sushobhan Saha³, Soumya Sachdeva⁴, Meghna Gupta², Ananya Sharma¹, Kumari Monalisa², Molisha Bhandari⁵, Anjali Bagrodia²

Mehktagul Dermaclinic, ¹Department of Dermatology and Venereology, All India Institute of Medical Sciences, ²Department of Dermatology and Venereology, Maulana Azad Medical College, ³Department of Dermatology and Venereology, University College of Medical Sciences, ⁴Department of Dermatology and Venereology, Atal Bihari Vajpayee Institute of Medical Sciences and Dr. RML Hospital, ⁵Department of Dermatology and Venereology, Vardhaman Mahavir Medical College and Safdarjung Hospital, New Delhi, India.

Abstract

Human skin is continually exposed to internal and external forces, dynamic as well as static. The skin is normally flexible and can resist mechanical trauma due to friction, pressure, vibration, suction and laceration to a considerable degree. However, an excess of these forces can abnormally affect the structure and function of the skin, setting the stage for the development of a skin disorder. Repetitive trauma can cause lichenification, hyperpigmentation, erythema, scaling, fissuring, blisters, ulceration and chronic alterations. Frictional dermatoses is an under-recognised entity with no clear-cut definition and encompasses a variety of terms such as frictional dermatitis, frictional melanosis, frictional pigmentary dermatoses and certain other named entities, many of which are confusing. The authors propose to define frictional dermatoses as 'a group of disorders caused by repetitive trauma to the skin as a result of friction of varied aetiology which can have a wide range of cutaneous manifestations depending on the type of insult.' The exact prevalence of frictional dermatoses as a separate entity is unknown. Authors who conducted this review include a group of dermatologists and post graduate students from various institutions. Literature was reviewed through PubMed, Medscape, Medline, ResearchGate and Google Scholar using the terms 'frictional dermatitis,' 'friction and skin,' 'dermatoses and culture,' 'clothing dermatitis,' 'friction melanosis,' 'PPE induced dermatoses in COVID-19 era,' etc. A total of 122 articles were reviewed and 100 articles among them were shortlisted and included in the study, after removing duplications. The review was followed up with further deliberation which resulted in the formulation of a new definition and classification of frictional dermatoses taking into account the morphology, histopathological characteristics, anatomical region affected and the major predisposing factors. The rising incidence of mechanical dermatoses in the COVID-19 era was also emphasised.

Key words: Cultural dermatoses, friction blisters, frictional dermatoses, occupational dermatoses, sports dermatoses

Introduction

Human skin is continually exposed to internal and external dynamic as well as static forces. The skin is normally flexible and can resist mechanical trauma to a considerable degree. However, an excess of these forces can abnormally affect the structure and function of the skin, setting the stage for the development of a skin disorder.

The term 'frictional dermatoses' encompasses a variety of entities such as frictional dermatitis, frictional melanosis, frictional pigmentary dermatoses and certain other named conditions, many of which are confusing. Friction is defined as the resistance experienced by a body when it comes in contact with another. Any imbalance in the frictional forces may lead to acute or chronic injury. Friction can also involve the mucosae¹⁻⁴ hair⁵⁻⁸ and nails.^{9,10}

How to cite this article: Arora G, Khandpur S, Bansal A, Shetty B, Aggarwal S, Saha S, *et al.* Current understanding of frictional dermatoses: A review. *Indian J Dermatol Venereol Leprol* 2023;89: 170–88.

Corresponding author: Dr. Anuva Bansal, House No. 2, National Park, Lajpat Nagar-4, New Delhi, India. anuvabansal22@gmail.com

Received: May, 2021 **Accepted:** October, 2021 **EPub Ahead of Print:** November, 2022 **Published:** March, 2023

DOI: 10.25259/IJDVL_519_2021 **PMID:** 36461803

This is an open-access article distributed under the terms of the Creative Commons Attribution-Non Commercial-Share Alike 4.0 License, which allows others to remix, transform, and build upon the work non-commercially, as long as the author is credited and the new creations are licensed under the identical terms.

Frictional dermatoses is an under-recognised entity with no clear-cut definition. The authors propose to define frictional dermatoses as ‘a group of disorders caused by repetitive trauma to the skin as a result of friction of varying aetiology which can have a wide range of cutaneous manifestations depending on the type of insult.’

The exact prevalence of frictional dermatoses as a separate entity is unknown. However, various studies have reported the prevalence of individual conditions. A study from Germany reported that 21.6% (89/412) musicians had musical instrument related frictional skin disorders.^{11,12} Friction accounted for 11.3% of occupational dermatoses due to non-glove personal protective equipment amongst healthcare workers in UK.^{1,11}

Materials and Methods

Authors who conducted the review include a group of dermatologists and postgraduate students from various institutions. They are members of the Resident Connect Committee of the Indian Association of Dermatologists Venereologists and Leprologists of the Delhi State Branch. It was a voluntary exercise proposed by the Chairperson of the Resident Connect Committee, Delhi State Branch. After a framework was decided on by participation of all authors on a virtual platform, different sections of the ‘review of literature’ were assigned to each. Literature was reviewed through PubMed, Medscape, Medline, ResearchGate and Google Scholar using the terms ‘frictional dermatitis,’ ‘friction and skin,’ ‘dermatoses and culture,’ ‘clothing dermatitis,’ ‘friction melanosis,’ ‘PPE induced dermatoses in COVID-19 era,’ etc. A total of 122 articles were reviewed and 100 articles were shortlisted for inclusion in the study, after removing duplications. The selected articles included brief communications, letters to editor, case reports, case series, observational studies, review articles and randomised controlled trials. The review was followed up with further deliberation and a new definition and classification for frictional dermatoses was formulated. The rising incidence of mechanical dermatoses in the COVID-19 era was also emphasised upon.

Predisposing Factors

Friction not only causes new dermatoses in individuals but can also exacerbate existing ones.¹⁰ The susceptibility of an individual’s skin to friction differs and is influenced by factors both extraneous and inherent, such as the presence of pre-existing diseases and genetic or racial differences, respectively [Table 1].

It is important to identify the predisposing factors that may be largely apparent or sometimes inconspicuous, but which are critical in the management of frictional dermatoses.

Pathogenesis

In simple terms, friction is the rubbing of one surface over the other or the force that resists movement between two bodies

Table 1: Predisposing factors of frictional dermatoses

Predisposing factor	Pathogenesis
Inherent factors	
Extremes of age ¹³ <ul style="list-style-type: none"> • Neonates • Elderly 	<ul style="list-style-type: none"> • Reduced ability to tolerate the frictional force • Immature skin, increased skin fragility • Decrease in flexibility, elasticity and resilience with age
Gender ¹⁰	<ul style="list-style-type: none"> • Primary – Females are more prone as compared to males due to increased micro-trauma as a result of household activities • Secondary – Exposure to contact allergens or irritants
Body site ¹⁴	<ul style="list-style-type: none"> • Acral areas – Stiff skin-shear strain leads to epidermal layer separation • Intertriginous areas – Frequent rubbing, moisture retention, increased friction
Sweating ¹⁴	<ul style="list-style-type: none"> • Increase in hydration of stratum corneum and COF
Extraneous factors	
Temperature	<ul style="list-style-type: none"> • Increased temperature – Sweating-moisture retention-raised COF – frictional dermatoses
Relative humidity ¹⁴	<ul style="list-style-type: none"> • Increased humidity – Moisture retention-occlusion-increased friction
Clothing <ul style="list-style-type: none"> • Type^{10,14,15} 	<ul style="list-style-type: none"> • Tight clothes, collared neck shirts – constant rubbing and microtrauma • Increased friction and moisture at the skin-fabric interface – mechanical skin irritation • Prolonged use of nylon clothes/towels – pigmentation of skin • Nylon and wool – most commonly implicated– frictional dermatitis
Occupation and habits ¹⁶⁻¹⁸ <ul style="list-style-type: none"> • Sportsmen • Musicians • Computer use • Health care workers • Indigenous cultural practices 	<ul style="list-style-type: none"> • Primary– Prolonged microtrauma to skin, injury to stratum corneum, defective epidermal barrier; dynamic friction-stress and shear strain in tissues– skin injury • Secondary – Increased sweating increases COF • Primary – Prolonged contact and constant rubbing of the instruments at a particular body site • Secondary – Presence of saliva increases the COF in flautist chin • Prolonged hours of computer use leading to frictional dermatoses over the hands and fingers • Primary – personal protective equipment induced dermatoses as a result of friction • Secondary – sweating and humidity increase the COF • Friction due to excessive use of alcohol-based sanitizer – skin barrier disruption • Drawstring dermatitis due to tightly worn sari and salwar-kameez • prayer nodules in Muslims • threading induced koebnerisation of pre-existing dermatoses

COF: Coefficient of friction

[Figure 1].¹⁹ The manifestation of friction related skin injury depends on the following factors:

Type of friction

Static friction, which refers to the friction between two still surfaces, dynamic friction which prevents motion between two sliding surfaces and shear force causing shear strain on deeper layers.¹⁹

Intensity of the force

Low intensity stimulus, which causes rapid cellular turnover and hyperkeratosis, or a high intensity one leads increased hydrostatic pressure and intraepidermal bullae formation.²⁰

Nature of the surface

The co-efficient of friction depends on the type of surface, moisture content, body site as well as type of fabric covering the skin.

- a. **Moisture content:** The presence of moisture increases the co-efficient of friction making the well hydrated skin over palms and fingers amenable to frictional injuries. Conditions such as humidity, sweating and occlusion increase the moisture content of the skin, thereby increasing the Coefficient of friction¹⁴
- b. **Body site:** There is increased moisture retention as well as constant rubbing between the skin surfaces of flexures and intertriginous areas. This further increases the co-efficient of friction¹⁴
- c. **Type of fabric:** The type and structure of textiles can have a considerable impact on the type of friction forces as well as skin hydration. The fabrics most commonly associated with dermatoses include nylon and wool.¹⁵

Classification

As previously outlined, no single definition exists for frictional dermatoses and therefore currently there is no accepted classification encompassing the wide range of conditions that can be categorised under this entity. We propose a classification that takes into consideration the morphology, histopathological characteristics, anatomical

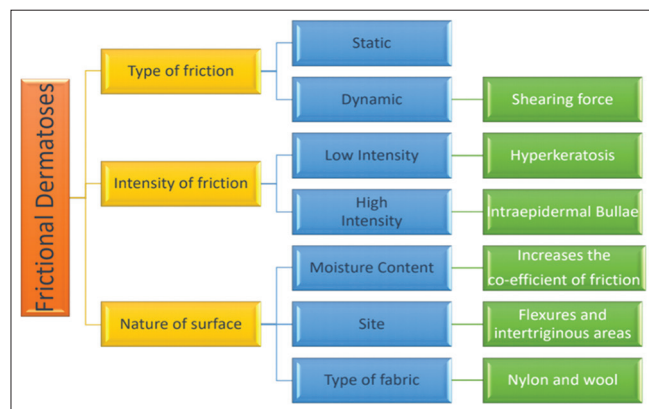


Figure 1: Pathogenesis of frictional dermatoses. Friction is the rubbing of one surface over the other or the force that resists movement between two bodies. The manifestation of friction related skin injury depends on: type of friction which can be static or dynamic; intensity of the force (low or high); and, nature of the surface which includes body site, moisture content and the coefficient of friction

region affected and the major predisposing factors such as the occupation of the individuals most commonly affected. This allows for a quick clinical diagnosis and treatment planning. However, it must be noted that the entities may not be specific to the occupation they are grouped under and may be found in patients with other occupations too.

Primary frictional dermatoses

Primary frictional dermatoses include entities where repeated friction is the major etiological factor responsible for development of the lesion. These conditions may be further classified based on the major predisposing factor such as the occupation, cultural or religious practices and the anatomical region affected [Figure 2], as outlined in Table 2.

Secondary frictional dermatoses

This category includes entities where friction plays a contributory role in the pathogenesis; however, its presence alone is not sufficient for development of the lesion. Infection, sweat or other inciting agents and/or a pre-existing dermatoses are prerequisites for the development of this set of conditions.

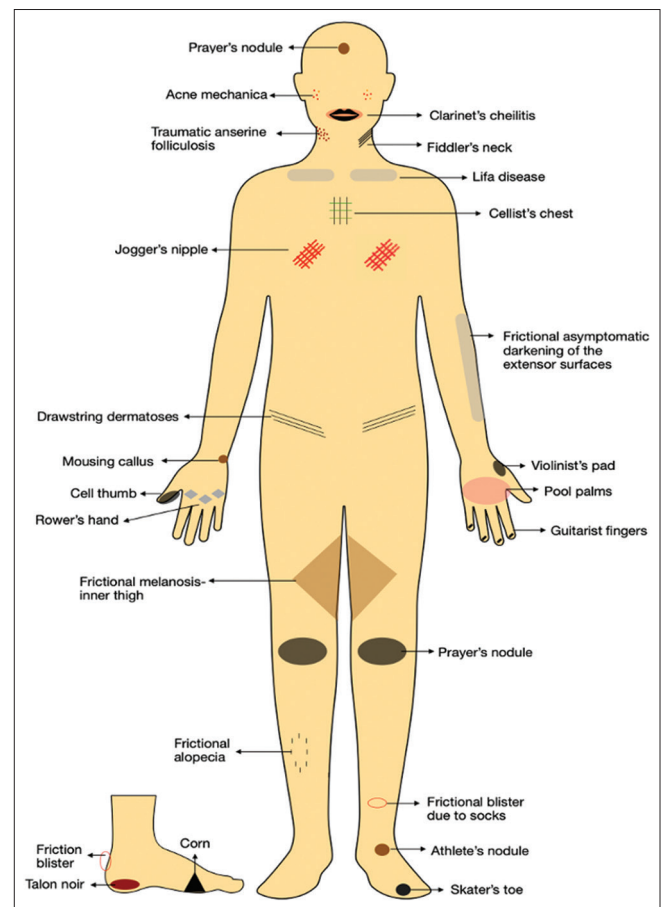


Figure 2: Important frictional dermatoses based on the location. Frictional dermatoses may be classified based on the major predisposing factor such as the occupation, cultural or religious practices and the anatomical region affected

Table 2: Classification of primary frictional dermatoses

Entity	Primary Frictional Dermatoses						
	Anatomical Region						
	Generalised	Head and Neck	Trunk	Limbs	Hair	Mucosa	Nails
1. Occupational							
<i>A. Sports Related</i>	-	-	Joggers nipples ¹⁷	<ul style="list-style-type: none"> Pool palms²¹ Rower’s hands²⁰ Athlete’s nodules¹⁷ Talon noir²² Skater’s toe/toenail²³ Skater’s nodules/pad²³ Skate bite/lace bite²³ Malleolar bursitis²³ Piezogenic pedal papules²² Baseball pitcher’s friction dermatitis⁶ Tylomas²⁰ Pump bumps²³ Hyperkeratosis and frictional dermatitis from practicing kendo²⁴ 	-	-	-
<i>B. Soldiers</i>	-	-	-	<ul style="list-style-type: none"> Friction blisters²⁵ Corns and calluses²⁶ 	-	-	-
<i>C. Musicians</i>	-	<ul style="list-style-type: none"> Fiddler’s neck¹⁶ Clarinetist’s cheilitis²⁷ Flautist’s chin²⁷ Lip Callosity²⁸ 	Cellist’s chest ²⁷	<ul style="list-style-type: none"> Drummer’s digits²⁷ Guitarist’s fingers/Harpist’s fingers²⁷ Garrod’s fingers/Violinist’s pads²⁷ 	-	-	-
<i>D. Computer/ Electronic device-related</i>	-	-	-	<ul style="list-style-type: none"> Cell thumb²⁹ Mousing callus³⁰ Writer’s bump²⁹ 	-	-	-
2. Related to Cultural Practices							
<i>A. Frictional Melanosis</i>	-	Facial frictional melanosis ³¹	<ul style="list-style-type: none"> Davener’s dermatoses³² Lifa disease³³ Orphan rocker tracks³⁴ Frictional Dermatoses due to car seat³⁵ 	<ul style="list-style-type: none"> Frictional asymptomatic-darkening of the extensor surfaces³⁶ Frictional melanosis of rubbing inner thighs³⁷ 	-	-	-
<i>B. Clothing Related</i>	Nylon clothes friction dermatoses ³⁸	-	<ul style="list-style-type: none"> Induced by sari and petticoat drawstrings^{18,39,40} Waist dermatoses—sari³⁹ 	Friction blisters due to socks ¹⁵	Friction alopecia due to socks ^{7,8}	-	-
<i>AC. Religious Practices/ Praying related</i>	-	Prayer’s nodules ^{18,41}	-	<ul style="list-style-type: none"> Prayer’s nodules^{18,41} Pew blisters or ‘prayer blisters’⁴¹ Davener’s dermatitis³² Yoga sign⁴² 	-	-	-
3. Miscellaneous							
-	-	Acne mechanica ⁴³ Folliculitis mechanica ⁴³ Traumatic anserine folliculitis ⁴⁴	-	Amputation stump callosities ⁴⁵	-	<ul style="list-style-type: none"> Frictional keratosis of oral mucosa or benign alveolar ridge keratosis³ Morsicatio buccarum and linguarum⁴ Frictional dermatoses due to sexual practices^{46,47} 	Frictional trauma to nails ¹⁰

Table 3: Clinical features of frictional dermatoses

Disease entity	Morphology	Location	Associated features
1. Frictional Dermatoses in Sportspersons			
Jogger's nipple ¹⁷	Cracked & painful nipple Bleeding±	Nipple	Long distance runners Continuous friction from cotton type T shirts
Pool palm ²¹	Recurrent painful, bilateral erythematous patches.	Finger pads, palms and soles	Swimmers
Rower's hand ^{20,48}	Erythematous patch or blisters	Fingers, back of hand	Rowers
Athlete's nodule ^{17,49} (<i>Skater's nodules, collagenomas, 'Nike nodule' in runners, 'knuckle pad' in boxers</i>)	Soft skin coloured painful/painless keratinised nodule.	Lateral malleoli, lateral sides of feet, overlying the Achilles tendon	Skaters, runners, boxers
Talon noir ^{17,50} <i>Black heel, calcaneal bleed/petechiae</i>	Blue black, linear to oval macule	Posterior or posterolateral aspect of heel	Basketball & tennis players, gymnasts
Skater's toe/nail ²³	Toe tip callus, nail thickening or SUH	Toe tip or toenail	Skaters, Runners, ice hockey players
Skater's nodule ^{23,49} (Double ankle bones)	Collagenoma which presents with hyperkeratotic, smooth surface nodules	Lateral malleoli, lateral sides of feet or skin overlying Achilles tendon	Skaters
Skater's pad ²³	Callus like hyperkeratosis. Superficial than skater's nodule.	Heels	Skaters
Skater's bite ^{23,51,52}	Pain and swelling, radiating pain from lower leg towards toe	Dorsum of foot or near the tongue of the skate	Skaters, ice hockey players
Malleolar bursitis ^{23,53}	Intermittent painful S/C mass. Superimposed infection may occur	Tip of malleolus. Medial malleolus most common.	Skaters
Piezogenic pedal papule ^{23,54,55} [Figure 3]	Asymptomatic papule may be painful	Medial or lateral aspect of heels (visualised better in standing position)	Common in skaters, runners & weightlifters with underlying connective tissue disease, rheumatic heart diseases
Baseball pitcher's friction dermatitis ⁶	Appears as discoid eczema.	Inner ankle, lower knee	Baseball players with endogenous eczema
Tyloma ⁴⁸	Uniform thickening of skin. Pain & bleeding if fissures develop	Pressure bearing areas of foot, palms and fingers.	Athletes
Pump bump ²³	Painful and inflamed bumps	insertion of Achilles tendon	Skaters with: High arched foot Tight Achilles tendons or Walking on outer aspects of heels
Hyperkeratosis and frictional dermatitis due to practicing kendo ²⁴	Asymptomatic hyperkeratotic to eczematous lesion seen a kendo player (a Japanese sport)	Palmoplantar area	Kendo
2. Frictional Dermatoses in Sportspersons			
Corns and Calluses ²⁵ [Figure 4]	Yellow-white hyperkeratotic callosities	Pressure bearing areas	Protective response to constant mechanical stimuli
Friction Blisters ⁶³	Blisters	Palms and soles	Constant stamping action of the feet; shearing force between skin and external surface; separation of epidermis at the level of the stratum corneum.
3. Frictional Dermatoses in Musicians			
a. Head and Neck			
Fiddler's neck ⁵⁶	Eythematous, hyperpigmented, lichenified lesion	Angle of the mandible	Friction at the site where the violin contacts the chin
Clarinetist's cheilitis ⁵⁷	Presents with erythema, scaling and lichenification Fissuring, atrophy and depigmentation may also be seen.	Median part of the vermilion border of the lower lip, chin	Due to the continuous friction, pressure and saliva which collects under lower lip. It is an irritant dermatitis in the area where the wooden reed comes in contact with the skin
Lip callosity ²⁸	Skin coloured or hyperpigmented hyperkeratotic plaque	Mid portion of the lip	Repetitively irritated because of intense contact with parts of the instrument
Flautist's Chin ⁵⁸	Scaly, erythematous plaques	Chin	Friction, pressure and moisture Sweat and saliva at the site of contact ACD to nickel, chromium
b. Trunk			
Cellist's chest ⁵⁹	Presents with xiphoid discomfort and hyperpigmented erythematous plaques	Lower end of the sternum at the xiphoid process	-

(Contd...)

Table 3: (Continued)

Disease entity	Morphology	Location	Associated features
c. Limbs			
Drummer's digits ¹²	Yellow-white hyperkeratotic callosities	Lateral aspect of the left index finger	-
Guitarist's fingers/harpists fingers ^{59,60} [Figure 5]	Paronychia, blisters, calluses Onycholysis, SUH	Sides and tips of the fingers	Harpist who is just starting is most prone to injury as calluses have not yet developed
Garrod's fingers/Violinist's pad ^{12,59}	Thickening of the skin and underlying tissues	Backs of IP joints of the index, middle fingers of left hand	Force is applied to the strings while playing, calluses protective mechanism
Frictional Dermatoses in Writer's and Computer users			
Writer's bump ²⁹	Well circumscribed yellow-white plaque. Slight tenderness on pressure	Lateral aspect of DIP of the middle finger of dominant hand	Constant pressure of tightly gripped pencils and pens while writing
Cell thumb/Playstation thumb ^{29,61}	Well defined, tender calluses	Medial aspect of the thumb	Excess phone gripping, occasionally
Frictional dermatitis due to computer mouse/mouse fingers ⁶²	Sharply demarcated lesions with erythema and scaling	Palmar aspect of first and fifth fingertips	Constant rubbing while using a mouse
Mousing callus ^{30,63}	Painless, yellowish, thickened callus	Palmar aspect of the wrist	Friction and pressure, on the one hand, prolonged use of computer mouse
A. Frictional Melanosis			
a. Face			
Facial frictional melanosis ³¹	Deep dark brown pigmentation	Bony prominences of the face	Aggressive rubbing of the face with hand or handkerchief
b. Trunk			
Lifa disease ³³	Deep dark brown pigmentation	Clavicles, shins, upper back and lateral aspect of the arms	Repeated rubbing by lifa (brush for washing)
Orphan Rocker Tracks ³⁴	Frictional dermatoses resembling train tracks	Bony prominences of the lumbosacral spine	Children with autistic behaviour, habitual of rocking movements
Frictional dermatoses due to car seat ³⁵	Linear hyperpigmented patches	Bony prominences on the back	Prolonged periods of sitting and driving
c. Limbs			
Frictional asymptomatic darkening of extensor surfaces ^{36,64}	Asymptomatic darkening overlying sites of friction, 'sign of dirty knees and elbows.'	Extensor surfaces of elbows and knees	Increased frictional rubbing
Frictional melanosis of inner thighs ³⁷	Asymptomatic darkening.	Inner thighs	Frictional stress – rubbing of thighs; obese females
B. Clothing related			
a. Generalised			
Nylon cloth frictional dermatoses ³⁸	Dark brown pigmentation	Bony prominences: clavicle, back, shoulders, ribs, spinous processes, extensors (limbs)	Reported in Japan – practice of rubbing body with wet or dry nylon cloth or scrub brushes
b. Limbs			
Frictional dermatoses due to socks ⁷	Dark brown pigmentation	Just below the knees or above the ankles up to mid-calf.	Repeated wearing of tight socks/knee length boots
c. Trunk			
Dermatoses due to sari, petticoat, salwar drawstrings ³⁹	Post inflammatory hyperpigmentation or hypopigmentation	Waist	Sari, petticoat/salwar tied to the waist via a drawstring, pressure and friction and formation of an artificial groove
C. Religious Practices/Praying related			
a. Face and Limbs			
Prayer Nodules ¹⁸ [Figure 6]	Nodules or calluses	Forehead, knees, ankles and dorsa of feet.	Squatting position—knees and ankles held against the floor, weight on the lower legs during prayers; touching forehead on the ground during prayer by Muslims.
Pew Blisters ⁴¹	Frictional blister	One or both knees	Repeated kneeling on pews in church
Davener's dermatitis ³²	Hyperpigmented ill-defined areas	Lower spinous processes	Exclusively in Jewish Israeli Yeshiva students, constant rocking of the upper body sitting on a firm wooden or metal chair with a rigid backrest during praying
Yoga sign ⁴²	Hyperkeratotic, circumscribed, hyperpigmented plaques Patients suffering of neuropathy may ulceration of the callosities	Outer ankles and fifth toes	The characteristic Yoga sitting position on plain and hard floor exerts mechanical stress, that is, repeated and prolonged pressure and shear forces Yoga sign is also seen in people who sit 'cross legged'

SUH: Subungual hyperkeratoses, IP: Interphalangeal, DIP: Distal interphalangeal

Table 4: Miscellaneous frictional dermatoses

Entity	Etiopathogenesis	Clinical feature	Diagnosis	Treatment
Face				
Acne mechanica ⁴³	<ul style="list-style-type: none"> Localised acne form eruptions due a combination of friction, pressure and occlusion. Sweating causes keratin hydration and decreased size of the pilosebaceous exit duct, leading to sebum accumulation, creating a favourable condition for bacterial colonisation and inflammation 	<ul style="list-style-type: none"> Comedones, inflammatory papules and pustules; cysts and nodules in severe cases Common in sports persons wearing occlusive protective gear and patients using medical devices such as a prosthesis or crutches 	<ul style="list-style-type: none"> Clinical Allergic contact dermatitis due to substances in the occlusive covering must be ruled out 	<ul style="list-style-type: none"> Removal of the inciting factor Benzoyl peroxide, topical retinoids, keratolytics Topical or systemic antibiotics where necessary²²
Traumatic anserine folliculosis ⁴⁴ [Figure 7]	<ul style="list-style-type: none"> Resting or supporting the head in a particular position leading to repeated friction at the site 	<ul style="list-style-type: none"> Multiple, closely-set, grouped follicular papules ('anserine' or goose-like appearance), usually on the chin, jaws or neck 	<ul style="list-style-type: none"> Clinical HPE: hyperkeratosis, hypergranulosis, focal presence or increase of stratum lucidum, rudimentary follicles and dilated follicular opening with retained keratotic material. Mild perivascular inflammatory infiltrate is occasionally seen 	<ul style="list-style-type: none"> Removal of inciting factor
Acanthoma fissuratum (misnomer: Granuloma fissuratum) ⁶⁵ [Figure 8]	<ul style="list-style-type: none"> Chronic persistent trauma due to ill-fitting spectacle frame or heavy glasses (spectacle frame granuloma) Abnormal anatomy and pre-existing skin disease (atopy, vulvar dermatoses, vaginal candidiasis) may contribute Ill-fitting dentures, tight-fitting underwear, hearing aid, have been implicated at other sites 	<ul style="list-style-type: none"> Pruritic or asymptomatic Usually unilateral; firm, folded coin-shaped lesion, flesh-coloured papule, nodule, or plaque with a central groove dividing the lesion into two halves (coffee bean appearance) Sites: <ul style="list-style-type: none"> Retroauricular and superior auricular sulci, bridge of nose (spectacle frame) Labio-alveolar sulcus (ill-fitting dentures) External auditory canal (in-the-canal hearing aids) Shaft of penis (tight underwear) Posterior fourchette of vulva, usually associated with co-existing disease Dyspareunia is common 	<ul style="list-style-type: none"> Clinical: The site correlates with points on the skin/mucosa where the spectacle frame or denture persistently rests or apposes Biopsy may be performed as lesion may simulate BCC HPE: Hyperkeratosis, variable parakeratosis, acanthosis, spongiosis (occasional). Epidermis shows central attenuation corresponding to the longitudinal groove. May be filled with inflammatory cells and keratinous debris. Dermis may show chronic inflammation. Granuloma is absent 	<ul style="list-style-type: none"> Removal of the inciting agent Surgical excision, intralesional corticosteroids, electrosurgery. Treatment of co-existing condition, especially vulval disease which co-exists with lichen sclerosus, or vulvo-vaginal candidiasis⁶⁶ Perineoplasty may be required for persistent vulval granuloma fissuratum due to dyspareunia and recurrent fissuring⁶⁶
Limbs				
Frictional dermatoses in amputees ⁴⁵	<ul style="list-style-type: none"> Poorly fitting prostheses 	<ul style="list-style-type: none"> Follicular hyperkeratosis due to friction, usually at weight-bearing sites in the popliteal fossa, inguinal region and distal stump Callus formation and lichenification may also occur 	<ul style="list-style-type: none"> Clinical 	<ul style="list-style-type: none"> Adjustment of prosthesis Topical keratolytics
Frictional dermatoses in oral mucosa				
Benign alveolar ridge keratosis ³	<ul style="list-style-type: none"> Chronic frictional trauma due to mastication 	<ul style="list-style-type: none"> White papule or plaque on the keratinised mucosa of the retromolar pad, or edentulous maxillary or mandibular alveolar ridge Males more commonly affected Prevalence highest in the fifth to seventh decades 	<ul style="list-style-type: none"> Clinical HPE: moderate to marked hyperkeratosis, mild surface papillomatosis, acanthosis with wedge shaped hypergranulosis. Focal parakeratosis may be present and basal layer is intact with insignificant mitotic activity and very mild reactive atypia 	<ul style="list-style-type: none"> No intervention required
Morsicatio buccarum and linguarum ⁴	<ul style="list-style-type: none"> Repetitive habit of rubbing, chewing or sucking of the oral mucosa against teeth leads to frictional keratosis of the buccal mucosa (morsicatio buccarum), tongue mucosa (morsicatio linguarum) and lip. 	<ul style="list-style-type: none"> Ill-defined areas of grey to white papules and plaques, often bilateral. The surface is rough with irregular tags, which results in a cycle of the patient biting the mucosa to remove the rough tags, producing more tags in turn. Erosions and ulcers may be present if the bite trauma is extensive. 	<ul style="list-style-type: none"> HPE: Marked hyperkeratosis and parakeratosis with shaggy or shredded keratin on the surface. Ballooned cells may be seen in the spinous layer. Dysplasia is absent 	<ul style="list-style-type: none"> Reassurance No intervention required
Frictional dermatoses of genitalia due to sexual practices				
Frictional trauma to nails ¹⁰	<ul style="list-style-type: none"> Repeated abrasion or friction on nail plate Habitual nail picking (Onychotillomania) 	<ul style="list-style-type: none"> Polishing of the nails, causing them to have a shiny appearance Central ridge deformity Various degrees of nail dystrophy 	<ul style="list-style-type: none"> Clinical 	<ul style="list-style-type: none"> Modification of behaviour Use of protective equipment

(Contd...)

Table 4: (Continued)

Entity	Etiopathogenesis	Clinical feature	Diagnosis	Treatment
Frictional dermatoses of genitalia due to sexual practices				
Penile coital injury ⁴⁶	<ul style="list-style-type: none"> Sexual intercourse Risk is greater with increasing age, multiple sexual partners, application of substances (creams, lotions or lubricants) on the penis or vagina. The risk is reduced in circumcised men and with use of condom 	<ul style="list-style-type: none"> Abrasions, cuts and scratches common in young men increases the risk of acquisition of HIV and other STIs, due to disruption of the epithelial barrier 	<ul style="list-style-type: none"> Clinical 	<ul style="list-style-type: none"> Use of condom
Frictional dermatitis of Onan ⁴⁷	<ul style="list-style-type: none"> Excessive masturbation 	<ul style="list-style-type: none"> Pruritic eruption on the penis. Subacute to chronic eczema and in more chronic cases, lichenification and hyperpigmentation is noted on the penile corona or the shaft, sometimes in linear distribution 	<ul style="list-style-type: none"> Clinical History of appearance of lesions following periods of increased masturbation 	<ul style="list-style-type: none"> Emollients

HPE: Histopathological evaluation, BCC: Basal cell carcinoma

Table 5: Secondary frictional dermatoses

Secondary frictional dermatoses	Etiopathogenesis	Clinical features	Diagnosis	Treatment
Sweat dermatitis/ Frictional sweat dermatitis ^{5,67}	<ul style="list-style-type: none"> Chronic cumulative irritant dermatitis to sweat solutes Controversial role of occlusion and friction 	<ul style="list-style-type: none"> Glazed sharply demarcated erythematous plaques localised to sites of friction Can vary from hyperpigmented 'parchment-like' skin to miliaria and maculopapular rash Burning and stinging All ages 	<ul style="list-style-type: none"> Clinical Dermoscopy: variable findings as per clinical morphology HPE: Mild spongiform dermatitis 	<ul style="list-style-type: none"> Avoidance of hot and humid conditions No specific treatment necessary Subsides spontaneously without sequelae in around two weeks
Diaper dermatitis ⁶⁸	<ul style="list-style-type: none"> Repeated contamination of skin by irritant faeces with active enzymes in addition to friction and excessive hydration Thinner epidermis and stratum corneum and immature barrier function in infants 	<ul style="list-style-type: none"> Painful, well-defined erythematous macules+papules, pustules or erosions on areas in contact with diaper including buttocks, genitals, inner thighs and waistline Sparing of inguinal folds Infants and elderly 	<ul style="list-style-type: none"> Clinical KOH to rule out fungal infection HPE: Mild spongiform dermatitis 	<ul style="list-style-type: none"> Frequent diaper changes Aeration of skin Use of water with gentle cleanser for cleaning followed by application of petrolatum or zinc oxide-based barrier cream Low-potency topical corticosteroids with or without antifungals if non-responsive
Juvenile plantar dermatoses/ ³ sweating sock dermatitis ⁶⁹	<ul style="list-style-type: none"> Sweating and friction in conditions of occlusion (prolonged wearing of shoes and socks without aeration) Atopic diathesis 	<ul style="list-style-type: none"> Erythematous, glazed and fissured plaques on plantar surface of forefoot, associated with soreness Spare web spaces and dorsae Young children 	<ul style="list-style-type: none"> Clinical KOH to rule out fungal infection HPE: Subacute or chronic spongiotic dermatitis with peri-ecrine lymphocytic infiltrate 	<ul style="list-style-type: none"> Self-limiting, resolves spontaneously in a few years Wear open sandals Emollients and topical corticosteroids
Frictional lichenoid dermatitis/ Dermatitis papulose adultorum/ Sutton's summertime prurigo ⁷⁰ [Figure 9] Frictional dermatitis ⁷¹	<ul style="list-style-type: none"> UV radiation Friction Atopy 	<ul style="list-style-type: none"> Grouped lichenoid papules over elbows and knees Asymptomatic or pruritic Spring and summer Young children 	<ul style="list-style-type: none"> Clinical HPE: Non-specific. Hyperkeratosis, acanthosis with or without mild spongiosis and perivascular lymphocytic infiltrate 	<ul style="list-style-type: none"> Self-limiting Emollients and mild topical corticosteroids
Frictional amyloidosis/ □Brush' amyloidosis ⁷²	<ul style="list-style-type: none"> Eczematous process triggered by chronic friction Occupational handling of tools, papers, plastic etc. Co-existence of contact allergy, atopic dermatitis or psoriasis Chronic scratching or rubbing 	<ul style="list-style-type: none"> Dryness and hyperkeratosis on the palm of the dominant hand as well as the sides and tips of fingers Can evolve to painful psoriasiform plaques with or without vesicles and/or fissuring Rippled hyperpigmentation over areas of chronic scratching or rubbing Can be pruritic Commonly on the upper back or lower limbs 	<ul style="list-style-type: none"> Clinical Studies on HPE not available, likely spongiotic dermatitis Clinical HPE: Hyperkeratosis and acanthosis of epidermis, deposition of amyloid in papillary dermis (pale, homogeneous eosinophilic material with fissures) 	<ul style="list-style-type: none"> Removal of precipitating factor (friction) or use of protective equipment Emollients, humectants and keratolytics Topical corticosteroids Grenz ray therapy Avoid scratching Emollients, topical mid-potent corticosteroids, DMSO Ablative lasers

DMSO: Dimethyl sulfoxide, HPE: Histopathological evaluation, KOH: Potassium hydroxide

Table 6a: Differential diagnosis of frictional dermatoses – head and neck, trunk

Entity	Differentials		
	Differentials	Differentiating Features	Investigations
Head and neck			
Facial frictional melanosis ^{30,73}	<ul style="list-style-type: none"> • Melasma 	<ul style="list-style-type: none"> • Bilaterally symmetrical diffuse light-brown to dark-brown areas of pigmentation on the central face, forehead, chin • May be associated with OCPs, pregnancy, sunlight exposure 	<p>Histopathology</p> <ul style="list-style-type: none"> • Epidermal form: melanin deposition mainly in the basal and suprabasal layers and the melanocytes are highly dendritic and full of pigment. • Dermal form: less prominent epidermal pigment with superficial and deep dermal perivascular melanophages and free melanin deposits <p>Dermoscopy</p> <ul style="list-style-type: none"> • Reticular/pseudo-reticular pattern with perifollicular sparing
	<ul style="list-style-type: none"> • Facial macular amyloidosis 	<ul style="list-style-type: none"> • Rippled salt-and-pepper appearance with alternating hyperpigmentation and hypopigmentation • Pruritus 	<p>Histopathology:</p> <ul style="list-style-type: none"> • Amyloid deposits in the papillary dermis • Melanin containing histiocytes encircle the deposits
	<ul style="list-style-type: none"> • Facial acanthosis nigricans 	<ul style="list-style-type: none"> • Thickened hyperpigmented with velvety texture • Metabolic syndrome and insulin resistance 	<p>Histopathology</p> <ul style="list-style-type: none"> • Hyperkeratosis • Papillomatosis • Irregular acanthosis <p>Dermoscopy:</p> <ul style="list-style-type: none"> • Linear crista cutis with sulcus cutis with focal hyperpigmented dots in crista cutis
	<ul style="list-style-type: none"> • Lichen planus pigmentosus 	<ul style="list-style-type: none"> • Symmetrical brown to gray-brown poorly demarcated macules and patches • Photoexposed sites • Pruritus 	<p>Histopathology</p> <ul style="list-style-type: none"> • Lichenoid infiltrate • Effacement of rete ridges resulting in epidermal atrophy
	<ul style="list-style-type: none"> • Pigmented contact dermatitis 	<ul style="list-style-type: none"> • Rapid onset and localised • Reticular grey-brown to almost black reticulate hyperpigmentation. • Favours site of application of irritants/cosmetics 	<p>Histopathology</p> <ul style="list-style-type: none"> • Liquefactive degeneration of the basal layer of the epidermis, • Pigment incontinence in the dermis. • Patch testing – positive for offending drug
	<ul style="list-style-type: none"> • Post-inflammatory hyperpigmentation 	<ul style="list-style-type: none"> • Prior history of inflammation/primary dermatoses 	<p>Histopathology</p> <ul style="list-style-type: none"> • Accumulation of melanophages and increased melanin in epidermal layers. • Pigment incontinence
	<ul style="list-style-type: none"> • Sebomelanosis⁷⁴ 	<ul style="list-style-type: none"> • Localised darkening in the seborrheic distribution • Erythema, scaling, dyssebacia, mild burning, pruritus 	-
	<ul style="list-style-type: none"> • Pigmentary demarcation lines 	<ul style="list-style-type: none"> • Clear linear demarcation between light and dark skin • Seen along embryonic suture lines • Childhood/pubertal onset 	<p>Dermoscopy:^{75,76}</p> <ul style="list-style-type: none"> • Clear borders of abrupt transition from light to dark • Exaggerated pseudo-network
Fiddler's neck ¹⁶	<ul style="list-style-type: none"> • Allergic Contact dermatitis (nickle, PPD, colophony) • Salivary gland malignancy 	<ul style="list-style-type: none"> • Erythema • Oedema • Pruritus • Oozing • Vesiculation • Palpable and enlarged salivary gland • Palpable regional lymph nodes 	<p>Histopathology</p> <ul style="list-style-type: none"> • Spongiosis • Dermal oedema, lymphocyte, eosinophils, mast cells, basophil infiltration • Patch test – positive for the offending allergen <p>Local Ultrasound</p> <ul style="list-style-type: none"> • Biopsy
Traumatic anserine folliculosis ⁴⁴	<ul style="list-style-type: none"> • Keratosis pilaris • Lichen spinulosus 	<ul style="list-style-type: none"> • Ill-defined relatively larger areas containing small (typically 1-mm), keratotic, follicular papules with varying degrees of perifollicular erythema. • Antennae sign • Round to oval groups of keratotic spiny papules • Most commonly children 	<p>Histopathology</p> <ul style="list-style-type: none"> • Hyperkeratosis, Follicular plugging, Hypergranulosis <p>Dermoscopy: thin, short hair shafts that are coiled or twisted within the follicular ostia</p> <p>Histopathology</p> <ul style="list-style-type: none"> • Hyperkeratosis dilated hair follicle with keratotic plugging

(Contd...)

Table 6a: (Continued)

Entity	Differentials		
	Differentials	Differentiating Features	Investigations
	<ul style="list-style-type: none"> • Trichostasis spinulosa 	<ul style="list-style-type: none"> • Comedo-like lesions composed of keratin and vellus hair; middle to lower central face affected 	Histopathology <ul style="list-style-type: none"> • Retention of small hair shafts within a dilated infundibulum, sometimes enveloped in a keratinous sheath
	<ul style="list-style-type: none"> • Trichodysplasia spinulosa 	<ul style="list-style-type: none"> • Shiny follicular eruptions on the central face associated with immune suppression 	Histopathology <ul style="list-style-type: none"> • Abnormal anagen follicles with excessive inner root sheath differentiation
Clarinetist's cheilitis ¹²	<ul style="list-style-type: none"> • Contact dermatitis (cane reed) 	<ul style="list-style-type: none"> • Erythema, oedema, pruritus, oozing, vesiculation, fissures, erosions 	<ul style="list-style-type: none"> • Patch test – positive
Trunk			
Frictional melanosis ⁷⁷	<ul style="list-style-type: none"> • Macular amyloidosis 	<ul style="list-style-type: none"> • Rippled salt-and-pepper appearance with alternating hyperpigmentation and hypopigmentation • Pruritus 	Histopathology <ul style="list-style-type: none"> • Amyloid deposits in the papillary dermis • Melanin containing histiocytes encircle the deposits
Jogger's nipple ¹⁷	<ul style="list-style-type: none"> • Contact dermatitis (disperse dyes, formaldehyde textile resins, fragrances) • Paget's disease 	<ul style="list-style-type: none"> • Erythema, oedema, pruritus, oozing, vesiculation <p>Long standing erythematous, scaly, or velvety patches or plaques over the nipple Usually unilateral</p> <ul style="list-style-type: none"> • Pruritus <p>Serosanguinous discharge</p> <ul style="list-style-type: none"> • Underlying intraepithelial breast carcinoma 	<ul style="list-style-type: none"> • Patch test – positive <p>Punch, wedge, or excisional biopsy</p> Histopathology <ul style="list-style-type: none"> • Acanthosis, hyperkeratosis and parakeratosis are often present • Paget cells have distinctive pale-staining cytoplasm and are usually randomly dispersed throughout the epidermis
	<ul style="list-style-type: none"> • Nipple eczema 	<ul style="list-style-type: none"> • Usually bilateral, pruritus, erythema, crusting, serous discharge • More common among lactating mothers 	-
Cellist's chest ¹²	<ul style="list-style-type: none"> • Contact dermatitis to nickel, colophony 	<ul style="list-style-type: none"> • Erythema, oedema, pruritus, oozing, vesiculation 	<ul style="list-style-type: none"> • Patch testing – positive
Davener's and lifa ^{32,33}	<ul style="list-style-type: none"> • Acanthosis nigricans 	<ul style="list-style-type: none"> • Thickened hyperpigmented with velvety texture • Metabolic syndrome and insulin resistance 	Histopathology <ul style="list-style-type: none"> • Hyperkeratosis • Papillomatosis • Irregular acanthosis Dermoscopy: ³¹ <ul style="list-style-type: none"> • Linear crista cutis with sulcus cutis with focal hyperpigmented dots in crista cutis

OCPs: Oral Contraceptive Pills

Table 6b: Differential diagnosis of frictional dermatoses – extremities and mucosa

Entity	Differentials	Differentiating Features	Investigations
Extremities			
Frictional melanosis of inner thigh ³⁷	<ul style="list-style-type: none"> • Acanthosis nigricans 	<ul style="list-style-type: none"> • Thickened hyperpigmented with velvety texture • Metabolic syndrome and insulin resistance 	Histopathology <ul style="list-style-type: none"> • Hyperkeratosis • Papillomatosis • Irregular acanthosis Dermoscopy: ³¹ <ul style="list-style-type: none"> • Linear crista cutis with sulcus cutis with focal hyperpigmented dots in crista cutis
Frictional asymptomatic darkening of extensor surfaces ³⁶	<ul style="list-style-type: none"> • Lichen simplex chronicus • Macular amyloidosis 	<ul style="list-style-type: none"> • Lichenified, dry and scaly plaque, hyper/hypopigmentation • Excoriation marks • Itching • History of habitual rubbing/scratching of the areas <ul style="list-style-type: none"> • Rippled salt-and-pepper appearance with alternating hyperpigmentation and hypopigmentation • Itching 	Histopathology <ul style="list-style-type: none"> • Pseudoepitheliomatous hyperplasia • Hyperkeratosis • Hypergranulosis • Elongated rete ridges • Dermal papillary fibrosis Histopathology <ul style="list-style-type: none"> • Amyloid deposits in the papillary dermis • Melanin containing histiocytes encircle the deposits

(Contd...)

Table 6b: Differential diagnosis of frictional dermatoses – extremities and mucosa

Entity	Differentials	Differentiating Features	Investigations
Amputation stump callosities ⁴⁵	<ul style="list-style-type: none"> Contact dermatitis (PPD, formaldehyde, epoxy resin, mercaptomix) Exacerbation of previous dermatitis (psoriasis) 	<ul style="list-style-type: none"> Erythema, oedema, pruritus, oozing, vesiculation Well demarcated erythematous plaques with silvery white scales Grattage and Auspitz sign positive Similar lesions elsewhere on the body Past history of psoriasis Nail and joint involvement 	<ul style="list-style-type: none"> Patch test – positive Histopathology <ul style="list-style-type: none"> Hyperkeratosis Parakeratosis Micromunro abscess Spongiform pustule of Kogoj Regular acanthosis Suprapapillary thinning Capillary dilatation in the papillary dermis Lymphocytic infiltration in the dermis
Socks alopecia ⁸	<ul style="list-style-type: none"> Arterial insufficiency Scleroderma Lipodermatosclerosis Waxing, shaving, laser removal 	<ul style="list-style-type: none"> Cyanosis/palor Cool extremities Discolouration of skin/ulceration/gangrene Feeble pulses Claudication Malformed and discoloured nails Smoking history Raynaud's phenomenon Skin tightening/restricted mouth opening Pitting scars over the finger tips Breathlessness Telangiectasias Skin is firm and indurated and bound down circumferentially giving champagne bottle appearance Nocturnal leg cramps Edema of lower limb History of varicose veins/DVT History of procedures 	<ul style="list-style-type: none"> USG doppler Ankle brachial pressure index Scleroderma specific antibodies Abnormal nail fold capillaries Histopathology <ul style="list-style-type: none"> Acute changes – sparse septal lymphohistiocytic infiltrates and foci of ischemic fat necrosis or hyalinisation of the lobules Late changes— <ul style="list-style-type: none"> Epidermis: melanin increased Dermis: lobules of small slightly thick walled vessels in concert with extravasated erythrocytes and hemosiderin lobular architecture disrupted
Mouse fingers ⁶²	<ul style="list-style-type: none"> Palmoplantar psoriasis Hand eczema 	<ul style="list-style-type: none"> Well defined bilaterally symmetrical erythematous plaques with scaling and fissuring with or without pustules over palms and soles, involving the dorsum of hand and foot Pruritus Pain Aggravation in winters and on soaking with water Pruritus Vesicular dermatitis over palmar and dorsal aspect Nail involvement Aggravation on contact with water/ household work Exposure to chemicals 	<ul style="list-style-type: none"> Histopathology <ul style="list-style-type: none"> Hyperkeratosis Parakeratosis Micromunro abscess Spongiform pustule of kogoj Regular acanthosis Suprapapillary thinning Capillary dilatation in the papillary dermis Lymphocytic infiltration in the dermis Patch test – positive
Corns and callosities, tylomas ^{22,23,56}	<ul style="list-style-type: none"> Warts 	<ul style="list-style-type: none"> Pain on lateral pressure Paring reveals pinpoint bleeding 	<ul style="list-style-type: none"> Histopathology <ul style="list-style-type: none"> Hyperkeratosis Parakeratosis Koilocytes Dilated capillaries
Black heel/ haemorrhagic hyperkeratosis and calcaneal petechiae ^{22,23,56}	<ul style="list-style-type: none"> Warts 	<ul style="list-style-type: none"> Pain on compressing side Paring reveals pinpoint bleeding 	<ul style="list-style-type: none"> Histopathology <ul style="list-style-type: none"> Hyperkeratosis Parakeratosis Koilocytes Dilated capillaries

(Contd...)

Table 6b: (Continued)

Entity	Differentials	Differentiating Features	Investigations
	• Acral lentiginous melanoma	• Asymptomatic • Ulceration± • Regional lymph node enlargement	Histopathology • Atypical melanocytes • Disruption of basement membrane Dermoscopy: ⁹¹ • Parallel ridge pattern • >7 mm • Asymmetrical lesions
Pool palms ^{21,48}	• Contact dermatitis	- Erythema, oedema, pruritus, oozing, vesiculation	• Patch test – positive
Skater's nodules/ Athlete's nodules ²³	• Hypertrophic scars	• Previous history of incision/trauma • Raised pink-red coloured firm papules/nodules within the boundary of the incision • Painful/pruritic	Histopathology • Increased collagen fibres arranged parallel to dermis • Increased myofibroblasts and type III collagen
	• Warts	• Pain on lateral pressure • Paring reveals pinpoint bleeding	Histopathology • Hyperkeratosis • Parakeratosis • Koilocytes • Papillomatosis • Dilated capillaries
Skater's toenail ²³	• Onychomycosis	• Subungual hyperkeratosis • Onycholysis • Discolouration	• Hyphae on KOH nail clipping and histopathology • Fungal culture positive
	• Subungual malignant melanoma ⁹¹	• Brown black discolouration of the nail bed • Thickening, splitting, destruction of the nail • Pain/inflammation may be present • Hutchinson's sign positive	Histopathology • Increased pleomorphic melanocytes with atypia in the basal layer • Multinucleation, atypia, extensive pagetoid spread of melanocytes
Piezogenic pedal papules ²³	• Juvenile aponeurotic fibroma	• Fixed, solitary, firm subcutaneous nodule • Does not disappear on standing up • Can calcify • More common in wrists	Histopathology • Fibroblastic tumour Tumour cells are elongated with scant pink cytoplasm and vesicular nuclei and very rare mitotic figures ²⁷
Writer's bump ²⁹ Prayer's nodule ¹⁸ Drummer's digit ¹² Cell thumb ²⁹ Guitarist's finger ^{59,60}	• Callus	• Paring of a corn reveals a central translucent whitish yellow core Exaggerated dermatoglyphics	-
Mucosa Frictional keratosis/ Benign alveolar ridge hyperkeratosis ⁴ Morsicatio buccorum and linguarum/libea alba ⁴	• Leukoplakia	• Homogeneous white patch or plaque that cannot be characterised clinically or pathologically as any other disease • Tobacco, alcohol consumption • No history of • Premalignant condition	Histopathology • Hyperkeratosis • Epithelial dysplasia
	• Leukoedema	• Bilateral buccal and labial mucosa and appears as an opalescent, filmy grey to white lesion that characteristically diminishes upon stretching of the mucosa	Histopathology • suprabasal epithelial cells show marked intracellular oedema
	• Hyperplastic candidiasis	• Persistent erythematous plaques with overlying white deposits • May be associated immunosuppression • May have angular cheilitis	• KOH scraping – positive
	• Oral hairy leukoplakia	• Thick adherent white plaques which cannot be scraped off • EBV associated • Mostly in immunocompromised	Histopathology • Irregular epithelial hyperplasia • Parakeratosis • Acanthosis • Ballooning of keratinocytes with ground glass cytoplasm

(Contd...)

Table 6b: (Continued)

Entity	Differentials	Differentiating Features	Investigations
Frictional dermatitis of Onan ⁴⁷	• Allergic contact dermatitis	Erythema, oedema, pruritus, oozing, vesiculation	Patch test – positive
	• Irritant contact dermatitis	<ul style="list-style-type: none"> • Immediate onset • Burning pruritus • Erosions 	-
	• Candidal balanoposthitis	<ul style="list-style-type: none"> • Erythema, oedema of the glans • White deposits on the glans • Itching • Dysuria • Phimosis in severe cases • History of diabetes mellitus • Similar history in the partner 	KOH-pseudo hyphae Fungal culture – positive
	• Psoriasis	<ul style="list-style-type: none"> • Erythematous scaly plaque • Psoriatic lesions elsewhere on the body 	Skin biopsy consistent with psoriasis
	• Balanitis xerotica	<ul style="list-style-type: none"> • Hypopigmentation • Pruritus • Dysuria • Epidermal thinning/atrophy • Phimosis ± 	Histopathology <ul style="list-style-type: none"> • Epidermal atrophy • Flattened rete ridges • Lichenoid infiltration

PPD: Paraphenylenediamine, USG: Ultrasonography, DVT: Deep vein thrombosis, KOH: Potassium hydroxide, EBV: Epstein-Barr virus

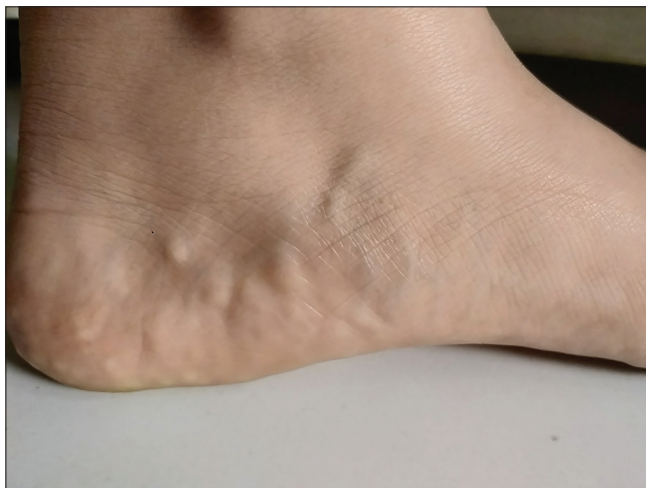

Figure 3: Piezogenic pedal papules-associated with figure skaters, runners and weightlifters, due to the high-impact surface collisions which cause herniation of subcutaneous fat into the dermis. Patients generally present with asymptomatic papules over the medial and lateral aspect of heels



Figure 4: Callosities: Yellowish, hyperpigmented hyperkeratotic callosities present on the palm and proximal digits in a sports person

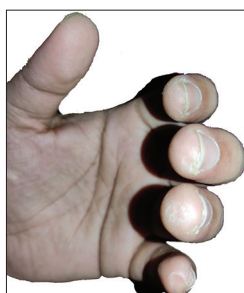

Figure 5: Guitarist’s fingers: These present as calluses at the sides and tips of the fingers

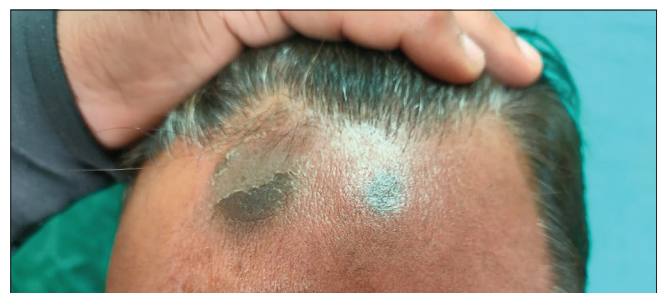

Figure 6: Prayer’s nodules: The religious practice of squatting and touching the forehead repeatedly on the ground during prayer by Muslims, leads to formation of nodules or calluses on the forehead

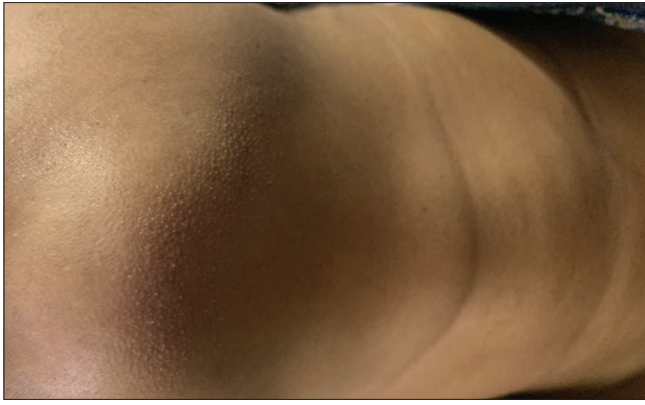

Figure 7: Traumatic anserine folliculitis: Characterised by multiple, closely-set, grouped follicular papules ('anserine' or goose-like appearance), usually on the chin, jaws or neck in children or adolescents, often with a history of resting or supporting the head in a particular position leading to repeated friction at the site

Clinical Features [Table 3]

Primary

Occupational

Frictional dermatoses in sportspersons

Sports entail exposure to several factors such as trauma, prolonged sun exposure, infections and friction, thus increasing the propensity of a variety of skin problems amongst sportspersons. Frictional dermatoses are among the most common cutaneous manifestations in this group.^{6,17,2-24,50-56}

Frictional dermatoses in soldiers

Friction-related skin injuries constitute one of the commonest dermatological conditions reported in military recruits and clinically present as corns, calluses or friction blisters localised to the pressure-bearing sites.^{25,26,50}

Frictional dermatoses amongst musicians

Musicians are particularly predisposed to develop frictional dermatoses, which typically present at the site of contact with the musical instrument.^{16,27,58-60}

Computer/electronic devices related frictional dermatoses

This category of frictional dermatoses has emerged in the past few decades due to the rampant use of computer electronics. The manifestations predominate on the users' hands and fingers.^{29,30,61-63}

Related to cultural practices

Indigenous cultural practices, religious customs and type of clothing also play a key role in causation of a friction related skin diseases and are especially relevant in the Indian setting.^{7,8,15,18,31-44,64}

Miscellaneous

Certain clinically distinct frictional dermatoses are not specific to any category. Such entities, as well as those that manifest in the mucosa and nails, have been included here [Table 4].^{3,4,10,45-49,65,66}

Secondary frictional dermatoses [Table 5]

As we have already elucidated, entities traditionally classified as primary 'frictional dermatoses' are those caused due to the rubbing of one body against another, termed as dry friction. However, friction may be contributory to dermatoses wherein factors such as sweat, moisture or a pre-existing skin disease play a larger role. Friction also plays a pivotal role in many contact dermatoses, by disrupting the stratum corneum barrier.^{19,67-70,72-77}

Differential Diagnosis

Careful history is of paramount importance in diagnosing frictional dermatoses and differentiating it from other clinically similar skin conditions. Differentials vary based on the location of the lesions, that is, skin, mucosa, hair and nail [Tables 6a and 6b].

Diagnosis

The diagnosis of frictional dermatoses is based on a thorough history as well as complete physical examination of the patient. Examination must focus on the type, morphology, distribution and location of lesions. The pattern of involvement provides valuable clues to the probable sources of friction such as sports equipment, musical instruments and cultural practices. The morphology helps establish the cause as well as duration of the insult. Non-invasive modalities such as dermoscopy are a useful diagnostic aid [Figure 10a].^{5,7,31,78-81} In addition, patch and photo patch testing may be helpful to rule out contact dermatitis, an important differential. Diagnostic dilemma and differentiation from clinical mimics may warrant a skin biopsy [Figure 10b]. Most of the entities are characterised by lichenification and show hyperkeratosis, acanthosis and elongation of rete ridges. Hypergranulosis accompanying these features is seen in callus or nodule formation.^{22,23} Conditions presenting with folliculitis including traumatic anserine folliculitis and acne mechanica reveal dilated follicular infundibulum filled with keratin along with a mild perivascular infiltrate. Foreign-body reaction, with abscess, cyst and granuloma formation can be seen in Fiddler's neck.^{16,41,43} Hyperpigmentation as seen in frictional melanosis, Lifa disease or Davener's dermatitis correlates histologically with increased basal layer pigmentation and pigment incontinence.³¹⁻³³ Friction blisters are characterised by an intraepidermal split without inflammation while eczematous lesions show oedema with intraepidermal neutrophilic and mononuclear infiltrate.^{25,57,71}

Treatment

The principles of treatment include providing symptomatic relief, determining the mechanical aetiology and treating the lesion and preventing further recurrence. Various pressure relieving devices (e.g., footwear with cushioned insoles and silicon sheets lubricants and barrier creams) are effective tools to protect stratum corneum.⁸² The main treatment aims at the removal of triggering habits or contact with external causative agent. Topical agents such as keratolytics and humectants help

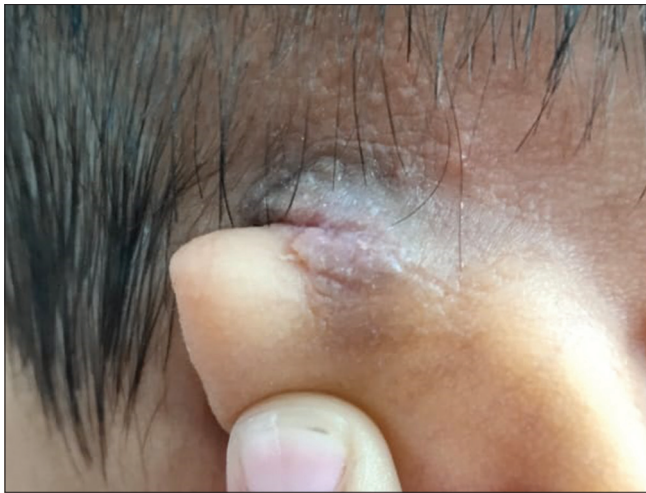

Figure 8: Acanthoma fissuratum: Pruritic or asymptomatic unilateral; firm, folded coin-shaped lesion, flesh-coloured plaque with a central groove dividing the lesion into two halves (Coffee bean appearance) resulting from chronic persistent trauma due to ill-fitting spectacles

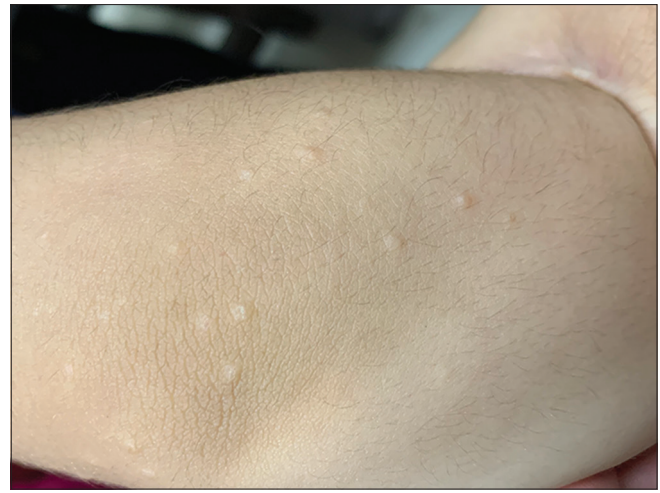


Figure 9: Frictional lichenoid eruption: Presents as grouped lichenoid papules over the elbows and knees in young children during spring and summer months

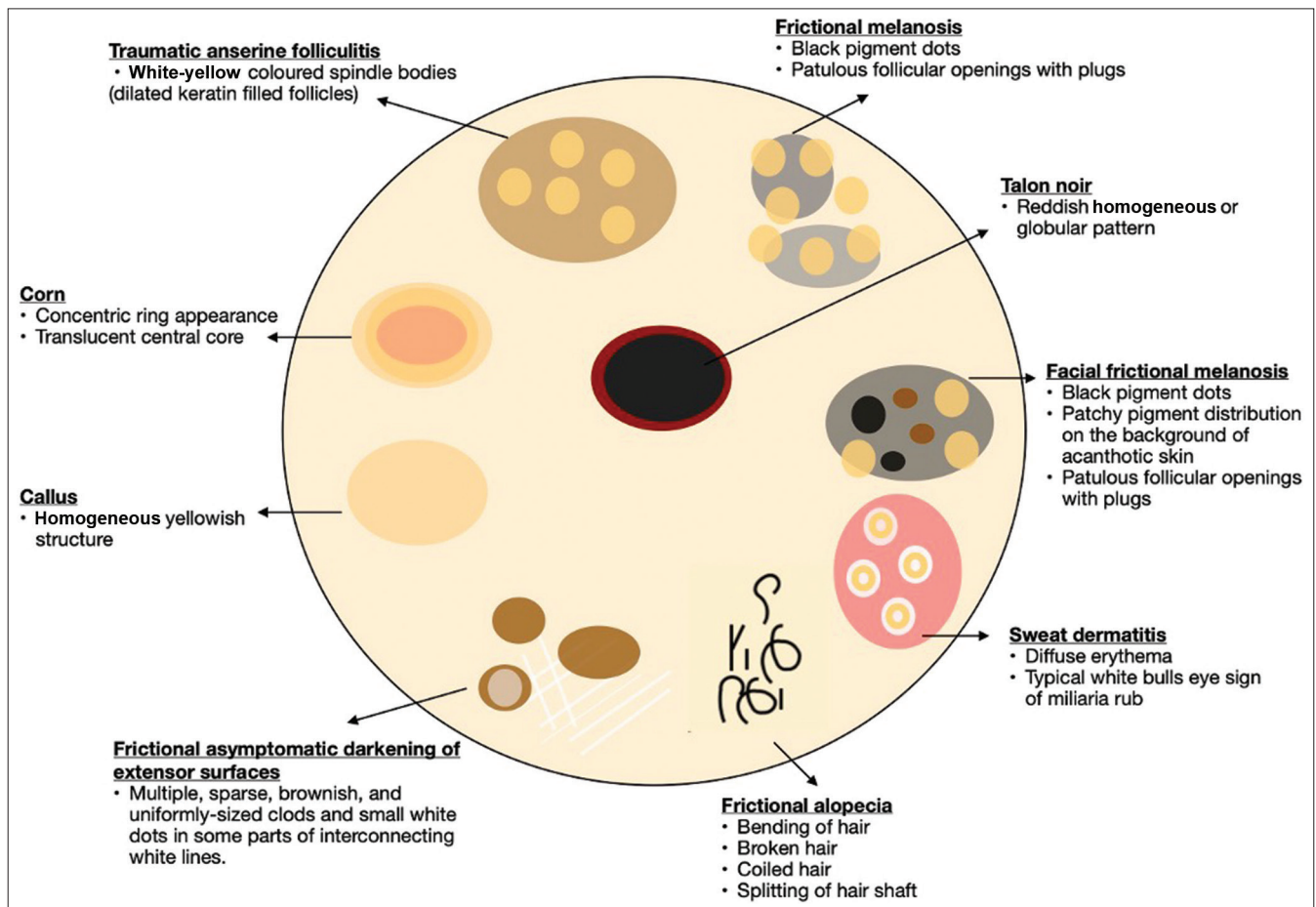


Figure 10a: Important dermoscopic features of frictional dermatoses. Most of the entities are characterised by lichenification and show hyperkeratosis, acanthosis and elongation of rete ridges. Hypergranulosis accompanying these features is seen in callus or nodule formation. Conditions presenting with folliculitis including traumatic anserine folliculitis and acne mechanica reveal dilated follicular infundibulum filled with keratin along with a mild perivascular infiltrate. Foreign-body reaction, with abscess, cyst and granuloma formation can be seen in Fiddler’s neck. Hyperpigmentation as seen in frictional melanosis, Lifa disease or Davener’s dermatitis correlates histologically with increased basal layer pigmentation and pigment incontinence. Friction blisters are characterised by an intraepidermal split without inflammation while eczematous lesions show oedema with intraepidermal neutrophilic and mononuclear infiltrate

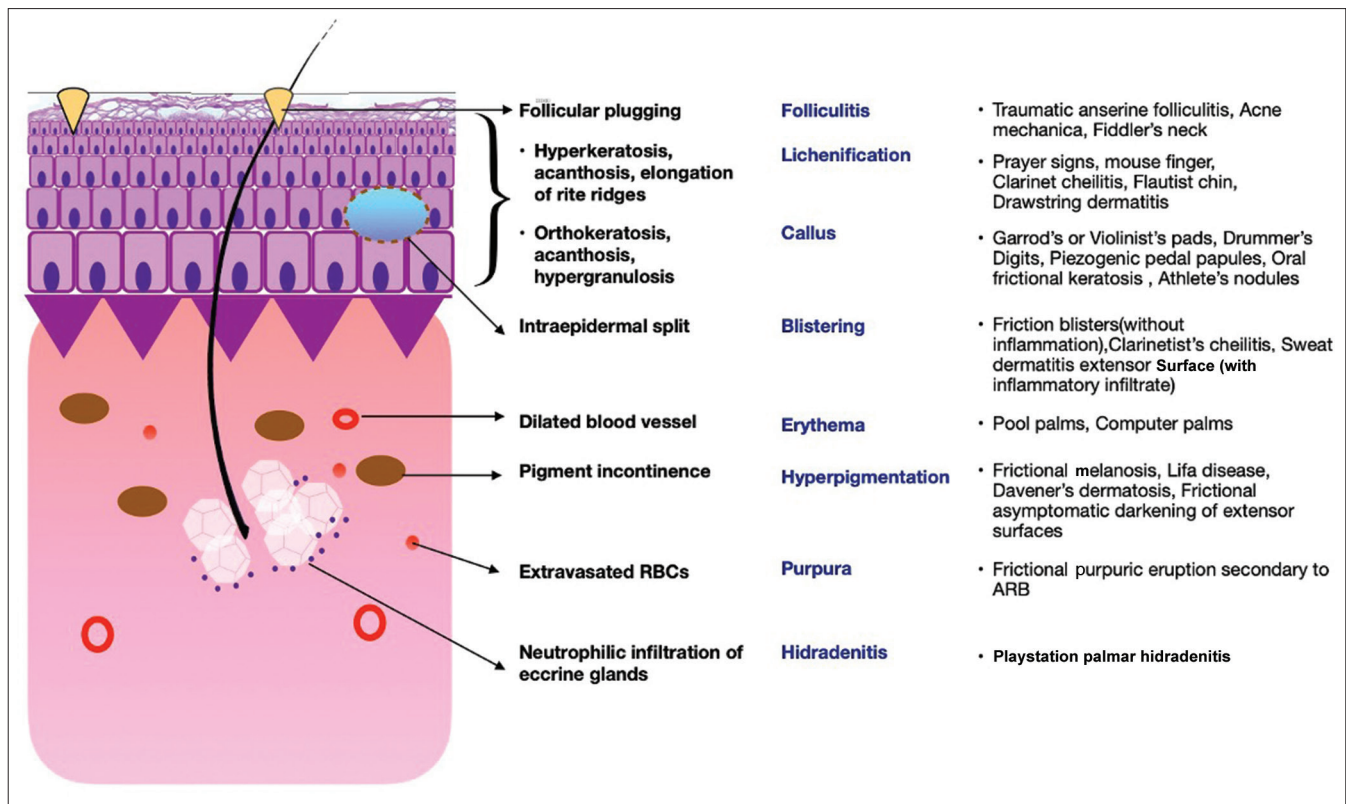


Figure 10b: Important histopathological features of frictional dermatoses: Most of the entities are characterised by lichenification and show hyperkeratosis, acanthosis and elongation of rete ridges. Hypergranulosis accompanying these features is seen in callus or nodule formation. Conditions presenting with folliculitis including traumatic anserine folliculitis and acne mechanica reveal dilated follicular infundibulum filled with keratin along with a mild perivascular infiltrate. Foreign-body reaction, with abscess, cyst and granuloma formation can be seen in Fiddler's neck. Hyperpigmentation as seen in frictional melanosis, Lifa disease or Davener's dermatitis correlates histologically with increased basal layer pigmentation and pigment incontinence. Friction blisters are characterised by an intraepidermal split without inflammation while eczematous lesions show oedema with intraepidermal neutrophilic and mononuclear infiltrate

in decreasing the hyperkeratosis and regulating epidermal proliferation. Various depigmenting agents such as retinoic acid analogues, kojic acid and arbutin help in decreasing hyperpigmentation. Q-switched Nd : YAG (1064 nm and 532 nm) laser has been found to be useful in frictional dermatoses with hyperpigmentation.^{27,83} Grenz rays help in decreasing the thickness of skin. A study reported remarkable improvement in patients with frictional hand dermatitis after six sessions, following a weekly dose of 400 rads (4Gy).⁸⁴

Current Times: Mechanical Dermatoses in The Era of COVID-19

In the era of COVID-19 three major types of mechanical dermatoses have been reported, which include device-related pressure injury,^{85,86} moisture-associated skin damage and skin tears.^{87,88} According to a study done by Jiang *et al.* the prevalence of device-related pressure injury skin injuries amongst healthcare workers was 30% and this prevalence was reported to be higher as compared to patients using respiratory devices, tubes and splints (2.1–27.9%).⁸⁹

This may be attributed to the prolonged duration of wearing personal protective equipment in combination with sweating and occlusion.

The common locations of device-related pressure injury among the medical personnel were bridge of the nose, ears, cheeks and forehead. Factors such as the pressure induced by the goggles on the bridge of nose and cheeks as well as the ear compression due to the mask strap, pressure on the forehead due to the surgical caps and face shield have been implicated [Figure 11].⁹⁰

Sweating leads to moisture-associated skin damage, which causes skin maceration as well as redness, itching, pain and pricking. Sweat-induced skin soaking along with pressure can cause increased friction coefficient between the personal protective equipment and skin; thus, when the mask and goggles are removed quickly, it can lead to skin tears. The factors associated with increased skin tears on logistic regression analysis by Jiang *et al.*, were grade of personal protective equipment, heavy sweating, daily wearing time and male gender.⁸⁹ Bhojru *et al.*, found a higher incidence of folliculitis/acne and occlusion and frictional dermatoses, when compared to glove related reactions.¹¹ Rustemeyer *et al.*, also found that tight fitting equipment induced pressure and friction could culminate in acne mechanica due to rupture of microcomedones.⁹¹ The authors suggested avoiding tight-fitting headgear and facemasks and recommended regular

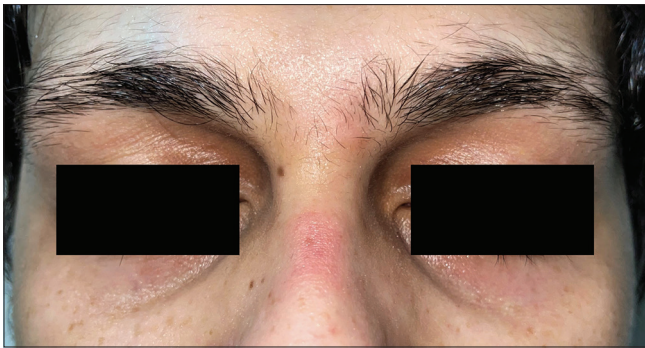


Figure 11: Mask induced frictional dermatoses over the bridge of the nose

washing and cleansing to help improve this condition. In regard to dermatoses due to skin friction, mechanical factors including material and repetitive forces when wearing personal protective equipment can lead to occupational and frictional dermatoses.⁹¹ The recommendations are to use materials with less shearing forces which are more breathable and comfortable. Furthermore, non-glove personal protective equipment specially footwear provides ideal environment for the growth of human papilloma virus since the moist environment and frictional forces associated with it increase the risk of abrasions and thus entry of human papilloma virus, causing warts.¹¹

Taking frequent breaks and removing excess sweat may facilitate alleviation of frictional dermatoses related to protective gear. Adequate hydration and regular use of emollients are essential to maintain barrier integrity and it is recommended that moisturisers should be used at least half an hour before wearing the mask. Low potency topical steroids or tacrolimus may be necessary in cases which fail to respond to conservative therapy.⁹²

Conclusion

Frictional dermatoses may be defined as ‘a group of disorders caused by repetitive trauma to the skin as a result of friction of varying aetiology, which can have a wide range of cutaneous manifestations depending on the type of insult.’

The susceptibility of an individual’s skin to friction differs and is influenced by factors both extraneous and inherent. The manifestation of friction related skin injury depends on the type of friction, intensity of the force and the nature of the surface and can clinically present as lichenification, hyperpigmentation, erythema, scaling, fissuring, blisters, ulceration and chronic alterations. We have devised a simple classification based on morphology, histopathological characteristics, anatomical region affected and the major predisposing factors such as the occupation. In the current era of COVID-19, three major types of mechanical dermatoses including device-related pressure injury, moisture-associated skin damage and skin tears have been described.

The diagnosis of frictional dermatoses is based on a detailed history and examination where the pattern of involvement provides valuable clues to the probable sources of friction and morphology helps establish the cause as well duration of the insult. The principles of treatment include providing symptomatic relief, determining the mechanical aetiology, treating the lesion and preventing further recurrence.

Declaration of patient consent

Patients’ consent not required as there are no patients in this study.

Financial support and sponsorship

Nil.

Conflicts of interest

There are no conflicts of interest.

References

- Conklin RJ. Common cutaneous disorders in athletes. *Sport Med* 1990;9:100-19.
- Al-Aboosi MM, Abalkhail A, Kasim O, Al-Khatib A, Qarqaz F, Todd D, et al. Friction melanosis: A clinical, histologic, and ultrastructural study in Jordanian patients. *Int J Dermatol* 2004;43:261-4.
- Natarajan E, Bin WS. Benign alveolar ridge keratosis (oral lichen simplex chronicus): A distinct clinicopathologic entity. *J Am Acad Dermatol* 2008;58:151-7.
- Müller S. Frictional keratosis, contact keratosis and smokeless tobacco keratosis: Features of reactive white lesions of the oral mucosa. *Head Neck Pathol* 2019;13:16-24.
- Soni R, Lokhande A, D’souza P. Atypical presentation of sweat dermatitis with review of literature. *Indian Dermatol Online J* 2019;10:698.
- Inui S, Yamamoto S, Ikegami R, Ozawa K, Itami S, Yoshikawa K. Baseball pitcher’s friction dermatitis. *Contact Dermatitis* 2002;47:176-7.
- Jakhar D, Kaur I. Frictional (Sock) alopecia of the legs: Trichoscopy as an aid. *Int J Trichol* 2018;10:129-30.
- Zhao J, Cohen PR. Frictional alopecia of the distal legs: Case series and review. *Dermatol Online J* 2016;22:129-30.
- Wong LS, Otsuka A, Tanizaki H, Nonomura Y, Nakashima C, Yamamoto Y, et al. Decrease of superficial serine and lactate in the stratum corneum due to repetitive frictional trauma. *Int J Dermatol* 2018;57:299-305.
- Wilkinson DS. Dermatitis from repeated trauma to the skin. *Am J Ind Med* 1985;8:307-17.
- Bhojyul B, Lecamwasam K, Wilkinson M, Latheef F, Stocks SJ, Agius R, et al. A review of non-glove personal protective equipment-related occupational dermatoses reported to EPIDERM between 1993 and 2013. *Contact Dermatitis* 2019;80:217-21.
- Gambichler T, Uzun A, Boms S, Altmeyer P, Altenmüller E. Skin conditions in instrumental musicians: A self-reported survey. *Contact Dermatitis* 2008;58:217-22.
- Cua AB, Wilhelm KP, Maibach HI. Elastic properties of human skin: Relation to age, sex, and anatomical region. *Arch Dermatol Res* 1990;282:283-8.
- Vilhena L, Ramalho A. Friction of human skin against different fabrics for medical use. *Lubricants* 2016;4:6.
- Zhong W, Xing MM, Pan N, Maibach HI. Textiles and human skin, microclimate, cutaneous reactions: An overview. *Cutan Ocul Toxicol* 2006;25:23-39.
- Myint CW, Rutt AL, Sataloff RT. Fiddler’s neck: A review. *Ear Nose Throat J* 2017;6:76-9.
- De Luca JF, Adams BB, Yosipovitch G. Skin manifestations of athletes competing in the summer olympics: What a sports medicine physician should know. *Sports Med* 2012;42:399-413.

18. Gupta D, Thappa DM. Dermatoses due to Indian cultural practices. *Indian J Dermatol* 2015;60:3–12.
19. Brienza D, Antokal S, Herbe L, Logan S, Maguire J, Van Ranst J, et al. Friction-induced skin injuries are they pressure ulcers? An updated NPUAP white paper. *J Wound Ostomy Cont Nurs* 2015;42:62–4.
20. Pigatto PD, Legori A, Bigardi AS. Occupational dermatitis from physical causes. *Clin Dermatol* 1992;10:231–43.
21. Morgado-Carrasco D, Feola H, Vargas-Mora P. Pool palms. *Dermatol Pract Concept* 2020;10:1–2.
22. Freiman A, Barankin B, Elpern DJ. Sports dermatology part 1: Common dermatoses. *CMAJ* 2004;171:851–3.
23. Tlough BE, Mancini AJ, Mandell JA, Cohen DE, Sanchez MR. Skin conditions in figure skaters, ice-hockey players and speed skaters: Part II cold-induced, infectious and inflammatory dermatoses. *Sport Med* 2011;41:967–84.
24. Yoshida M, Oiso N, Kawada A. Hyperkeratosis and frictional dermatitis from practicing Kendo. *Case Rep Dermatol* 2010;2:65–8.
25. Knapik JJ, Reynolds KL, Duplantis KL, Jones BH. Friction blisters: Pathophysiology, prevention and treatment. *Sport Med* 1995;20:136–47.
26. Singh D, Bentley G, Trevino SG. Callosities, corns, and calluses. *BMJ* 1996;312:1403–6.
27. Ashack KA, Griffiths C, Barker J, Bleiker T, Chalmers R, Creamer D, editors. *Rook's Textbook of Dermatology*. 9th ed. Hoboken, New Jersey: Wiley-Blackwell; 2016. p. 4696.
28. Sridhar J, Ray R. Frequency and associated factors of instrument-specific dermatoses among musicians in a military band: A cross-sectional study. *J Mar Med Soc* 2018;20:111–5.
29. Lindgren AL, Hui Austin A, Welsh KM. Cell thumb replaces writer's bump: Changing times, changing callouses. *Case Rep Dermatol* 2020;12:1–4.
30. Ghasri P, Feldman SR. Frictional lichenified dermatoses from prolonged use of a computer mouse: Case report and review of the literature of computer-related dermatoses. *Dermatol Online J* 2010;16:12.
31. Mutalik S, Pethe S, Nikam B, Rasal Y. Facial frictional melanosis in Indian patients: Defining the entity. *Clin Dermatol Rev* 2019;3:78.
32. Naimer SA, Trattner A, Biton A, Avinoach I, Vardy D. Davener's dermatoses: A variant of friction hypermelanosis. *J Am Acad Dermatol* 2000;42:442–5.
33. Sharquie KE, Al-Dorky MK. Frictional dermal melanosis (Lifa disease) over bony prominences. *J Dermatol* 2001;28:12–5.
34. Diamond G, Ben AD. Orphan rocker tracks: A variant of friction melanosis in an institutionalized child. *Pediatr Dermatol* 2013;30:198–9.
35. Wollina U, Tchernev G, Lotti T. Frictional dermatoses in a courier driver. *Open Access Maced J Med Sci* 2017;5:541–2.
36. Krishnamurthy S, Sigdel S, Brodell RT. Frictional asymptomatic darkening of the extensor surfaces. *Cutis* 2005;75:349–55.
37. Sharquie KE, Noaimi AA, Hajji AA. Frictional melanosis of rubbing thighs in Iraqi patients. *J Cosmet Dermatological Sci Appl* 2014;4:203–11.
38. Tanigaki T, Hata S, Kitano Y, Sano S. Epidemiological survey of nylon cloths friction dermatoses in Japan. *J Dermatol* 1985;12:498–501.
39. Verma SB. Dermatological signs in South Asian women induced by sari and petticoat drawstrings: Clinical dermatology. *Clin Exp Dermatol* 2010;35:459–61.
40. Lilly E, Kundu RV. Dermatoses secondary to Asian cultural practices. *Int J Dermatol* 2012;51:372–82.
41. Ladizinski B, Lee KC. Religion and the skin: Devotional dermatoses. *JAMA Dermatol* 2013;149:1322.
42. Verma SB, Wollina U. Callosities of cross-legged sitting: "Yoga sign"—an under-recognized cultural cutaneous presentation. *Int J Dermatol* 2008;47:1212–4.
43. Mazhar M, Simpson M, Marathe K. Inner thigh friction as a cause of acne mechanica. *Pediatr Dermatol* 2019;36:546–7.
44. Rambhia KD, Wankhade V, Mukhi J, Singh RP. Traumatic anserine folliculosis. *Indian Dermatol Online J* 2017;8:59–61.
45. Lyon CC, Kulkarni J, Zimerson E, Van Ross E, Beck MH. Skin disorders in amputees. *J Am Acad Dermatol* 2000;42:501–7.
46. Mehta SD, Krieger JN, Agot K, Moses S, Ndinya-Achola JO, Parker C, et al. Circumcision and reduced risk of self-reported penile coital injuries: Results from a randomized controlled trial in Kisumu, Kenya. *J Urol* 2010;184:203–9.
47. Jorizzo JL, Subrt P, Smith EB, King CA, Henry JC, Archer E. Frictional dermatitis of Onan. *JAMA* 1983;250:362.
48. Toback AC, Korson R, Krusinski PA. Pulling boat hands: A unique dermatoses from coastal New England. *J Am Acad Dermatol* 1985;12:649–55.
49. Kieliszak CR, Junkins-Hopkins JM. Athlete's nodule in a figure skater: An unusual presentation. *Am J Dermatopathol* 2015;37:e21–5.
50. Urbina F, León L, Sudy E. Black heel, talon noir or calcaneal petechiae? *Australas J Dermatol* 2008;49:148–51.
51. Jaworski CA, Ballantine-Talmadge S. On thin ice: Preparing and caring for the ice skater during competition. *Curr Sports Med Rep* 2008;7:133–7.
52. Janowicz RA. How To Evaluate Figure Skating Injuries Podiatry Today. *Podiatry Today*; 2020. Available from: <https://www.hmpglobelearningnetwork.com/site/podiatry/article/5374> [last accessed on 2022 Feb 01].
53. Brown TD, Varney TE, Micheli LJ. Malleolar bursitis in figure skaters: Indications for operative and nonoperative treatment. *Am J Sports Med* 2000;28:109–11.
54. Redbord KP, Adams BB. Piezogenic pedal papules in a marathon runner. *Clin J Sport Med* 2006;16:81–3.
55. Montgomery F, Fioriti A. Piezogenic pedal papules: Treated by resection and hernial closure. *Foot* 1998;8:171–2.
56. Phillips S, Seiverling E, Silvis M. Pressure and friction injuries in primary care. *Prim Care* 2015;42:631–44.
57. Ruiz-Hornillos FJ, Alonso E, Zapatero L, Pérez C, Martínez-Molero I. Clarinetist's cheilitis caused by immediate-type allergy to cane reed. *Contact Dermatitis* 2007;56:243–5.
58. Inoue A, Shoji A, Fujita T. Flautist's chin. *Br J Dermatol* 1997;136:147.
59. Rimmer S, Spielvogel RL. Dermatologic problems of musicians. *J Am Acad Dermatol* 1990;22:657–63.
60. Cohen PR. Harpist's finger: Case report of a trauma-induced blister in a beginner harpist and review of string instrument-associated skin problems in musicians. *Cutis* 2008;82:329–34.
61. Corazza M, Minghetti S, Bertoldi AM, Martina E, Virgili A, Borghi A. Modern electronic devices: An increasingly common cause of skin disorders in consumers. *Dermatitis* 2016;27:82–9.
62. Vermeer MH, Bruynzeel DP. Mouse fingers, a new computer-related skin disorder (2). *J Am Acad Dermatol* 2001;45:477.
63. Goksugur N, Cakici H. A new computer-associated occupational skin disorder: Mousing callus. *J Am Acad Dermatol* 2006;55:358–9.
64. Ber A. The sign of dirty knees and elbows. *Acta Endocrinol (Copenh)* 1954;16:305–8.
65. Deshpande N, Sen A, Vasudevan B, Neema S. Acanthoma fissuratum: Lest we forget. *Indian Dermatol Online J* 2017;8:141.
66. Kennedy CM, Dewdney S, Galask RP. Vulvar granuloma fissuratum: A description of fissuring of the posterior fourchette and the repair. *Obstet Gynecol* 2005;105:1018–23.
67. Ramam M, Khaithan BK, Singh MK, Gupta SD. Frictional sweat dermatitis. *Contact Dermatitis* 1998;38:49.
68. Stamatas GN, Tierney NK. Diaper dermatitis: Etiology, manifestations, prevention, and management. *Pediatr Dermatol* 2014;31:1–7.
69. Moorthy TT, Rajan VS. Juvenile plantar dermatoses in Singapore. *Int J Dermatol* 1984;23:476–9.
70. Sardana K, Goel K, Garg VK, Goel A, Khanna D, Grover C, et al. Is frictional lichenoid dermatitis a minor variant of atopic dermatitis or a photodermatoses. *Indian J Dermatol* 2015;60:66–73.
71. Ale SI, Maibach HI. Irritant contact dermatitis ersus allergic contact dermatitis. *Irritant Dermatitis* 2008;2008:11–8.
72. Prabhakara VG, Chandra S, Shankar KD. Frictional pigmentary dermatoses: A clinical and histopathological study of 27 cases. *Indian J Dermatol Venereol Leprol* 1997;63:99–100.
73. Thoyyib M, Menon R, David BG. Clinical spectrum of facial hypermelanosis: A descriptive study from a tertiary care centre. *Int J Res Dermatol* 2020;6:212.
74. Verma SB, Vasani RJ, Chandrashekar L, Thomas M. Seborrheic melanosis: An entity worthy of mention in dermatological literature. *Indian J Dermatol Venereol Leprol* 2017;83:285–9.
75. Russo F, Flori ML, Taddeucci P, Rubegni P, Cinotti E. Pigmentary demarcation lines of Voigt-Futcher: Dermoscopic and reflectance confocal microscopy features. In: *Skin Research and Technology*. Vol. 26. Blackwell Publishing Ltd.; 2020. p. 440–2.

76. Vinay K, Ankad BS. Dermatoscopic features of pigmented diseases in ethnic skin. *Indian Dermatol Online J* 2021;12:24–33.
77. Jampani K, Jampani S. A clinico-histopathological study of frictional melanosis. *J Evid Based Med Healthc* 2016;3:2465–8.
78. Hall KH, Rapini RP. *Acral lentiginous melanoma*. Treasure Island, FL: StatPearls Publishing; 2021.
79. Mole RJ, MacKenzie DN. *Cancer, Melanoma, Subungual*. Treasure Island, FL: StatPearls Publishing; 2019.
80. Nayak SS, Mehta HH, Gajjar PC, Nimbark VN. Dermoscopy of general dermatological conditions in Indian population: A descriptive study. *Clin Dermatol Rev* 2017;1:41–51.
81. Tan C, Xia L. Dermoscopy of frictional asymptomatic darkening of the extensor surfaces. *Adv Dermatol Allergol* 2019;36:232–3.
82. Brennan FH. Managing blisters in competitive athletes. *Curr Sports Med Rep* 2002;1:319–22.
83. Al-Dhalimi MA, Maluki AH, Tauma A. Efficacy and safety of 532-nm and 1,064-nm Q-switched Nd : YAG laser treatment of frictional dermal melanosis over bony prominences (lifa disease). *Dermatol Surg* 2015;41:136–41.
84. Walling HW, Swick BL, Storrs FJ, Boddicker ME. Frictional hyperkeratotic hand dermatitis responding to Grenz ray therapy. *Contact Dermatitis* 2008;58:49–51.
85. Barakat-Johnson M, Lai M, Wand T, Li M, White K, Coyer F. The incidence and prevalence of medical device-related pressure ulcers in intensive care: A systematic review. *J Wound Care* 2019;28:512–21.
86. Kayser SA, Vangilder CA, Ayello EA, Lachenbruch C. Prevalence and analysis of medical device-related pressure injuries: Results from the international pressure ulcer prevalence survey. *Adv Ski Wound Care* 2018;31:276–85.
87. Ayello EA. CMS MDS 3.0 section M skin conditions in long-term care: Pressure ulcers, skin tears, and moisture-associated skin damage data update. *Adv Ski Wound Care* 2017;30:415–29.
88. Zulkowski K. Understanding moisture-associated skin damage, medical adhesive-related skin injuries, and skin tears. *Adv Ski Wound Care* 2017;30:372–81.
89. Jiang Q, Song S, Zhou J, Liu Y, Chen A, Bai Y, *et al.* The prevalence, characteristics, and prevention status of skin injury caused by personal protective equipment among medical staff in fighting COVID-19: A multicenter, cross-sectional study. *Adv Wound Care* 2020;9:357–64.
90. National Health Commission of the People's Republic of China. The Management of COVID-19 Prevention and Control. 5th ed. <http://www.nhc.gov.cn/jkj/s3577/202002/a5d6f7b8c48c451c87dba14889b30147/files/3514cb996ae24e2faf65953b4ecd0df4.pdf> [Last accessed on 2020 Feb 21].
91. Rustemeyer T, Elsner P, John SM, Maibach HI. *Kanerva's Occupational Dermatology*. 2nd ed. Berlin: Springer; 2012.
92. Singh M, Bhargava S, Pawar M, Jatana G, Maheswari A, Bothra A. Jogger's facial dermatoses: An emerging entity in COVID-19 pandemic. *Dermatol Ther* 2020;33:e14293.