

Conflicts of interest

There are no conflicts of interest.

Policlinico, Milan, Italy.
maurizio.romagnuolo@unimi.it

**Maurizio Romagnuolo, Chiara Moltrasio¹,
Silvia Alberti Violetti², Davide Riva,
Francesco Barberi, Alessandra Di Benedetto²,
Francesca Boggio³**

Dermatology Unit, Department of Pathophysiology and Transplantation, Università degli Studi di Milano, Milan, ¹Department of Medical Surgical and Health Sciences, University of Trieste, Trieste, ²Dermatology Unit, ³Pathology Unit, Fondazione IRCCS Ca' Granda Ospedale Maggiore Policlinico, Milan, Italy.

Corresponding author:

Dr. Maurizio Romagnuolo,
Dermatology Unit,
Fondazione IRCCS Ca' Granda
Ospedale Maggiore

References

1. Lira-Valero FJ, Carrillo-Cisneros ER, Pulido-Díaz N, Quintal-Ramírez MJ, Godínez-Aldrete L. Circumscribed storiform collagenoma, an unusual tumor. *Dermatol Online J* 2020;26:13030/qt3cm905c1.
2. Kieselova K, Santiago F, Henrique M, Cunha MF. Multiple sclerotic fibromas of the skin: An important clue for the diagnosis of Cowden syndrome. *BMJ Case Rep* 2017;2017:bcr2017221695.
3. Nakashima K, Yamada N, Adachi K, Yoshida Y, Yamamoto O. Solitary sclerotic fibroma of the skin: Morphological characterization of the 'plywood-like pattern'. *J Cutan Pathol* 2008;35 Suppl 1:74–9.
4. Ebadian M, Citarella L, Collins D, Diaz-Cano S, Pozo-García L. Dermoscopy of a solitary storiform collagenoma. *Dermatol Pract Concept* 2018;8:120–2.
5. McCalmont TH. Sclerotic fibroma: A fossil no longer. *J Cutan Pathol* 1994;21:82–5.
6. Cohen PR, Tschen JA, Abaya-Blas R, Cochran RJ. Recurrent sclerotic fibroma of the skin. *Am J Dermatopathol* 1999;21:571–4.

An observational study to describe dermoscopic features of sweat dermatitis and assess the treatment outcome

Dear Editor,

Sweat dermatitis was first described by Ramam *et al.*¹ in 1998, as an irritant dermatitis caused due to excessive stagnant sweat produced due to high temperature and low humidity.² Risk factors include tight clothing, friction, and synthetic clothing that do not absorb sweat.³ It is seen both over convex areas such as lateral back, chest, and abdomen as well as concave areas such as lower back, cubital fossa, axilla, inter and submammary area, neck, and midline groove of the back.⁴ Clinically, it presents as dry, fissured, crinkled, hyperpigmented plaques with well-defined borders.⁵

This was a single-center observational study of 10 patients with sweat dermatitis diagnosed at the tertiary care center in North India, from April 2022 to September 2022. The study was done in summer where the daytime temperature reaches up to 49°C due to the prevailing heat wave.⁶ The diagnosis of sweat dermatitis was made based on the acute onset pruritic papules and scaly plaques on the classical sites (back, axillae, and inframammary areas), preceding history of increased sweating and rapid response to treatment. Written informed

consent was taken from all patients/guardians. Clinical (age, sex, occupation, duration, relationship with sweating, use of synthetic clothing, sites involved, and morphology) and dermoscopic data was collected from all the patients and histopathological evaluation was done on two patients. Patients were contacted through telephone to enquire regarding recurrence of the symptoms.

A total of 10 patients were enrolled in this study. The mean age of presentation was 26.4 ± 8 (range; 10–38) years with male–female ratio of four and mean duration of disease was 8.1 ± 9.4 (range; 2–20, median; 8.5) days. The mean follow-up period was 2.5 ± 1.5 (range; 0.3–5) months. Two patients had history of similar lesions on the same sites in the previous year in summer, which resolved in 2–3 weeks. Use of synthetic clothes was present in 2 (20%) patients. The most common site of involvement was back (9/10; 90%) and other sites were infra-axillary area (2/10; 20%), inframammary area (1/10; 10%) and forehead (1/10; 10%). Patients presented with multiple erythematous to skin-coloured tiny pinhead-sized papules on background of erythema (active stage; Figures 1a and 1b)

How to cite this article: Mustari A, Garg D, Thind A, Narayan RV, Parkhi M, Vinay K. An observational study to describe dermoscopic features of sweat dermatitis and assess the treatment outcome. *Indian J Dermatol Venereol Leprol.* 2024;90:226–9. doi: 10.25259/IJDVL_1119_2022

Received: December, 2022 **Accepted:** April, 2023 **Epub Ahead of Print:** May, 2023 **Published:** February, 2024

DOI: 10.25259/IJDVL_1119_2022 **PMID:** 37317752

This is an open-access article distributed under the terms of the Creative Commons Attribution-Non Commercial-Share Alike 4.0 License, which allows others to remix, tweak, and build upon the work non-commercially, as long as the author is credited and the new creations are licensed under the identical terms.

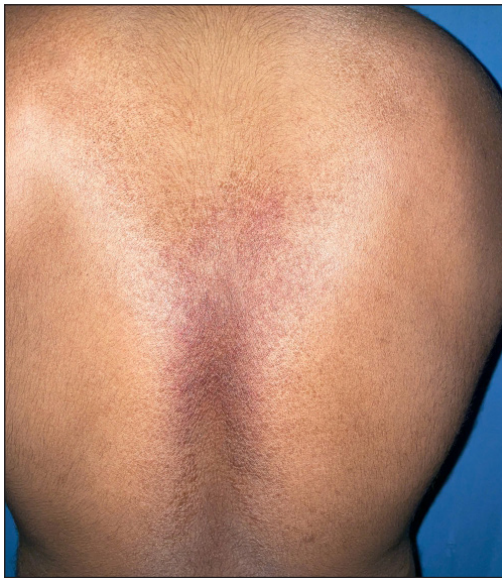

Figure 1a: Clinical presentation (active stage) - Erythematous pinhead-sized papules on a background of erythema over the midline of the back

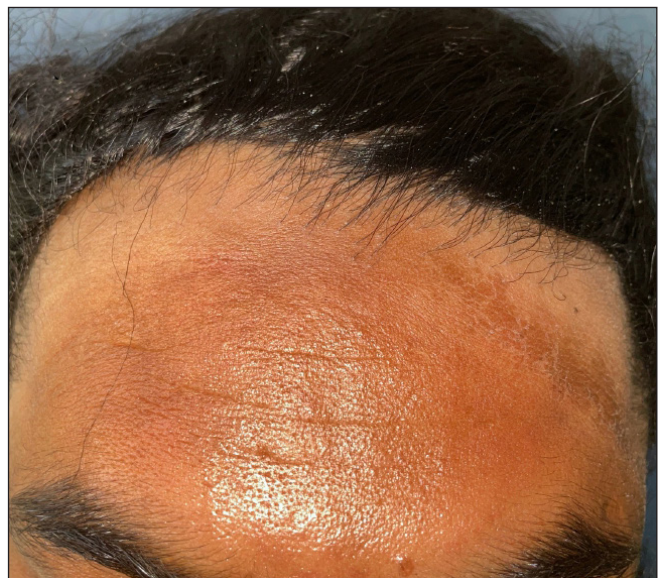

Figure 1b: Clinical presentation (active stage) - Scaling on the background of erythema over forehead due to excessive sweat and occlusion due to the use of turban

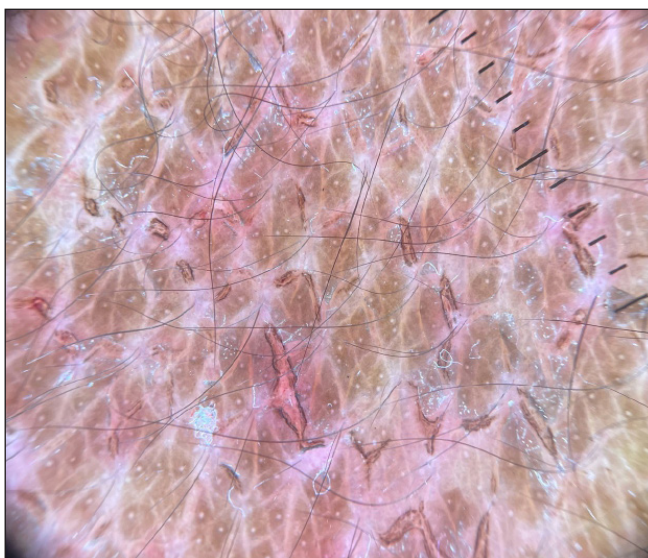


Figure 1c: Dermoscopy image of the active stage showing multiple linear erosions with brownish crusting in a hexagonal pattern on the background of erythema. Prominent eccrine gland openings can also be appreciated

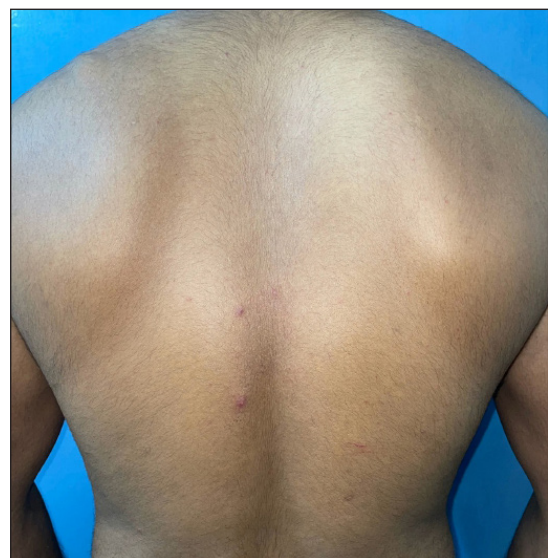


Figure 1d: Clinical presentation (active stage) - Complete improvement after 7 days of treatment.

in 40% (4/10) and greyish-brown scaling on background of dry hyperpigmented skin (resolving stage; Figure 2a) in 60% (6/10) of the patients and mean duration of disease in these patients was 3.2 and 11.3 days, respectively ($p = 0.002$). Pruritus was present in all the patients (100%; 10/10). Nine (9/10; 90%) patients reported history of excessive sweating prior to the development of skin lesions [Table 1].

Dermoscopy of the active stage revealed multiple erosions surrounded by brownish crust in a linear (4/10; 40%) and hexagonal pattern (2/10; 20%) with surrounding greyish-white semi-adherent scaling on the background of erythema [Figure 1c]. Dermoscopic evaluation of the resolving stage

showed greyish-brown oval to polygonal scaling on background of erythema in 60% (6/10) of the patients with prominent eccrine openings and none of the patients had erosions [Figure 2b and Table 2]. Histopathological examination done in 2 patients revealed eroded epithelium, spongiosis, papillary dermal edema and mild superficial dermal perivascular infiltrate of lymphocytes and histiocytes [Figure 3]. All patients were treated with a once-daily application of mometasone furoate 0.1% cream and anti-histamine. There was complete resolution of the lesions and symptoms within 7 days in 90% (9/10) of the patients and lesions resolved after 12 days in one (1/10; 10%) patient. None of the patients had

Table 1: Clinical features and treatment repose of the patients

Age/Sex	Occupation/Factors contributing to increased sweating	Duration (days)	Sites/Symmetry	Past history	History of excessive sweating	Presentation	Improvement after 7 days
25/M	Horticulturist	2	Back/Symmetrical	No	Yes	Active stage*	Complete
30/M	Cycling	3	Back/Symmetrical	Yes	Yes	Active stage*	Complete
35/M	Farmer	4	Back, forehead and infra-axillary area/ Symmetrical except over forehead	Yes	Yes	Active stage*	Partial
21/F	Student	4	Back/Symmetrical	No	No	Active stage*	Partial
38/M	Physical exercise	10	Back/Symmetrical	No	Yes	Resolving stage [#]	Complete
26/M	Driver	9	Back/Symmetrical	No	Yes	Resolving stage [#]	Complete
10/M	Student/Physical activity	20	Back/Symmetrical	No	Yes	Resolving stage [#]	Complete
26/F	Homemaker	12	Inframammary/Symmetrical	No	Yes	Resolving stage [#]	Complete
32/M	Security guard	8	Back and infra-axillary area/Symmetrical	No	Yes	Resolving stage [#]	Complete
21/M	Student	9	Back/Asymmetrical	No	Yes	Resolving stage [#]	Complete

*Active stage, multiple erythematous to skin-coloured tiny pinhead-sized papules on background of erythema; [#]Resolving stage, greyish-brown scaling on background of dry hyperpigmented skin; M, male; F, female

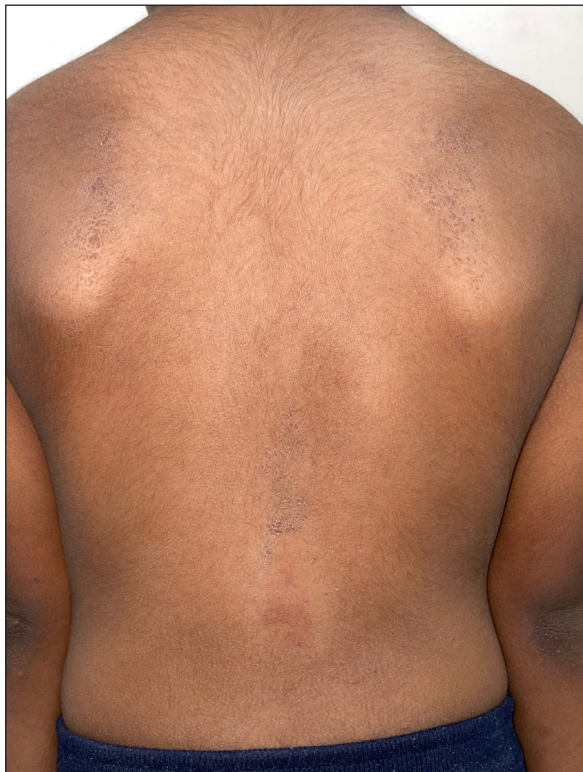

Figure 2a: Clinical presentation (resolving stage) showing greyish-brown scaling on midline over back (concave area) and medial scapular margins (convex area)

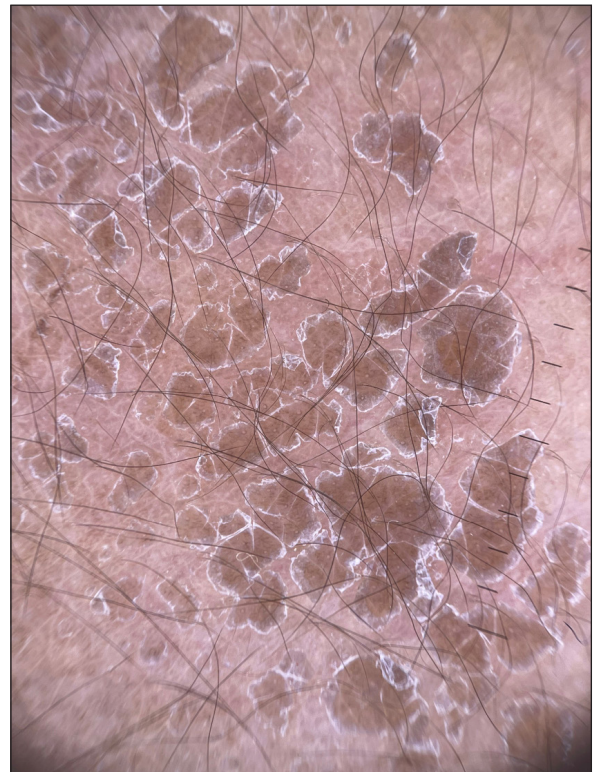


Figure 2b: Dermoscopy image of resolving stage showing greyish-brown oval to polygonal scaling on background of erythema

any residual changes [Figure 1d]. All patients were advised to avoid strenuous activity in hot and low humid environment to prevent recurrence.

Sweat dermatitis is one of the important causes of morbidity in tropical countries and is commonly seen in the 3rd–4th decade in the summer season. The prolonged exposure to sweat under occlusion causes cumulative damage to stratum corneum and facilitates delivery of other irritants leading to dermatitis. Use of synthetic clothes increases risk of sweat

dermatitis as they do not absorb sweat.⁷ Two morphological types were observed in our patients, acute and resolving stage. This classification was done based on the morphology (erythematous papules and background of erythema in active stage and only scaling on background of hyperpigmentation in resolving stage) and mean duration of disease (3.2 days in active stage and 11.3 days in resolving stage; $P = 0.02$).

Soni *et al.* described dermoscopy of sweat dermatitis as brown, fissured plaque, which showed deep brown pigmentation with

Table 2: Dermoscopic features of sweat dermatitis

Dermoscopic features	Number (percentage)
Active stage	
Multiple erosions with brown crusting	4 (40)
Linear pattern	4 (40)
hexagonal pattern	2 (20%)
Background erythema	4 (40)
Prominent eccrine openings	4 (40)
Resolving stage	
Greyish-brown oval to polygonal scaling	6 (60)
Background of erythema	6 (60)
Prominent eccrine openings	6 (60)
Erosions	0 (0)

superimposed scaling at some places, along with increased skin markings. Another case of maculopapular sweat dermatitis showed focal areas of necrosis and yellow-white lacunar areas giving rise to starry sky appearance.^{5,7} Our patients also showed greyish-brown scaling on the background of erythema in lesions in resolving stage. Multiple linear erosions with brownish crusting in a hexagonal pattern seen in active stage was a novel finding in our case series. Multiple linear erosions and crusting in a patterned distribution are caused due to extravasated sweat-induced irritant reaction and correspond to the epidermal erosions seen histologically. Interestingly, this feature was observed only in patients who presented early in the course of the disease (active stage). Exaggerated reticular network and background erythema surrounding the dilated eccrine openings depicts eccrine gland inflammation.

Differential diagnosis of sweat dermatitis is miliaria rubra, which also presents with multiple erythematous non-follicular papules over back. Dermoscopy of miliaria rubra is distinct and is characterized by central white area surrounded by a darker halo resembling bull's-eye which differentiates it from sweat dermatitis.⁸ Skin biopsy could be helpful in doubtful cases to rule out other differential diagnoses such as miliaria rubra.

Sweat dermatitis has an acute onset of presentation and has spectrum of clinical manifestations depending on the timing of presentation with a rapid response to treatment. Dermoscopy can be a good adjunct in the diagnosis that helps in better management of patients.

Declaration of patient consent

The authors certify that they have obtained all appropriate patient consent.

Financial support and sponsorship

Nil.

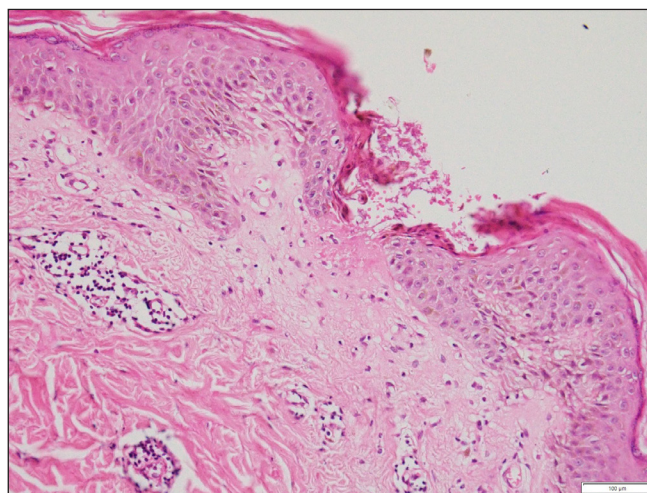


Figure 3: The skin biopsy shows eroded epithelium, spongiosis, and superficial dermal mild perivascular infiltrate of lymphocytes and histiocytes (Hematoxylin and eosin, x400)

Conflicts of interest

There are no conflicts of interests.

**Akash Mustari, Divya Garg, Anish Thind,
Vignesh Narayan R, Mayur Parkhi¹,
Keshavamurthy Vinay**

Departments of Dermatology, Venereology and Leprology,
¹Histopathology, PGIMER,
Chandigarh, India.

Corresponding author:

Dr. Keshavamurthy Vinay,
Department of Dermatology, Venereology and Leprology,
PGIMER, Sector-12, Chandigarh, India.
vinay.keshavmurthy@gmail.com

References

- Ramam M, Khaitan BK, Singh MK, et al. Frictional sweat dermatitis. *Contact Dermatitis* 1998;38:49–50.
- Chatterjee M, Vasudevan B. A study of desert dermatoses in the Thar Desert region. *Indian J Dermatol* 2015;60:21–7.
- Gopinath H, Karthiga R, Karthikeyan K. A cross-sectional study of sweat-induced dermatitis during a South Indian summer: a glimpse of sweat gland-mediated cutaneous inflammation. *Int J Dermatol* 2019;86–90.
- Mehta RD, Bumb RA. Sweat dermatitis. *Int J Dermatol* 2000;39:872.
- Soni R, Lokhande AJ, D'souza P. Atypical presentation of sweat dermatitis with review of literature. *Indian Dermatol Online J* 2019;10:698–703.
- Hrishikesh S, Sebastian M. Delhi suffers at 49C as heatwave sweeps India. *BBC News*, May 16, 2022, <https://www.bbc.com/news/world-asia-india-61242341>.
- Deepak V, Parul K, Chaudhary SR, Vashisht. Descriptive study of sweat dermatitis: A rare dermatoses not so rare in tropics, *Medical Journal Armed Forces India*. Available at: <https://doi.org/10.1016/j.mjafi.2022.11.004>
- Mohan S, Behera B, Chandrashekar L, Kar R, Thappa DM. Bull's-eye pattern in miliaria rubra. *Australas J Dermatol* 2014;55:263–5.