

Observation Letters

Varenicline-induced symmetrical drug-related intertriginous and flexural exanthema

Sir,

Symmetrical drug-related intertriginous and flexural exanthema is a drug-induced eruption characterized by symmetrical distribution of well-demarcated erythema of the inguinal, gluteal and other intertriginous areas. The most common offending drug is β -lactam antibiotics, particularly amoxicillin. In addition, acetaminophen, hydroxyzine, ranitidine and radiocontrast have been reported to be causative drugs.^{1,2} Varenicline is a selective partial agonist for the $\alpha 4\beta 2$ nicotinic acetylcholine receptor, which was approved by the United States Food and Drug Administration in May 2006 for tobacco cessation. We were unable to find any previous reports of varenicline-induced symmetrical drug-related intertriginous and flexural exanthema. Here, we report a rare case of varenicline-induced symmetrical drug-related intertriginous and flexural exanthema.

A 50-year-old male presented to our clinic with progressive itchy skin rash over neck and buttocks which had persisted for 20 days. These skin lesions had developed 2 days after taking varenicline 1.0 mg daily for smoking cessation. The patient reported a history of epilepsy, treated with oxcarbazepine for the past 2 years without dose adjustment in the last year. On physical examination, erythematous macules and patches were found to be symmetrically distributed over the buttocks, anterior neck and inguinal region [Figures 1a and 1b]. There was no mucosal involvement, blister or pustule formation. Systemic examination was within normal limits. Laboratory tests revealed no other systemic involvement. A skin biopsy from the buttock region showed

basket-weave hyperkeratosis, mild acanthosis, perivascular lymphocytes and eosinophil infiltration [Figure 2].

On the basis of these findings, symmetrical drug-related intertriginous and flexural exanthema was diagnosed. The causality of varenicline-induced symmetrical drug-related intertriginous and flexural exanthema was in the probable category according to the Naranjo Adverse Drug Reaction Probability Scale (a score of 6) [Table 1].³ Administration of varenicline was discontinued, and the patient received one dose of 5 mg dexamethasone intramuscular injection. Oral antihistamine and mometasone furoate 0.1% cream were also prescribed. After treatment for 2 weeks, the skin lesions gradually resolved. One month later, we performed lymphocyte activation assay by measuring granulysin level which has been previously published.⁴ Drugs were diluted in the medium to obtain a concentration reflecting the physiological therapeutic range. The result revealed a positive finding of 1.7-fold elevation in granulysin level when varenicline was administered compared with a negative control of phosphate buffered saline (normal healthy control, 1.04 ± 0.24 -fold elevation in granulysin level). Oxcarbazepine findings were negative. Oral provocation test was not performed because varenicline could lower seizure threshold. The patient was followed up for 3 months; with no recurrence.

The term SDRIFE that is symmetrical drug-related intertriginous and flexural exanthema was first described by Häusermann *et al.* in 2004, and five diagnostic criteria were proposed: (1) Exposure to a systemically administered

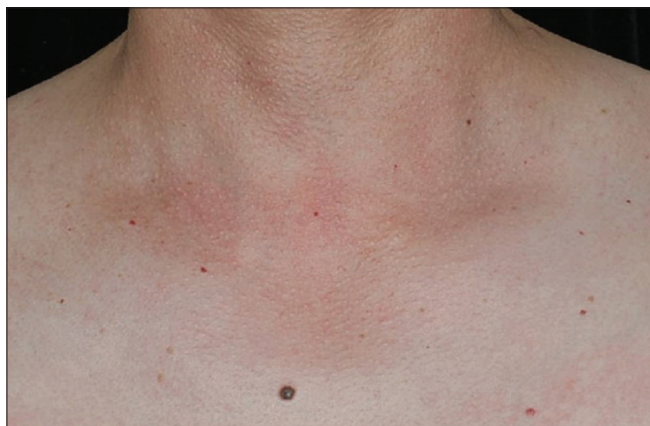

Figure 1a: Erythematous macules and patches symmetrically distributed on anterior neck

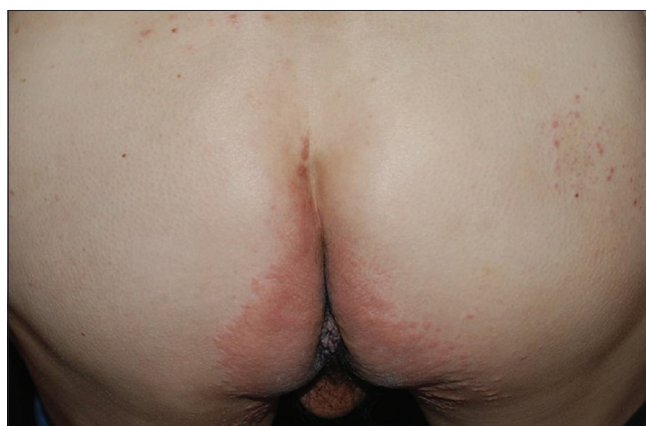

Figure 1b: Erythematous macules and patches symmetrically distributed on buttocks

Table 1: Naranjo adverse drug reaction probability scale

Questions	Yes	No	Do not know	Score in this case
Are there previous conclusive reports on this reaction?	+1	0	0	0
Did the adverse event occur after the suspected drug was administered?	+2	-1	0	+2
Did the adverse reaction improve when the drug was discontinued or a specific antagonist was administered?	+1	0	0	+1
Did the adverse reaction reappear when the drug was re-administered?	+2	-1	0	0
Are there alternative causes (other than the drug) that could have, on their own, caused the reaction?	-1	+2	0	+2
Did the reaction reappear when a placebo was given?	-1	+1	0	0
Was the drug detected in the blood (or other fluids) in concentrations known to be toxic?	+1	0	0	0
Was the reaction more severe when the dose was increased or less severe when the dose was decreased?	+1	0	0	0
Did the patient have a similar reaction to the same or similar drugs in any previous exposure?	+1	0	0	0
Was the adverse event confirmed by any objective evidence?	+1	0	0	+1
Total scores				6

Scoring ≥9: Definite, 5-8: Probable, 1-4: Possible, 0: Doubtful

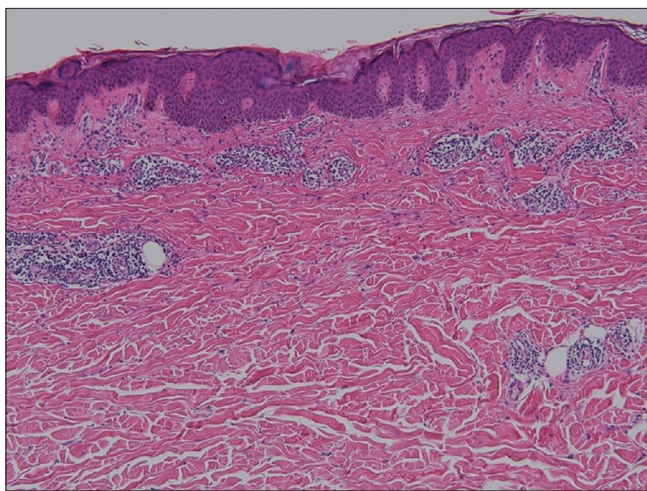


Figure 2: Histopathology showed basket wave hyperkeratosis, mild acanthosis and perivascular lymphocytes and eosinophils infiltration (hematoxylin and eosin, ×100)

drug either at the first or repeated dose (excluding contact allergens); (2) sharply demarcated erythema of the gluteal/perianal area and/or V-shaped erythema of the inguinal/perigenital area; (3) involvement of at least one other intertriginous/flexural localization; (4) symmetry of affected areas; and (5) absence of systemic symptoms and signs.⁵ Our case met all the above-mentioned criteria.

The diagnosis of symmetrical drug-related intertriginous and flexural exanthema may be easily missed, and it should be differentiated from other flexural eruptions, such as candidal intertrigo, inverse psoriasis or acute generalized exanthematous pustulosis. Besides, symmetrical drug-related intertriginous and flexural exanthema should also be differentiated from systemic contact dermatitis. Symmetrical drug-related intertriginous and flexural exanthema is induced by systemic medication without previous cutaneous sensitization while systemic contact dermatitis is caused by systemic exposure of previous sensitized contact allergen or a cross-reacting molecule.

Thorough medical history taking is important for early diagnosis. Symmetrical drug-related intertriginous and flexural exanthema is classified as a type IV hypersensitivity reaction. The skin rash often develops hours to days after exposure to the causative drugs. The histopathology of symmetrical drug-related intertriginous and flexural exanthema is nonspecific and frequently reveals superficial perivascular lymphocytic infiltration with the occasional presentation of neutrophils or eosinophils. Symmetrical drug-related intertriginous and flexural exanthema is diagnosed mainly on history and clinical manifestations. Other diagnostic tests include patch test, lymphocyte transformation test and provocation test. Although patch test is a common method for identifying the causative drug in symmetrical drug-related intertriginous and flexural exanthema, only half of the cases show a positive result.⁵ The lymphocyte transformation test is an *in vitro* examination which measures the proliferation of T cells in the presence of a specific antigen; however, low sensitivity limits its diagnostic value. Granulysin is a cytolytic molecule which is primarily expressed in the natural killer cells and cytotoxic T cells. In the past decade, Chung *et al.* demonstrated that granulysin is the key cytotoxic mediator of Stevens–Johnson syndrome and toxic epidermal necrolysis.⁶ In addition, Schlapbach *et al.* found that granulysin could be induced *in vitro* in patients with several kinds of cutaneous adverse reaction in addition to Stevens–Johnson syndrome and toxic epidermal necrolysis, such as maculopapular eruption, acute generalized exanthematous pustulosis or fixed drug eruption.⁷ The present case report demonstrates that granulysin can be induced by the causative drug in patients with symmetrical drug-related intertriginous and flexural exanthema. The result indicates that granulysin may play a role in the pathogenesis of symmetrical drug-related intertriginous and flexural exanthema, and *in vitro* granulysin assay may be a useful diagnostic tool. However, further well-controlled study is warranted for its clinical application in the diagnosis of symmetrical drug-related intertriginous and flexural exanthema.

In conclusion, we report a rare case of varenicline-induced symmetrical drug-related intertriginous and flexural exanthema; the causality was confirmed by *in vitro* granulysin assay. Physicians should be aware of this potential adverse cutaneous reaction in patients receiving varenicline for smoking cessation.

Declaration of patient consent

The authors certify that they have obtained all appropriate patient consent forms. In the form, the patient has given his consent for his images and other clinical information to be reported in the journal. The patient understands that name and initials will not be published and due efforts will be made to conceal identity, but anonymity cannot be guaranteed.

Financial support and sponsorship

Nil.

Conflicts of interest

There are no conflicts of interest.

**Chun-Yu Cheng^{1,2,3}, Chuang-Wei Wang^{4,5},
Fang-Ying Wang¹, Wen-Hung Chung^{4,5,6,7}**

¹Department of Dermatology, Chang Gung Memorial Hospital, Chang Gung University College of Medicine, ²Department of Cosmetic Science, Chang Gung University of Science and Technology, ³Center For Tissue Engineering, Chang Gung Memorial Hospital, ⁴Department of Dermatology, Drug Hypersensitivity Clinical and Research Center, Chang Gung Memorial Hospital, ⁵Chang Gung Immunology Consortium, Chang Gung Memorial Hospital, Chang Gung University, ⁶College of Medicine, Chang Gung University, Taoyuan, ⁷Whole-Genome Research Core Laboratory of Human Diseases, Chang Gung Memorial Hospital, Keelung, Taiwan

Correspondence: Dr. Wen-Hung Chung,
Chang Gung Memorial Hospital, 199, Tun-Hwa North Road,
Taipei 105, Taiwan.
E-mail: chung1@cloud.cgmh.org.tw

References

1. Akkari H, Belhadjali H, Youssef M, Mokni S, Zili J. Baboon syndrome induced by hydroxyzine. *Indian J Dermatol* 2013;58:244.
2. Binitha MP, Sasidharanpillai S, John R, Sherjeena PV. Symmetrical drug-related intertriginous and flexural exanthema due to ranitidine. *Indian J Pharmacol* 2014;46:551-2.
3. Naranjo CA, Busto U, Sellers EM, Sandor P, Ruiz I, Roberts EA, *et al.* A method for estimating the probability of adverse drug reactions. *Clin Pharmacol Ther* 1981;30:239-45.
4. Chung WH, Pan RY, Chu MT, Chin SW, Huang YL, Wang WC, *et al.* Oxypurinol-specific T cells possess preferential TCR clonotypes and express granulysin in allopurinol-induced severe cutaneous adverse reactions. *J Invest Dermatol* 2015;135:2237-48.
5. Häusermann P, Harr T, Bircher AJ. Baboon syndrome resulting from systemic drugs: Is there strife between SDRIFE and allergic contact dermatitis syndrome? *Contact Dermatitis* 2004;51:297-310.
6. Chung WH, Hung SI, Yang JY, Su SC, Huang SP, Wei CY, *et al.* Granulysin is a key mediator for disseminated keratinocyte death in Stevens-Johnson syndrome and toxic epidermal necrolysis. *Nat Med* 2008;14:1343-50.
7. Schlapbach C, Zawodniak A, Irla N, Adam J, Hunger RE, Yerly D, *et al.* NKp46+ cells express granulysin in multiple cutaneous adverse drug reactions. *Allergy* 2011;66:1469-76.

This is an open access journal, and articles are distributed under the terms of the Creative Commons Attribution-NonCommercial-ShareAlike 4.0 License, which allows others to remix, tweak, and build upon the work non-commercially, as long as appropriate credit is given and the new creations are licensed under the identical terms.

Access this article online	
Quick Response Code:	Website: www.ijdv.com
	DOI: 10.4103/ijdv.IJDVL_768_17

How to cite this article: Cheng CY, Wang CW, Wang FY, Chung WH. Varenicline-induced symmetrical drug-related intertriginous and flexural exanthema. *Indian J Dermatol Venereol Leprol* 2019;85:209-11.

Received: March, 2018. **Accepted:** November, 2018.

© 2019 Indian Journal of Dermatology, Venereology and Leprology | Published by Wolters Kluwer - Medknow